



## Case Report

# Double Intraocular Lens: Dislocated One into Vitreous and Implanted One into Posterior Chamber

Burak Turgut<sup>1\*</sup>, Nagehan Can<sup>1</sup>, Tamer Demir<sup>1</sup> and Orhan Aydemir<sup>1</sup>

### Abstract

Phaco-emulsification is the most preferred technic at cataract surgery. Rate of dislocated intraocular lens (IOL) into the vitreous has been increased in this surgery. We reported here the results of a case who has dislocated IOL into the vitreous at the time of phaco-emulsification surgery and posterior chamber IOL located to sulcus at a secondary surgical procedure. If the patients have dislocated IOL into the vitreous and they have not any complication and visual acuity loss; IOL can be remain at the place of dropped. However, increasing risk of cystoid macular edema and retinal detachment should be remember, and these cases should be follow closely.

**Keywords:** Intraocular lens dislocated into vitreous; Double intraocular lens; Cataract surgery

### Introduction

The usage of phacoemulsification (PE) in cataract surgery is reported in 1967 [1]. Currently, PE is the most preferred surgical method in cataract surgery over the world [2]. It is more advantageously compared to extracapsular cataract extraction. These advantages include fast wound healing, short surgical time, lower postoperative astigmatism rate and lower risk for expulsive hemorrhage. However, it should be consider that PE has been a long and difficult learning curve. While PE has above mentioned advantages, it has some potentially complications such as posterior capsular rupture, vitreous loss, dislocation of nuclear or cortical lens fragment or implanted intraocular lens (IOL) into vitreous especially in surgery of complicated cases or in surgery performed by unexperienced surgeon [3]. In current literature, it has been reported that the incidence of dislocation of nuclear or cortical lens fragment or IOL into vitreous is 0.2-2.8% in cataract surgery [4,5].

Dislocation of IOL into vitreous is rare but a serious complication. This complication may occur due to forced hydrodissection, phacoemulsification of the nucleus in the presence of a posterior capsular tear or a capsulorrhexis tear or an inappropriate capsulorrhexis, a zonular diastasis and faulty implantation of IOL

\*Corresponding author: Burak Turgut, Associate Professor of Ophthalmology, Firat University School of Medicine, Department of Ophthalmology, Elazığ Turkey, Tel: +904242333555; Fax: +904242388096; E-mail: drburakturgut@gmail.com

Received: October 31, 2012 Accepted: December 13, 2012 Published: December 20, 2012

[3]. Dislocation of IOL into vitreous may observed intraoperatively or a few days following the surgery postoperatively or months after any ocular trauma. Nuclear lens fragments retained in vitreous cavity can result in corneal edema, cystoid macular edema, severe chronic intraocular inflammation, glaucoma, epimacular membrane, peripheral retinal tear, retinal or choroidal detachment, and it may lead to loss of visual acuity [6-8]. A dislocated IOL into vitreous may also cause similar complications [9].

We report here a case with double IOLs including dislocated into vitreous cavity and implanted in posterior chamber without any complication or severe visual loss.

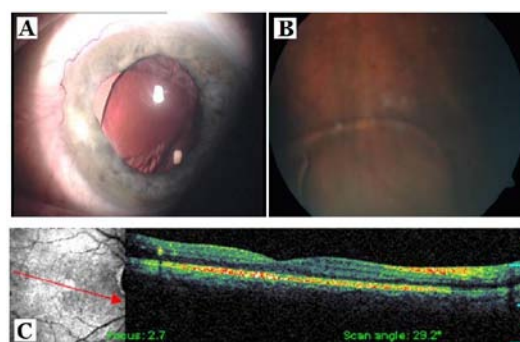
### Case Report

A 65 year-old man with diabetes mellitus was referred to our outpatient clinic for retinopathy. His visual acuity was 20/30 in both eyes. The intraocular pressures were 15 mmHg in right eye and 14 mmHg in the left eye. Slit-lamp examination revealed and nuclear sclerosis in right eye and unreactive, irregular and middilated pupil and posterior chamber IOL implanted on sulcus because of the lack of posterior capsule in left eye (Figure 1A).

Fundus examination revealed a few retinal hemorrhages in macular area in right eye and foldable IOL on retina but not stick on 6 o'clock in inferior peripheral retina beside a few retinal hemorrhages and hard exudates in macular area in left eye (Figure 1B).

When the patient was taken detailed medical history, it was come into the open that he underwent a cataract operation using a PE tecnique in another hospital two years ago. Based on his history, visual acuity in his left eye was good in the first days following surgery. However, then, his visual acuity was dramatically decreased to hand movement level in operated eye. The patient could not continued to come follow up visits because of transportation problems and weather conditions.

Seven months later after the first operation, he was evaluated by primary surgeon and underwent secondary posterior chamber IOL implantation on sulcus (Figure 1A). The follow up visits were



**Figure 1:** A) A posterior chamber intraocular lens implanted on sulcus. B) Dislocated foldable intraocular lens on inferior retina. C) An optical coherence tomographic scan crossing the macula.

performed in our ophthalmology clinic. The patient was carefully examined for retinal tears or detachment in each visit. Any severe complication such as ocular inflammation, glaucoma, retinal tear or detachment was not observed. Optical coherence tomography (OCT) and a scanning laser ophthalmoscope (Spectral OCT/SLO, OTI/OPKO Inc. Toronto, Kanada) were used to detect cystoid macular edema or epimacular membrane or macular detachment. However, any macular pathology was not detected (Figure 1C) in OCT scans. There was no change in previous fundus examination findings in the first year of follow up. The patient is still under follow up in our retina section.

## Discussion

Dislocation of an IOL into vitreous can comprise through ruptured posterior lens capsule or widening aperture of posterior capsulotomy. In the patients with pseudoexfoliation syndrome, spontaneous IOL dislocation can occur years after surgery because of zonular dehiscence, even if posterior capsule is intact. Due to damage the zonular fibers, ocular trauma can also cause drop IOL in the capsular bag [4].

The main surgical indications for removal of intracocular lens or nucleus or lens fragments are vitreous opacity, permanent intraocular inflammation, refractory high intraocular pressure, lens fragment over 25% or multiple lens fragments dislocated into vitreous, corneal edema, vitreous hemorrhage and retinal detachment. Two or three port pars plana vitrectomy (PPV) provides useful visual acuity and the adequate management of complications due to dislocated lenses [10,11].

Surgical techniques described for retrieval of dislocated intraocular lens or nucleus nuclear fragments include floating the nucleus anteriorly using a viscoelastic material and extraction through corneal incision or phacofragmentation and vitrectomy [12-14]. Although dislocated lenses having intact capsule may be remain in vitreous cavity without any complication, crystalline lens proteins from lens with damaged capsule may stimulate the immune reactions [15]. Thus, cortical lens remnants cause more immune reaction due to back of a lens with intact and protective capsule. In current literature, it has not been reported whether or not the prognosis in the patients with dislocated IOL is good compared to those with dislocated cortical remnants. However, we did not observe intraocular inflammation, glaucoma or other complications in our patient.

Dislocation of a foldable IOLs into vitreous cavity is more possible compared to hard polymethylmetacrylate intraocular lenses (PMMA IOL) because foldable IOLs have shorter length and more elastic structure [12-14].

There is no consensus on the optimal timing of vitrectomy at the management of dislocated lenses. It has been suggested that the best time for vitrectomy is at during the cataract surgery to avoid the lens-induced inflammation and other complications. A delay in surgery of more than three weeks can cause the risk of chronic glaucoma, retinal tears, retinal detachment and endophthalmitis [5,8-11].

Although it has been recommended that the removal of dislocated IOL into vitreous using PPV [16,17], in the present case, the primary surgeon which performed cataract operation has not preferred to remove it.

In this kind of case, circular photocoagulation of peripheral retina and the adjacent retina to IOL could be used to prevent retinal and vitreal complications. However, we did not preferred this procedure because IOL was not in touch with retina and, visual acuity was 20/30. In case of that the back of intraocular inflammation and severe visual loss are absent, we preferred to remain IOL in vitreous cavity and PMMA IOL into ciliary sulcus. If dislocated IOLs do not cause ocular inflammation, retinal complications and visual loss, they might remain on the place.

However, retained nuclear fragments after cataract surgery represents a potentially vision-threatening complication. Thus, increasing risk of cystoid macular edema and retinal detachment should be remember, and these cases should be follow closely.

## Disclosures

The authors indicate no financial support or financial conflict of proprietary interest. An informed consent was taken from the patient for this presentation.

## References

1. Kelman CD (1967) Phacoemulsification and aspiration. A new technique of cataract removal. A preliminary report. *Am J Ophthalmol* 64: 23-35.
2. Sihota R, Tandon R (2007) *Parson's diseases of the eye*. (20th edn), New Delhi, Elsevier.
3. Steinert RF (2000) Complications of cataract surgery. In Albert DM, Jakobiec FA, *Principles and Practice of Ophthalmology*, (2nd edn) Philadelphia, WB Saunders, 1551-1598.
4. Gross JG, Kokame GT, Weinberg DV, Dislocated In -The- Bag Intraocular Lens Study Group (2004) In -The-Bag intraocular lens dislocation. *Am J Ophthalmol* 137: 630-635.
5. Schneiderman TE, Johnson MW, Smiddy WE, Flynn HW Jr, Bennett SR, et al. (1997) Surgical management of posteriorly dislocated silicone plate haptic intraocular lenses. *Am J Ophthalmol* 123: 629-635.
6. Pande N, Dabbs TR (1996) Incidence of lens matter dislocation during phacoemulsification. *J Cataract Refract Surg* 22: 737-742.
7. Wolter JR (1983) Foreign body reaction to firm nuclear lens substance. *Ophthalmic Surg* 14: 135-138.
8. Wood WJ (1994) Management of dislocated crystalline lens fragments and intraocular lenses. *Ophthalmology Clinics of North America* 77-87.
9. Avcı R, Baykara M (2001) Treatment of dropped intraocular lenses with pars plana vitrectomy. *Ret-vit* 9: 132-136.
10. Kwok AK, Li KK, Lai TY, Lam DS (2002) Pars plana vitrectomy in the management of retained intravitreal lens fragments after cataract surgery. *Clin Experiment Ophthalmol* 30: 399-403.
11. Boscher C, Lebuissou DA, Lean JS, Nguyen-Khoa JL (1998) Vitrectomy with endoscopy for management of retained lens fragments and/or posteriorly dislocated intraocular lens. *Graefes Arch Clin Ophthalmol* 236: 115-121.
12. Tognetto D, Agolini G, Ravalico G (1999) Spontaneous dislocation into the vitreous of a poly(methyl methacrylate) disc lens 9 years after surgery. *J Cataract Refract Surg* 25: 289-292.
13. Smiddy WE, Flynn HW Jr. (1991) Management of dislocated posterior chamber intraocular lenses. *Ophthalmology* 98: 889-894.
14. Insler MS, Mani H, Peyman GA (1988) A new surgical technique for dislocated posterior chamber intraocular lenses. *Ophthalmic Surg* 19: 480- 481.
15. Peyman GA, Schulman JA (1994) *Intravitreal surgery*. Prentice-Hall international Inc, 235-246.
16. Col VS, Gurusudh, Col A Banarji, Col TS Ahluwalia, Col AK Upadhyay, Col S

Patyal (2008) Management of nucleus and IOL drop. *Medical Journal Armed Forces India* 64: 315-316.

Treatment Modalities and Outcomes of Dislocated IOLs into the Vitreous. *Ret-Vit* 14: 181-184.

17. Serif N, Özdek S, Gürelık G, Akata F, Hasanreisođlu B (2006) Surgical

## Author Affiliation

[Top](#)

<sup>1</sup>Firat University School of Medicine, Department of Ophthalmology, Turkey

### Submit your next manuscript and get advantages of SciTechnol submissions

- ❖ 50 Journals
- ❖ 21 Day rapid review process
- ❖ 1000 Editorial team
- ❖ 2 Million readers
- ❖ More than 5000 
- ❖ Publication immediately after acceptance
- ❖ Quality and quick editorial, review processing

Submit your next manuscript at • [www.scitechnol.com/submission](http://www.scitechnol.com/submission)