



Case Report

A SCITECHNOL JOURNAL

Lymphomatous Optic Nerve Infiltration in Paediatric Cases

RN Hussain^{1*}, C Chambers¹ and G Woodruff^{1,2}

Abstract

We describe 2 children with stage IV anaplastic lymphoma with optic neuropathy due to optic nerve infiltration. Both children had an established diagnosis of anaplastic lymphoma prior to their ocular symptoms. Common symptoms included visual blurring and ocular pain, and examination revealed optic nerve head infiltration. Although one patient responded initially to systemic chemotherapy agents, both had residual severe visual impairment secondary to their optic nerve lesion and to the toxic effects of treatment for their central nervous system disease.

Anaplastic lymphoma is a rare cause of optic neuropathy. This is the first report of children with such a diagnosis with visual follow up; the visual prognosis seems to be poor and very resistant to treatment.

Keywords

Lymphoma; Optic nerve infiltration

Introduction

Non-Hodgkin lymphoma is the most common type of ocular lymphoma; the most common presentation is with reduced vision and non-resolving uveitis. Optic nerve infiltration secondary to advanced systemic lymphoma is rare and has been described in the literature predominantly in the adult population [1-3]. Lymphoma in the paediatric population tends to be of a more aggressive form than in adults; there have been 3 case reports of lymphomatous optic nerve infiltration in children [4-6] and, although 2 of these cases describe an improvement in the optic nerve appearance to examination and radiological imaging in response to systemic treatment, the consequences on visual outcome have not been reported. We present a series of 2 cases in the paediatric population with significant visual and systemic sequelae following lymphomatous optic nerve disease.

Case 1

A 5 year old girl presented with back pain and a thoracic paraspinal mass. Magnetic resonance imaging and biopsy of the mass confirmed the diagnosis of stage IV T-cell lymphoma. She was treated with chemotherapy inclusive of intrathecal methotrexate, cytarabine and dexamethasone with a favourable response initially. However, fifteen months into treatment (November 2011) a central nervous system relapse warranted additional weekly courses of intrathecal methotrexate. In January 2012, she subsequently

complained of painful eyes and blurred vision in the left eye. Ocular examination revealed poor left best corrected visual acuity (BCVA) at no perception of light, mild left proptosis with limited globe elevation, and a dramatic relative afferent pupillary defect. Fundal examination demonstrated gross left optic disc oedema, peripapillary haemorrhages and macular oedema (Figure 1). An MRI revealed an increase in white matter signal, left optic nerve enlargement with thickening and blurring of the left optic nerve margins (Figure 2). The patient was continued on weekly high dose systemic corticosteroids and intrathecal methotrexate. She subsequently underwent bone marrow transplantation and cerebral radiotherapy, with consequent cerebral toxicity and significant deterioration in her neuronal function. The BCVA in the left eye remains severely impaired at perception of light; however the optic nerve appears less swollen.

Case 2

A 10 year old boy presented with abdominal pain and generalised lymphadenopathy; he was diagnosed with anaplastic lymphoma and was treated with intravenous vincristine, methotrexate and folinic acid and intrathecal methotrexate, cytarabine and hydrocortisone.

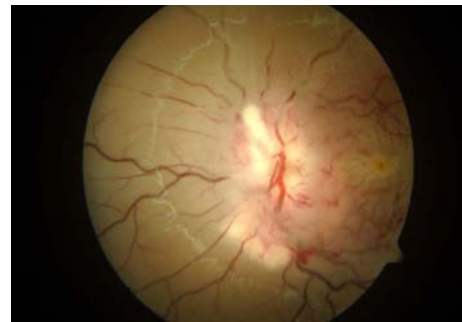

Figure 1: Left optic disc appearance.

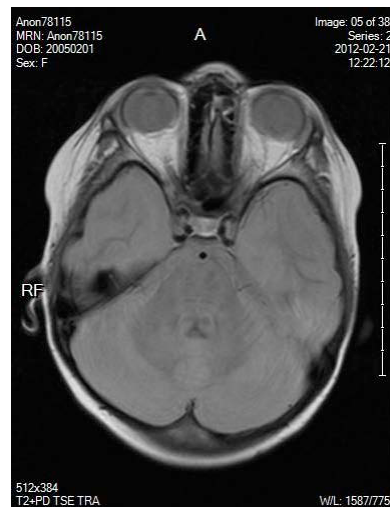


Figure 2: MRI showing thickening of the left optic nerve with blurring of the margins.

*Corresponding author: RN Hussain, Department of Ophthalmology, Leicester Royal Infirmary, Infirmary Square, Leicester LE1 5WW, UK, Tel: 07903271112; E-mail: rumanahussain@hotmail.com

Received: February 19, 2013 Accepted: March 19, 2013 Published: March 25, 2013

His initial response was favourable but 12 months later he presented with headaches, drowsiness, pain on eye movement and poor left eye vision. His left BCVA was hand motions, with a marked RAPD, left optic disc swelling, peripapillary haemorrhages and macular oedema (Figure 3). His ocular movements were restricted in all directions of gaze with associated pain. Following a course of intravenous dexamethasone and intrathecal methotrexate, cytarabine and hydrocortisone his BCVA improved to 6/9 with moderate resolution of his abnormal disc appearance and macular oedema. His MRI at the time showed white matter changes, left optic nerve enlargement and enhancement (tram track) (Figure 4). On completion of a course of systemic steroids, his vision declined with return of the haemorrhagic disc oedema. Counting fingers was his last recorded visual acuity. Unfortunately despite intensive chemotherapy and stem cell transplantation, this patient demised.

Discussion

Infiltration of the optic nerve by lymphoma usually occurs in the setting of recurrence of systemic lymphoma or as part of the initial disease presentation. With the increasing survival associated with more effective treatment of non Hodgkin's lymphoma, the incidence of CNS involvement is increasing with the ophthalmologist being more involved in such cases [7]. Making the diagnosis of lymphomatous infiltration can prove difficult as other causes are possible such as optic neuritis secondary to infections, neurotoxic drugs (intrathecal chemotherapeutic agents in our patient),

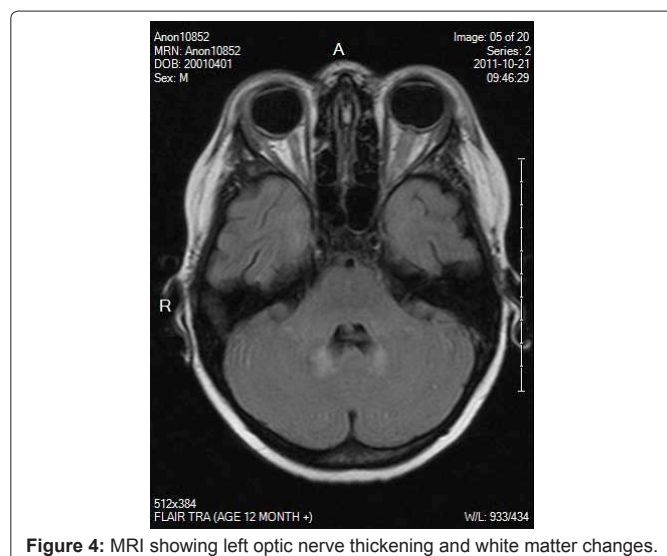
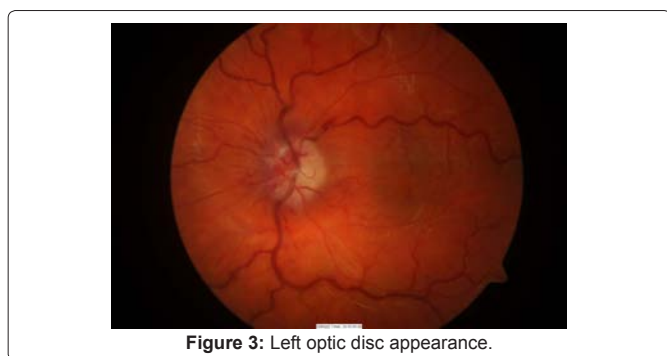
radionecrosis and paraneoplasia. A tissue biopsy of the optic nerve is often unavailable. In our 2 patients, the responsive nature of the optic nerve appearances to chemotherapeutic agents and the simultaneous systemic lymphomatous recurrence would suggest an infiltrative pathology.

Because of the high recurrence rate and refractory nature of primary central nervous system lymphoma with ocular involvement, treatment is difficult. Chemoradiation is the most effective treatment but with significant cerebral and ocular morbidity. Radiotherapy for primary central nervous system lymphoma with ocular involvement is highly effective, however complications include cataract, dry eye, corneal ulceration, neovascular glaucoma, radiation retinopathy, and optic neuropathy. These patients have a poor prognosis even with chemoradiation, and many succumb to central nervous system (CNS) disease within 2 years.

The optic nerve is a rare site of lymphomatous infiltration and has rarely been described in the literature in the paediatric population [4-6]. The prognosis of these patients seems to be visually extremely poor with an associated poor systemic outcome.

References

1. Finke E, Hage R, Donnio A, Bomahou C, Guyomarch J, et al. (2012) Retrobulbar optic neuropathy and non-Hodgkin lymphoma. *J Fr Ophtalmol* 35: 124.e1-4.
2. Kitzmann AS, Pulido JS, Garrity JA, Witzig TE (2008) Histologic findings in T-cell lymphoma infiltration of the optic nerve. *Ophthalmology* 115: e1-6.
3. Yamamoto N, Kiyosawa M, Kawasaki T, Miki T, Fujino T, et al. (1994) Successfully treated optic nerve infiltration with adult T-cell lymphoma. *J Neuroophthalmol* 14: 81-83.
4. Porto L, Kieslich M, Schwabe D, Yan B (2005) Central nervous system lymphoma in children. *Pediatr Hematol Oncol* 22: 235-246.
5. Kim UR, Shah AD, Arora V, Solanki U (2010) Isolated optic nerve infiltration in systemic lymphoma--a case report and review of literature. *Ophthal Plast Reconstr Surg* 26: 291-293.
6. Kashani AA, Kerman BM (1997) Central nervous system malignant B-cell lymphoma identified with standard echography of the optic nerve. *J Neuroophthalmol* 17: 243-246.
7. Zaman AG, Graham EM, Sanders MD (1993) Anterior visual system involvement in non-Hodgkin's lymphoma. *B J Ophthalmol* 77: 184-187.




Author Affiliations

¹Leicester Royal Infirmary, UK
²University of Leicester, UK

Top

Submit your next manuscript and get advantages of SciTechnol submissions

- ❖ 50 Journals
- ❖ 21 Day rapid review process
- ❖ 1000 Editorial team
- ❖ 2 Million readers
- ❖ More than 5000 
- ❖ Publication immediately after acceptance
- ❖ Quality and quick editorial, review processing

Submit your next manuscript at • www.scitechnol.com/submission