



Case Report

A SCITECHNOL JOURNAL

Spontaneous Resolution of Retinal Detachment Only After Barrage Laser Photocoagulation in a Patient with Inadvertent Scleral Perforation during Retrobulbar Anesthesia: A Case Report

Mehmet Demir^{1*}

Abstract

Inadvertent scleral perforation during cataract surgery is not a common but a serious complication of retrobulbar anesthesia. The majority of cataract surgeries in adults is performed under retrobulbar, peribulbar or topical anesthesia. The high myopia is a risk factor for scleral perforation during peribulbar or retrobulbar anesthesia. In this case sclera was perforated during retrobulbar anesthesia and we present management and follow-up from baseline to 41 months.

Keywords

Inadvertent scleral perforation; Retinal detachment; High myopia; Clear lens Extraction; Laser photocoagulation

Case Report

A 39-year-old woman presented with the complaint of low vision and thick glasses. On ophthalmologic examination, her best corrected visual acuity (BCVA) was 20/200 (-15,50 -1.50 100*) in the right eye and 20/200 (-14.00-1.50 85*) in the left eye. The IOP was 17 mm Hg OD and 15 mm Hg OS. She had degenerative myopic fundus in both eyes. She had no retinal detachment or glaucoma. The axial length was 27.6 mm in the right eye and 26.5 mm in the left eye. Anterior chambers were deep and crystallin lenses were clear on both side.

We decided to perform clear lens extraction under retrobulbar anesthesia by phacoemulsification. The cataract surgery was completed without complication in the left eye with retrobulbar anesthesia. After one week, the patient was prepared for right eye surgery. Retrobulbar anesthesia was performed using 25 gauge needle. During anesthesia globe deformation was noticed and inadvertent scleral perforation was suspected. Fortunately, the anesthetic agent was not injected from syringe. After noticing scleral perforation the needle was withdrawn from retrobulbar space. We decided to continue clear lens surgery under topical anesthesia.

*Corresponding author: Mehmet Demir, Sisli Etfal Training and Research Hospital, Eye Clinic, Istanbul, Turkey, E-mail: drmehmetfe@hotmail.com

Received: February 25, 2013 Accepted: March 21, 2013 Published: March 28, 2013

During phacoemulsification there was no red reflex of retina and there was marked ocular hypotony. Lens capsule was stained with tripan blue dye. Lens extraction with phacoemulsification and IOL implantation was performed via clear corneal incisions. Capsule perforation or vitreous loss did not occur during surgery.

At the first postoperative day a retinal round break with local neuroretinal detachment at nasal quadrant and hypotony (4 mmHg) was observed (Figures 1 and 2). Visual acuity was 20/400. Serous detachment area was 1x2 disc diameter at the first day and 3x4 disc diameter at 2nd postoperative day. Laser photocoagulation (with Indirect laser ophthalmoscope) was performed around of the detachment on the second postoperative day to prevent extension of detachment. We had to wait until 2nd postoperative day for laser photocoagulation because we wait for an indirect laser ophthalmoscope. We did not have ready an indirect laser ophthalmoscope.

The patient was examined on postoperative day 1, 2, 7, 10, 30 and with 1 monthly intervals thereafter. Topical dexamethasone and tobramycin drops 5x1/day was prescribed for 30 days. During follow up visits the detachment spontaneously reattached and visual acuity increased. Posterior capsul opacification developed at 36 months and capsulotomy was performed with Nd: YAG laser. After 41 months visual acuity was measured 20/50 in the both eyes and retina was attached with laser scars at nasal quadrant (Figure 3).

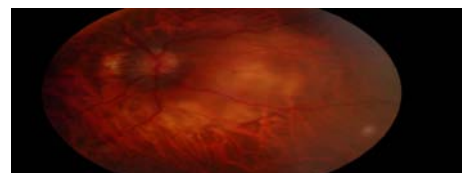


Figure 1: Postoperative 1 day, retinal detachment at nasal quadrant in the right eye.

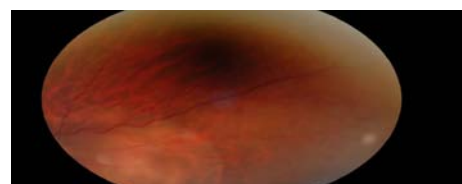

Figure 2: Postoperative 1 day, retinal detachment at nasal quadrant in the right eye.

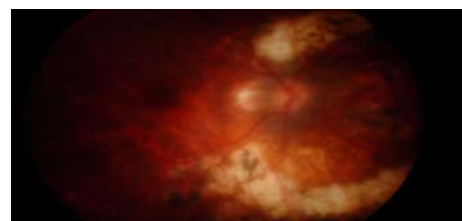


Figure 3: At 41 months, Retina attached and laser scars.

Discussion

Scleral perforation during retrobulbar anesthesia is a terrible complication. It occurs especially in patients with high myopia with posterior staphyloma. A study showed that scleral perforation is more frequent in retrobulbar anesthesia than peribulbar anesthesia [1]. Retinal break, retinal detachment, intraocular hemorrhage and proliferative vitreoretinopathy (PVR) can develop after scleral perforation [2-4], however hemorrhage and PVR did not develop in our case. The most of the inadvertent scleral perforations during retrobulbar or peribulbar anesthesia need multiple surgeries for detachment, PVR or hemorrhage [5]. Topical or peribulbar anesthesia are safer for patients with high myopia. Retrobulbar anesthesia was chosen due to patient anxiety in our case. Several studies showed that visual acuity ranges from no light perception to 20/50 [1-5]. In our case, visual acuity in 41 months after surgery was 20/50. We believe that final visual acuity was satisfactory in our case because sclera was perforated at nasal area and anesthetic agents was not injected into vitreous body. Scleral perforation site and whether or not anesthetic agent has been given into vitreous body are important prognostic factors for final visual acuity. A study showed that vision-threatening consequences of globe perforation during strabismus surgery is uncommon in the rabbit model [6]. This is explained with the absence of injection of anesthetic agent/s and anterior localization of perforation. Barrage laser photocoagulation of retinal break or local retinal detachment is sufficient in some inadvertent scleral perforation cases.

Conclusion

If there is suspect of scleral perforation during retrobulbar

anesthesia, anesthetic solution should not be injected and needle should be withdrawn carefully. Area of detachment or point of perforation should be surrounded by laser photocoagulation using contact lenses or indirect ophthalmoscopy immediately.

Financial Disclosure

The authors did not receive any financial support from any public or private sources.

References


1. Duker JS, Belmont JB, Benson WE, Brooks HL Jr, Brown GC, et al. (1991) Inadvertent globe perforation during retrobulbar and peribulbar anesthesia. Patient characteristics, surgical management, and visual outcome. *Ophthalmology* 98: 519-526.
2. Wearne MJ, Flaxel CJ, Gray P, Sullivan PM, Cooling RJ (1998) Vitreoretinal surgery after inadvertent globe penetration during local ocular anesthesia. *Ophthalmology* 105: 371-376.
3. Modarres M, Parvaresh MM, Hashemi M, Peyman GA (1997) Inadvertent globe perforation during retrobulbar injection in high myopes. *Int Ophthalmol* 21: 179-185.
4. Schrader WF, Schargus M, Schneider E, Jostifova T (2010) Risks and sequelae of scleral perforation during peribulbar or retrobulbar anesthesia. *J Cataract Refract Surg* 36: 885- 889.
5. Edge R, Navon S (1999) Scleral perforation during retrobulbar and peribulbar anesthesia: risk factors and outcome in 50,000 consecutive injections. *J Cataract Refract Surg* 25: 1237-1244.
6. Bagheri A, Erfanian-Salim R, Ahmadi H, Nourinia R, Safarian O, et al. (2011) Globe perforation during strabismus surgery in an animal model: Treatment versus observation. *J AAPOS* 15: 144-147.

Author Affiliation

Top

¹Sisli Etfal Training and Research Hospital, Eye Clinic, Istanbul, Turkey

Submit your next manuscript and get advantages of SciTechnol submissions

- ❖ 50 Journals
- ❖ 21 Day rapid review process
- ❖ 1000 Editorial team
- ❖ 2 Million readers
- ❖ More than 5000 
- ❖ Publication immediately after acceptance
- ❖ Quality and quick editorial, review processing

Submit your next manuscript at • www.scitechnol.com/submission