



Case Report

## Observation of Left Ventriculography with a Single Left Coronary Injection via Unique Coronary-Cameral Fistulas

Bulent Uzunlar<sup>1</sup>, Zeki Dogan<sup>1</sup> and Ahmet Karabulut<sup>1\*</sup>

### Abstract

We presented a case of coronary cameral fistulas with unique multiple paths throughout rich microvascular mesh leading to complete opacification of left ventricle similar to standard ventriculographic study. We also discussed the treatment strategy in the coronary fistulae.

### Keywords

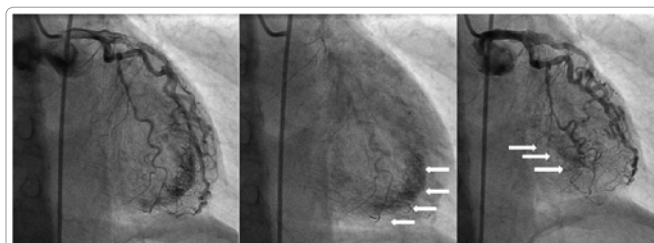Coronary fistulae; Left ventricle

### Introduction

Coronary cameral fistulas are rare clinical findings in the routine angiographic examination [1]. They usually drain into cardiac chambers with a small paths which lead to restricted opacification of the chambers. Herein, we presented a case of coronary cameral fistulas with unique multiple paths throughout rich microvascular mesh leading to complete opacification of left ventricle similar to standard ventriculographic study.

### Case Report

A 68 year-old female patient was presented with a class 3 anginal symptoms. On medical background, she was hypertensive and undermedication for dyslipidemia. Electrocardiography showed left ventricular hypertrophy criteria. Echocardiography revealed normal ejection fraction and left ventricular hypertrophy (1,3 cm) with apical predominance (1.5 cm). Three-vessel disease was obtained in the coronary angiography, and also, an unique diffuse microfistulas between left coronary system and left ventricle was observed. The fistulas was originating from small branches of left anterior descending and circumflex arteries and they was connected to rich microvascular mesh over apical segment with diffuse drainage system. In the each injection of left coronary ostium, apical segment was opacified in the wash-out period of coronary circulation and left ventricular cavity was visualized similar to standard left ventriculography view (Figure



**Figure 1:** Left coronary circulation in the right anterior oblique cranial view. Opacification of apical segment with microfistular mesh (indicated with white arrow) observed in the left and middle pictures. Midventricular systolic opacification (indicated with white arrow) was observed in the right picture.

1). Surgical revascularization was scheduled for the patient because of the multivessel disease.

### Discussion

The fistulas between coronary arteries and cardiac chambers are defined as coronary cameral fistula. They are rare angiographic findings with 0.08–0.3% incidence [1,2]. Majority of them usually drain into right ventricle. They are classified as arterio-luminal, arterio-sinusoidal and arterio-capillary communication. The former has a lowest prevalence and our patient belong to sinusoidal type fistulas. Coronary cameral fistulas are usually asymptomatic and detected incidentally. However they can lead to widespread clinical pictures including simply dyspnea to acute myocardial infarction due to ischemia. The mechanism of ischemia formation was proposed either direct coronary stealing or diastolic volume overload [3,4]. Medical follow with beta blockers or calcium channel blockers, percutaneous closure and surgical ligation are the treatment choices [3,4]. Our patient's symptomatology was most probably secondary to multivessel disease. Ischemic effect of fistulas themselves will be assessed after revascularisation. Even they trigger ischemia, medical follow is only choice for our patient due to diffuse microvascular involvement. There was not direct pathway or communication between coronaries and left ventricle. Thus, surgical or percutaneous approach is not proper for this kind of sinusoidal and capillary microfistulas. In addition, drainage segment of fistulas are frequently observed as hypertrophic. The definite mechanism is not known. It was proposed that fistulas could progress on the basis of hypertrophic cardiomyopathy secondary to extracellular dysorganisation. And also, fistulas themselves could lead to ventricular hypertrophy by the effect of volume overload [5]. The former was seem to be probable mechanism of hypertrophy in our patient. Hence, patient has concentric hypertrophy secondary to uncontrolled hypertension with apical predominance that may clarify the additive effect of multiple microfistulas.

### Conclusion

Coronary cameral fistulas are rare angiographic findings with unique angiographic appearance. Medical follow is only choice for multiple microvascular sinusoidal type microfistulas irrespective to their symptomatology.

\*Corresponding author: Ahmet Karabulut, Associate Professor, Istanbul Medicine Hospital, Department of Cardiology, Hoca Ahmet Yesevi Cad. No: 149, 34203, Istanbul, Turkey, Tel: +90 212 4890800; Fax: +90 212 4743694; E-mail: drkarabulut@yahoo.com

Received: March 08, 2013 Accepted: March 29, 2013 Published: March 31, 2013

### Aknowledgement

The authors do not report any conflict of interest regarding this work. This work was not supported by any company.

### References


1. Lee DY, Park SH, Bae MH, Lee JH, Yang DH, et al. (2012) Multiple fistula emptying into the left ventricle through the entire left ventricular wall. J Cardiovasc Ultrasound 20: 108-111.
2. Padfield GJ (2009) A case of coronary cameral fistula. Eur J Echocardiogr 10: 718-720.
3. Kurt IH (2009) Myocardial infarction caused by a fistula between the left anterior descending coronary artery and the left ventricle. Tex Heart Inst J 36: 177-179.
4. Arslan S, Gurlertop Y, Elbey MA, Karakelleoglu S (2009) Multiple coronary-cameral fistulae causing angina pectoris. Tex Heart Inst J 36: 622-623.
5. Dresios C, Apostolakis S, Tzortzis S, Lazaridis K, Gardikiotis A (2010) Apical hypertrophic cardiomyopathy associated with multiple coronary artery-left ventricular fistulae: a report of a case and review of the literature. Eur J Echocardiogr 11: E9.

### Author Affiliation

Top

<sup>1</sup>Department Of Cardiology, Istanbul Medicine Hospital, Istanbul, Turkey

#### Submit your next manuscript and get advantages of SciTechnol submissions

- ❖ 50 Journals
- ❖ 21 Day rapid review process
- ❖ 1000 Editorial team
- ❖ 2 Million readers
- ❖ More than 5000 
- ❖ Publication immediately after acceptance
- ❖ Quality and quick editorial, review processing

Submit your next manuscript at • [www.scitechnol.com/submission](http://www.scitechnol.com/submission)