



Case Report

Central Mucoepidermoid Carcinoma—A Case Report and Review of the Literature

Seyedmajidi M^{1*} and Foroughi R²

Abstract

Mucoepidermoid carcinoma is one of the most common malignancies of the salivary glands. Central mucoepidermoid carcinomas are extremely rare in the jaws, representing about 2 to 4% of all mucoepidermoid carcinomas. The case presented is a 43 year old woman with central mucoepidermoid carcinoma on the left side of the mandible. She did not visit surgeon for further treatment and died due to heart disease after 3 months. Although more than 100 cases have been reported in the literature, its etiopathogenesis has centered on the pluripotential capabilities of the epithelial lining of odontogenic cysts but our patient did not give a prior history of either cyst enucleation or tumor resection in the same region. It seems that this tumor originated from retromolar mucous glands entrapped or embryonic remnants of the submandibular salivary gland within the mandibular bone which subsequently underwent neoplastic transformation.

Keywords

Jaw tumors; Intraosseous carcinoma; Mucoepidermoid

Introduction

Mucoepidermoid carcinoma is one of the most common salivary gland malignancies that exhibit biological behaviors with range from low to high grade [1,2]. It comprises 10% of all major salivary gland tumors and 15% to 23% of minor salivary gland tumors [1-5]. In 1945, Stewart et al. established it as a distinct pathologic entity with description of mucus secreting and epidermal cellular elements [6]. Earlier in 1939, Lepp reported central mucoepidermoid carcinoma of the mandible in a 66-year old woman [7], and Bhaskar reported two cases and analyzed the criteria for their central origin, histology and pathogenesis [8].

Eversole reviewed 815 cases of mucoepidermoid carcinoma and showed that of the major salivary gland tumors, parotid was the most common site (89.6%) of involvement, followed by submandibular gland (8.4%) and sublingual gland (0.4%) [3]. The most common site for minor salivary gland involvement was palate, accounting for 41.1% of intraoral lesions [3].

Intraosseous salivary gland neoplasms arising within the jaws are extremely rare. They comprised 2-3% of all reported mucoepidermoid

*Corresponding author: Maryam Seyedmajidi, Department Of Oral and Maxillofacial Pathology, Dental Faculty, Babol Medical Sciences University, Babol, Iran, Tel: +981112291408 (Ext: 116); Fax: +981112291093; E-mail: ms_majidi79@yahoo.com

Received: January 02, 2013 Accepted: February 20, 2013 Published: February 27, 2013

carcinomas [4]. A systematic review of its histology and degree of differentiation was done in 1991, after that the WHO classification recommended that the term “mucoepidermoid tumor” be changed to “mucoepidermoid carcinoma” [9]. More than 100 cases of mucoepidermoid carcinoma arising in the mandible were reported in the literature [4,5,10,11].

We report another case of central mucoepidermoid carcinoma within the mandible.

Case Presentation

The patient is a 43-year-old woman referred to oral and maxillofacial surgeon. Her chief complaint was facial swelling at the left mandibular angle about 4 years ago without any pain or paresthesia or trismus. She denied smoking and any consumption of drugs or alcohol. On clinical examination, buccal and lingual cortical expansion could be seen. The overlying mucosa was normally intact. All left molars were extracted many years ago. Cervical lymphadenopathy was absent. Panoramic radiograph of the mandible revealed a well circumscribed multilocular radiolucency at the left angle area extending to distal aspect of the 2nd premolar (Figure 1). Differential diagnosis included ameloblastoma, odontogenic myxoma and Pindborg tumor. Biopsy was carried out and the specimen was sent for histopathologic examination.

Microscopic examination revealed a neoplasm composed predominantly of an epidermoid component in a fibrous stroma (Figure 2). The cystic spaces were scarce. Also mucous secreting cells and cells of intermediate type were observed (Figure 3). In many areas, stroma was hyalinized. An extensive chronic inflammation was observed around nests of tumor. Final diagnosis was mucoepidermoid carcinoma. The patient did not show interest to visit surgeon for further treatment. Ultimately, she died after 3 months.

Discussion

Central mucoepidermoid carcinoma has been reported in all ages ranging from 1 to 78 years [5] and the majority of cases occur in 4th and 5th decades of life. It demonstrates a slight female predilection [1]. It is three times more common in the mandible than in the maxilla and is most often seen in the molar-ramus area [1].

Due to this fact that 83% of cases of central mucoepidermoid

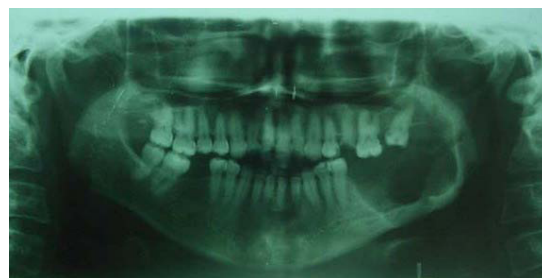

Figure 1: Panoramic radiograph of the mandible revealed a well circumscribed multilocular radiolucency at the left angle area extending to distal aspect of the 2nd premolar.

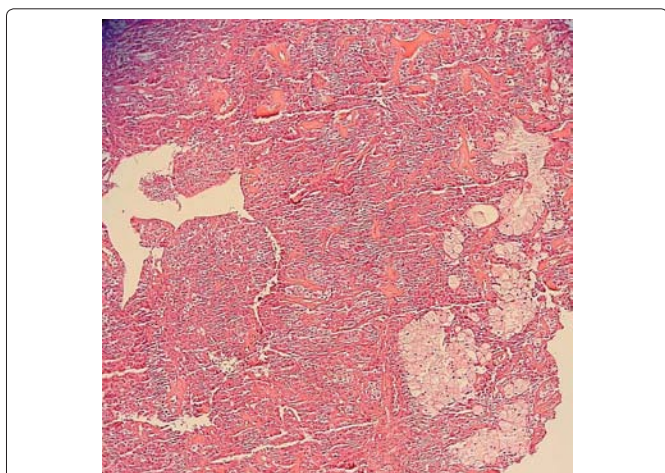


Figure 2: Microscopic examination revealed a neoplasm composed predominantly of an epidermoid component in a fibrous stroma ($\times 100$).

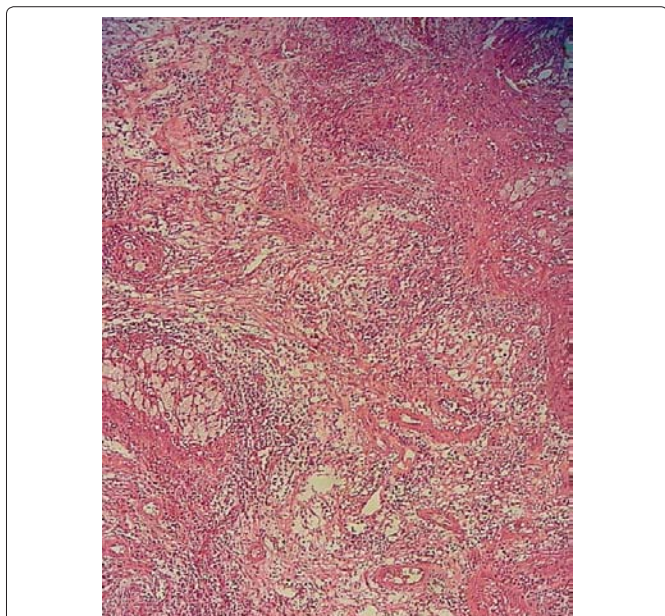


Figure 3: The cystic spaces were scarce. Also mucous secreting cells and cells of intermediate type were observed ($\times 100$).

carcinoma occurred in the molar region the most probable location of developing dentigerous and odontogenic keratocysts, it was suggested that the most likely source of the central mucoepidermoid carcinoma is the neoplastic transformation of the epithelial lining of an odontogenic cyst as mucus-producing cells are common in odontogenic cysts lining especially in dentigerous cysts [7].

Eversole et al. found approximately 50% of the central mucoepidermoid carcinomas associated with dental cysts and/or impacted teeth [5] while Brookstone and Huvos reported a rate of 32% [10].

In present case, lack of previous history of a cyst or impacted tooth with tumor suggested that odontogenic epithelium is not origin of tumor. It seems that this tumor originated from retromolar mucous glands entrapped or embryonic remnants of the submandibular

salivary gland within the mandibular bone which subsequently underwent neoplastic transformation.

The main symptoms associated with central mucoepidermoid carcinoma are swelling and pain with trismus [10]; paraesthesia and tooth mobility are also occasionally being noted [10]. Tucci et al. reported destruction, local infiltration and ulcerated mucosa in long time evolution case of central mucoepidermoid carcinoma [12]. Facial swelling and cortical expansion were seen in present case without any pain, paresthesia or trismus.

Radiographic feature of tumors usually show a well circumscribed unilocular/multilocular radiolucency [13]. Also panoramic radiograph of present case revealed a well circumscribed multilocular radiolucency.

Pires et al. reported four cases of central mucoepidermoid carcinomas affecting the mandible radiographically, three cases showed a radiolucent multilocular image and in one case it was unilocular [14].

Radiographic features of two cases presented by Jiang et al. showed osteolytic odontogenic cyst. They believed that X-ray is not enough to distinguish central mucoepidermoid carcinomas from an odontogenic cyst or benign tumor such as ameloblastoma [15].

Sherin et al. reported unusual case of central mucoepidermoid carcinomas where the lesion appeared with radio-opaque masses in the radiograph and bone in histopathology [16].

Lesions in maxilla may arise from the mucous secreting glands in the antrum, or represented as an intraosseous extension of minor salivary gland tumors of the antral mucosa but origin of tumor is controversial when the tumor is in the mandible [13].

In general, four possible origins have been described 1) neoplastic transformation of entrapment of retromolar mucous glands; 2) embryonic remnants of the submandibular gland within the mandible; 3) neoplastic transformation of the mucous producing cells in odontogenic cyst lining, especially dentigerous cysts associated with impacted third molars; and 4) arising from gland of the sinus lining [6].

Our patient did not give a prior history of cyst enucleation in the same region as the tumor. Then it seems that this tumor originated from retromolar mucous glands entrapped or embryonic remnants of the submandibular salivary gland within the mandibular bone which subsequently underwent neoplastic transformation.

Metastases are reported in 9% of central mucoepidermoid carcinomas mainly to the regional lymph nodes [10,17] and occasionally to the ipsilateral clavicle, [18] lung and brain [19].

Surgery is the primary treatment modality. In a review of 64 patients, Brookstone and Huvos observed 40% recurrences after conservative surgical modalities such as curettage, enucleation, marsupialization and marginal resection with or without adjuvant therapy, whereas in the group treated by radical methods such as segmental resection with/without treatment of associated neck and/or adjuvant therapy only 4% recurred [10]. Adjuvant radiotherapy is recommended for high-grade tumors [17].

Alexander et al. proposed the most commonly accepted criteria for diagnosis of central mucoepidermoid carcinoma that modified by Browand and Waldron as follows: cortical plates are intact, bony

destruction is seen in radiographic features, exclusion of another primary tumor metastasis, exclusion of an odontogenic tumor, histopathological confirmation, detectable intracellular mucin [20,21].

In present case, cortical plates were expanded and were intact without any radiographic evidence of bone destruction. The histopathological feature confirmed the lesion and intracellular mucin could be detected.

A staging system based on condition of the overlying bone had been offered by Brookstone and Huvos [10]. The best prognosis suggests for lesions with intact cortical plates without any evidence of bony expansion and indicate stage I disease. Intact cortical bone with some degree of expansion indicated Stage II disease. Stage III disease is surrounded by existence of cortical perforation, breakdown of the overlying periosteum or nodal spread. The presented case showed expanded, but intact buccal and lingual cortices and could be imputed as stage II disease [10].

Conclusion

Central mucoepidermoid carcinomas are uncommon salivary gland tumors that usually affect the posterior mandible as uni- or multilocular radiolucency with well defined borders. Most tumors are low-grade lesions and treatment includes wide local excision.

Most common reason of death is local recurrence of tumor that can occur even after decades.

References

1. Neville BW, Damm DD, Allen C, Bouquout JE (2009) *Oral and Maxillofacial Pathology*. (4th edn) W.B Saunders, Philadelphia, USA.
2. Regezi JA, Sciubba JJ, Jordan RCK. *Oral Pathology: Clinical Pathologic Correlations*. (6th edn) Saunders, St. Louis, USA.
3. Eversole LR (1970) Mucoepidermoid carcinoma: review of 815 reported cases. *J Oral Surg* 28: 490–494.
4. Gingell JC, Beckerman T, Levy BA, Snider LA (1984) Central mucoepidermoid carcinoma. Review of the literature and report of a case associated with an apical periodontal cyst. *Oral Surg Oral Med Oral Pathol* 57: 436–440.
5. Ezsiás A, Sugar AW, Milling MA, Ashley KF (1994) Central mucoepidermoid carcinoma in a child. *J Oral Maxillofac Surg* 52: 512–515.
6. Shafer WG, Hine MK, Levy BM (1974) *Text book of Oral Pathology*. (3rd edn) WB Saunders, Philadelphia, USA.
7. Kochaji N, Goossens A, Bottenberg P (2004) Central mucoepidermoid


- carcinoma: Case report, literature review for missing and available information and guideline proposal for coming case reports. *Oral Oncol Extra* 40: 95–105.
8. Bhaskar SN (1963) Central mucoepidermoid tumors of the mandible. Report of 2 cases. *Cancer* 16: 721–726.
9. Seifert G, Sobin LH, Thackray AC (1991) *Histological typing of salivary glands tumors*. World health organization international histological classification of tumors. (2nd edn) Springer-Verlag, Heidelberg.
10. Brookstone MS, Huvos AG (1992) Central salivary gland tumors of the maxilla and mandible: a clinicopathologic study of 11 cases with an analysis of the literature. *J Oral Maxillofac Surg* 50: 229–236.
11. Maremonti P, Califano L, Mangone GM, Zupi A, Guida C (2001) Intraosseous mucoepidermoid carcinoma. Report of a long-term evolution case. *Oral Oncol* 37: 110–113.
12. Tucci R, Matizonkas-Antonio LF, de Carvalho AA, Castro PH, Nunes FD, et al. (2009) Central mucoepidermoid carcinoma: Report of a case with 11 years' evolution and peculiar macroscopic and clinical characteristics. *Med Oral Patol Oral Cir Bucal* 14: E283–286.
13. Freje JE, Campbell BH, Yousif NJ, Clowry LJ (1995) Central mucoepidermoid carcinoma of the mandible. *Otolaryngol Head Neck Surg* 112: 453–456.
14. Pires FR, Paes de Almeida O, Lopes MA, Elias da Cruz Perez D, Kowalski LP (2003) Central mucoepidermoid carcinoma of the mandible: report of four cases with long-term follow-up. *Int J Oral Maxillofac Surg* 32: 378–382.
15. Jiang L, Jiang X, Zhao L, Liu Y, Wang G, et al. (2007) Central mucoepidermoid carcinoma of the jaws: report of two cases. *Journal of Medical Colleges of PLA* 22: 129–131.
16. Sherin S, Sherin N, Thomas V, Kumar N, Sharafuddeen KP (2011) Central mucoepidermoid carcinoma of maxilla with radiographic appearance of mixed radiopaque-radiolucent lesion: a case report. *Dentomaxillofac Radiol* 40: 463–465.
17. Eversole LR, Sabes WR, Rovin S (1975) Aggressive growth and neoplastic potential of odontogenic cysts: with special reference to central epidermoid and mucoepidermoid carcinomas. *Cancer* 35: 270–282.
18. Lebsack JP, Marrogi AJ, Martin SA (1990) Central mucoepidermoid carcinoma of the jaw with distant metastasis: a case report and review of the literature. *J Oral Maxillofac Surg* 48: 518–522.
19. Simon D, Somanathan T, Ramdas K, Pandey M (2003) Central mucoepidermoid carcinoma of mandible: A case report and review of the literature. *World J Surg Oncol* 1: 1–5.
20. Alexander RW, Dupuis RH, Holton H (1974) Central mucoepidermoid tumor (carcinoma) of the mandible. *J Oral Surg* 32: 541–547.
21. Browand BC, Waldron CA (1975) Central mucoepidermoid tumors of the jaws: Report of nine cases and review of the literature. *Oral Surg Oral Med Oral Pathol* 40: 631–643.

Author Affiliations

Top

¹Dental Materials Research Center, Oral and Maxillofacial Pathology Department, Dental Faculty, Babol University of Medical Sciences, Babol, Iran
²Oral and Maxillofacial Surgery Department, Dental Faculty, Babol University of Medical Sciences, Babol, Iran

Submit your next manuscript and get advantages of SciTechnol submissions

- ❖ 50 Journals
- ❖ 21 Day rapid review process
- ❖ 1000 Editorial team
- ❖ 2 Million readers
- ❖ More than 5000  followers
- ❖ Publication immediately after acceptance
- ❖ Quality and quick editorial, review processing

Submit your next manuscript at • www.scitechnol.com/submission