



Cervical Neoplasia-Associated Schistosomiasis in HIV-Infected and Uninfected South African Women

Louis-Jacques van Bogaert^{1*}

Abstract

Background: Epidemiologic mapping of human immunodeficiency virus (HIV), urogenital schistosomiasis (UGS), and cervical cancer in sub-Saharan Africa exhibit substantial overlap. This prompted the hypothesis of a possible link between these conditions. Cross-sectional studies suggest an increased risk of HIV infection and transmission in women with UGS. In this perspective, it is hypothesized that systematic prevention of schistosomiasis in school girls might contribute to the reduction of transmission of HIV after sexual debut. UGS has not been etiologically linked to cervical cancer; however, like HIV, human papillomavirus (HPV) infection is promoted by breaches in mucosal barriers. The possible reciprocal effect of UGS and HIV co-infection in cervical carcinogenesis is unclear.

Methods: Cross-sectional study of 227 biopsy-diagnosed cervical pre-invasive and invasive lesions from 177 HIV-uninfected and 50 HIV-infected women.

Results: The overall prevalence of biopsy-diagnosed cervical schistosomiasis was 4.1%. The mean duration of progression from pre-invasive to invasive lesion was one and four years in HIV-infected and uninfected respectively. The relative distribution of pre-invasive and invasive lesions and Splendore-Hoeppli granulomas was similar in both groups.

Conclusion: No evidence was found of an increased rate of cervical schistosomiasis associated with HIV, or of any convincing effect of HIV-schistosome co-infection on cervical pre-invasive or invasive neoplasia.

Keywords

Schistosome; HIV; Uterine cervix; Pre-invasive lesions; Invasive cancer

Introduction

Schistosomes (S) are water-borne trematodes (flukes) that penetrate the skin and live in the blood. Depending on the species, the adults live in the veins of the intestine or bladder where they lay eggs. *S. haematobium* eggs penetrate through the bladder, rectal and reproductive organs mucosa. *S. mansoni* is mainly found in the bowel. Initially, the ova are embryonated (containing a fully

developed miracidium); about 20% remain in the tissues and become calcified; the majority is excreted in urine or faeces [1]. The presence of embryonated ova in the tissues triggers an inflammatory reaction called Splendore-Hoeppli granuloma. Later on, the inflammatory tissue evolves into a fibrous scar [2,3]. Water sanitation (extermination of snails) and praziquantel treatment of school children are the two weapons to combat this neglected tropical disease (NTD) [1]. Because of chronic contact with contaminated water in endemic areas, children and women carry the main burden of schistosomiasis. School-children preventive praziquantel campaigns are able to prevent schistosome-related morbidity.

Female genital schistosomiasis (FGS) affects a large number of women in endemic regions [4]. Because the disease affects both the urinary and genital tract in up to 75% of infected individuals, the condition was renamed “urogenital schistosomiasis” (UGS) [5].

Epidemiologic mapping studies of human immunodeficiency virus (HIV), *S. haematobium*, and cervical cancer in Africa depict a substantial overlap in many regions of sub-Saharan Africa [6]. This prompted the hypothesis of a possible link between the conditions, namely that UGS facilitates the transmission of HIV and human papillomavirus (HPV) [7,8]. Cross-sectional studies have shown that rural Zimbabwean women with FGS exhibit a 3-fold risk of having HIV compared to women without FGS [9]. In Tanzania, women with FGS had a 4-fold increased risk of HIV [10].

The link between HPV and ano-genital pre-invasive and invasive lesions is firmly established [11]. The contribution of HIV co-infection to the transition of pre-invasive to invasive lesions remains rather elusive. The influence of UGS on cervical carcinogenesis seems weak, at best [12]. To the best of our knowledge, the effect of HIV-schistosome coinfection on cervical pathology has not been investigated.

Materials

This was a cross-sectional study of 599 consecutive biopsy-diagnosed cases of schistosomiasis from the Limpopo Province public health facilities from January 2008 through December 2012. Among them 417 were cases of female UGS: 391 (93.8%) genital only and 26 (6.2%) vesical only (Figure 1).

During the same period, a total of 5400 cervical biopsies were examined; the general prevalence of HIV-infection in the 5400 women was 21.5%; evidence of schistosomal infection was found in 223 (4.1%) cervical biopsies. A portion of the biopsies was from 123 (55.2%) symptomatic patients complaining of lower abdominal pain and/or contact bleeding. Eighty four (37.7%) biopsies were indicated by an abnormal Pap smear. Sixteen (7.1%) cases were an incidental finding on a hysterectomy specimen for leiomyomas.

Figure 1 illustrates the anatomical distribution. The cervix was affected in 90.1% of the lower genital localizations; 177 (78.0%) were HIV-negative and 50 (22.0%) were HIV-positive. *S. haematobium* and *S. mansoni* were found in 214 (94.3%) and 13 (5.7%) cases respectively.

*Corresponding author: Louis-Jacques van Bogaert, Post Net Suite 7, Private Bag x8689, Groblersdal 0470, South Africa, Tel: +27132624339; Fax: +27132624339; E-mail: louis.vanBogaert@nhls.ac.za

Received: February 20, 2013 Accepted: March 25, 2013 Published: April 03, 2013

The specimens were processed conventionally. Four micron thick sections were stained with hematoxylin & eosin. The diagnosis of ova of *S. haematobium* was made in the presence of a terminal spike, and of *S. mansoni* in the presence of a lateral spike. The ova were either calcified (non-viable) or embryonated (viable, containing miracidia). The presence or absence of Splendore-Hoeppli inflammatory granulomas was recorded.

The cervical pathology was reported as cervicitis, cervical intraepithelial neoplasia (CIN), or invasive carcinoma. The diagnosis of cervicitis was made in the presence of ova, with or without inflammatory granulomas, but without epithelial abnormality. CINs were subdivided into CIN1 (low-grade) and CIN2+ (high-grade).

The statistical evaluation was carried out using column statistics, Student's t test, contingency table analysis, and 95% confidence intervals (CI) of proportions. The level of statistical significance was set at $P < 0.05$.

Results

Table 1 shows the age at diagnosis of schistosoma-associated cervical lesions in HIV-negative and -positive women. HIV-positive cases of chronic schistosomal cervicitis were on average 10 years older at the time of diagnosis than the HIV-negative ($P = 0.024$). The estimated average transition time from CIN2+ to invasion calculated from the age at diagnosis was one year in the HIV-positive and 4 in the HIV-negative cases.

Figure 1 and Table 2 illustrate the distribution of schistosoma-associated cervical pathology according to the HIV serostatus. The prevalence of cervicitis was significantly higher (although weakly so: $P = 0.048$) in HIV-uninfected women. The prevalence of cervical cancer was similar in both groups (chi-square = 0.78; $P = 0.38$).

Table 3 shows the distribution of Splendore-Hoeppli granulomas by pathology and HIV serostatus. The overall prevalence of the granuloma was similar in both groups (chi-square = 1.1; $P = 0.29$).

Discussion

It has been postulated that UGS exacerbates the effects of HPV infection, leading to swifter development and spread of cervical cancer [13,14]. The earliest study on the connection between invasive cervical cancer and UGS found only 1.7% association of the two conditions [12]. They and others concluded that UGS was not a determinant co-factor of cervical carcinogenesis, and that, in the absence of HPV, schistosomiasis was not an oncogenic causative or promoting agent for cervical cancer [2,12]. A Ghanaian study compared two groups of women from schistosoma-endemic and non-endemic areas. They

Table 1: Relative distribution by age at diagnosis of schistosoma-associated cervical pathology: HIV-uninfected vs. HIV-infected.

Pathology	HIV-negative	HIV-positive	t	P
Cervicitis	36.8 (11.2) [37.0] (16.0-65.0)*	47.0 (8.8) [42.5] (37.0-61.0)	2.3	0.024
CIN1	38.7 (10.5) [37.0] (27.0-70.0)	38.6 (9.8) [35.0] (33.0-56.0)	0.02	0.98
CIN2+	41.4 (9.8) [38.5] (30.0-62.0)	40.6 (7.7) [43.5] (29.0-52.0)	0.17	0.86
Invasive cancer	45.7 (12.4) [45.0] (24.0-75.0)	41.6 (9.4) [42.5] (29.0-61.0)	1.21	0.23

*Values are numbers (SD) [Median] (range)

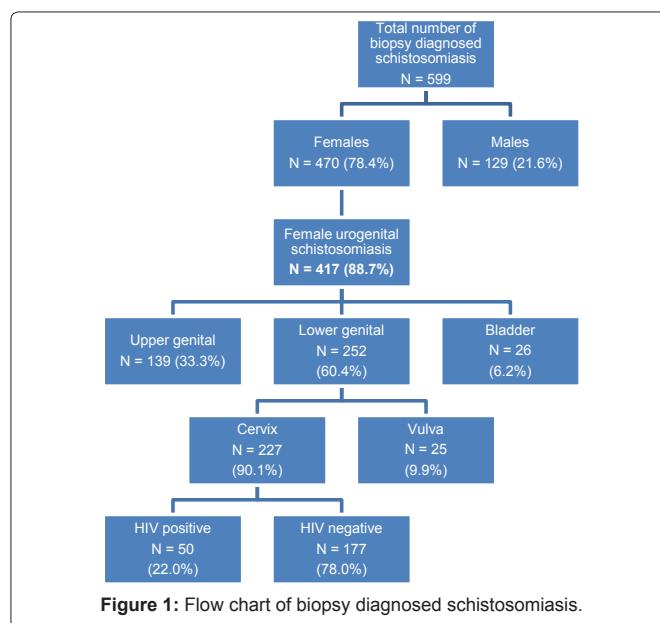


Figure 1: Flow chart of biopsy diagnosed schistosomiasis.

Table 2: Relative distribution by schistosoma-associated cervical pathology: HIV negatives vs. HIV positives.

Pathology	HIV-uninfected	HIV-infected	P
Cervicitis	68 (58.1) [48.7 - 67.2]*	8 (16.0) [7.2 - 29.1]	0.05
CIN1	19 (10.7) [6.6 - 16.3]	6 (12.0) [4.5 - 24.3]	0.10
CIN 2+	40 (22.6) [16.6 - 29.5]	19 (38.0) [24.6 - 52.9]	0.09
Invasive cancer	50 (28.2) [21.8 - 35.5]	17 (34.0) [21.2 - 48.8]	0.09
Total	177 (78.0)	50 (22.0)	

*Values are numbers (%) [95% confidence intervals]

Table 3: Distribution of the Splendore-Hoeppli reaction to schistosome by cervical pathology: HIV negatives vs. HIV positives.

Pathology	HIV-uninfected	HIV-infected	P
Cervicitis	4 (28.6) [8.4 - 58.1]*	**	***
CIN1	**	1 (14.3) [0.5 - 58.0]	
CIN 2+	3 (21.4) [4.7 - 50.8]	3 (42.9) [9.9 - 81.6]	0.38
Invasive cancer	7 (50.0) [23.0 - 77.0]	3 (42.9) [9.9 - 81.6]	0.38
Total	14 (68.4)	7 (31.6)	

*Values are numbers (%) [95%CI intervals]; ** No data available; ***Not applicable

found a comparable high rate of HPV infection in both and concluded that UGS did not contribute significantly to cervical cancer [15]. This view was confirmed in Zimbabwean rural women [16]. A Tanzanian report found that 14 out of 71 biopsy-diagnosed invasive cervical cancers showed associated schistosomal infection. It showed a high rate of association but the authors did not draw any conclusion on a possible cancer promoting effect [17].

The relationship between HIV and schistosomal infection is still conjectural. The inflammatory cells in the granulomas of affected

tissues express CD4+ T-cell receptors, which are the primary targets for HIV. They facilitate rapid binding of the virus. *S. haematobium* might increase HIV susceptibility through chronic immune modulation. It preferentially stimulates the Th2-type immune response and downregulates the Th1-type cytotoxic response that is important in the initial control of HIV infection [3]. There is also evidence that *S. haematobium* infection may speed up the progression of disease by raising viral load in co-infected subjects [18]. However, this was not the case with *S. mansoni* infection, suggesting possible differences between helminths species, stage and intensity of infection, and influence of additional co-infections [19]. On the other hand, treatment of schistosomal infection in HIV-1 infected subjects had no effect on the viral load [20].

A report of two cases of schistosomiasis of the uterine cervix in two HIV-positive women suggested that the absence of a granulomatous response to the ova should alert the pathologist to the possibility of HIV infection [21]. In our series, Splendore-Hoeppli granulomas were found only in 8.8% of the cases, with no statistically significant difference between the HIV-uninfected and -infected women. This low prevalence of granulomas is explainable by the fact that the granulomas are transient and followed by a fibrous scar reaction. The presence of granulomas depends on the time between the infection and biopsy.

It is currently hypothesized that UGS in both genders may constitute a significant risk factor for HIV acquisition, and that the prevention and treatment of UGS could reduce and possibly interrupt HIV transmission [1,3,4]. The rationale is that like with sexually transmitted infections (STI) mucosal barrier breakdown facilitates HIV entry. In Zimbabwe, Kjetland et al. found that after a one year follow up of 224 women with UGS, seven (3.1%) who were uninfected at baseline had seroconverted (P=0.098). This led to the conclusion that UGS caused a 3-fold risk of infection with HIV [9]. The cross-sectional nature of such studies, however, allows only determining an association rather than a causal relationship [3,19]. The only ethically acceptable way to investigate a causal relationship would be comparing different mass treatment strategies between prospective cohorts of school-girls to find out whether, when sexually active, HIV infection is decreased or even prevented by praziquantel prophylaxis [3,22].

It is important to keep in mind that the tissue lesions are not due to the adult worm but to the ova that are trapped in the tissues. The ova secrete proteolytic enzymes that provoke the granuloma which is progressively replaced by fibrotic deposits. Praziquantel kills the adult worm but has little if any effect on the ova, regardless of the HIV serostatus [23,24]. This is why periodic and regular treatment with praziquantel should be initiated at an early age before urogenital lesions caused by the ova occur [25].

Close to a decade back, a case report was published about a HIV-infected woman with CIN2+ carrying one low-risk and three high-risk HPV. The authors raised the question whether this was a “dangerous coexistence or coincidence” [26]? The answer is that any genital mucosal integrity breach increases the risk of transmission of any STI (including HIV and HPV). The agents involved in the loss of integrity include UGS, but not exclusively. HIV-infected women have a high rate of persistence of HPV, and a tendency to carry more than one subtype. Their risk of CIN2+ is high [27]. Despite the fact

that, arguably, cervical cancer is listed as an AIDS-defining condition, epidemiologic data from sub-Saharan Africa and elsewhere do not support this view [28-30]. No data indicate UGS as a risk factor for invasive cervical cancer either [12,14,15].

In conclusion, in the present population based investigation of biopsy-diagnosed cervical schistosomiasis in an endemic region 1) the prevalence of UGS was relatively low, 2) the prevalence of HIV infection, and 3) the prevalence of invasive cervical carcinoma were similar in UGS and non-UGS women. Since established schistosomal granulomas are resistant to treatment and a potential entry or exit portal for HPV and HIV there is a valid argument in support of integrated prevention of UGS as a potential prevention of HIV in girls and young women. Only time will tell if this will materialize.

References

1. Hotez PJ, Kamath A (2009) Neglected tropical diseases in sub-Saharan Africa: review of their prevalence, distribution, and disease burden. *PLoS Negl Trop Dis* 3: e412.
2. Rand RJ, Low JW (1998) Schistosomiasis of the uterine cervix. *Br J Obstet Gynaecol* 105: 1329-1331.
3. Mbabazi PS, Andan O, Fitzgerald DW, Chitsulo L, Engels D, et al. (2011) Examining the relationship between urogenital schistosomiasis and HIV infection. *PLoS Negl Trop Dis* 5: e1396.
4. Hotez PJ, Fenwick A, Kjetland EF (2009) Africa's 32 cents solution for HIV/AIDS. *PLoS Negl Trop Dis* 3: e430.
5. World Health Organization (2009) Neglected tropical diseases. Statement-WHO working group on urogenital schistosomiasis and HIV transmission. Geneva, Switzerland.
6. World Health Organization (2012) Control of Neglected Tropical Diseases. Geneva, Switzerland.
7. World Health Organization (2012) Report of an informal working group on urogenital schistosomiasis and HIV transmission. Geneva, Switzerland.
8. Hotez PJ (2009) Empowering women and improving female reproductive health through control of neglected tropical diseases. *PLoS Negl Trop Dis* 3: e559.
9. Kjetland EF, Ndhlovu PD, Gomo E, Mduluzi T, Midzi N, et al. (2006) Association between genital schistosomiasis and HIV in rural Zimbabwean women. *AIDS* 20: 593-600.
10. Downs JA, Mguta C, Kaatano GM, Mitchell KB, Bang H, et al. (2011) Urogenital schistosomiasis in women of reproductive age in Tanzania's Lake Victoria region. *Am J Trop Med Hyg* 83: 364-369.
11. Walboomers JM, Jacobs MV, Manos MM, Bosch FX, Kummer JA, et al. (1999) Human papillomavirus is a necessary cause of invasive cervical cancer worldwide. *J Pathol* 189: 12-19.
12. Moubayed A, Ziehe A, Peters J, Mwakyoma H, Schmidt D (1995) Carcinoma of the uterine cervix associated with schistosomiasis and induced by human papillomaviruses. *Int J Gynecol Obstet* 49: 175-179.
13. Petry KU, Scholz U, Hollwitz B, Von Wasielewski R, Meijer CJLM (2003) Human papillomavirus coinfection with schistosoma haematobium, and cervical neoplasia in rural Tanzania. *Int J Gynecol Cancer* 13: 505-509.
14. Richens J (2004) Genital manifestations of tropical diseases. *Sex Trans Inf* 80: 12-17.
15. Szela E, Bachicha J, Miller D, Till M, Wilson JB (1993) Schistosomiasis and cervical cancer in Ghana. *Int J Gynecol Obstet* 42: 127-130.
16. Kjetland EF, Dhlovu PD, Mduluzi T, Gomo E, Gwanzura L, et al. (2005) Simple clinical manifestations of genital schistosoma haematobium infection in rural Zimbabwean women. *Am J Trop Med Hyg* 72: 311-319.
17. Swai B, Poggensee G, Mtewe S, Krantz I (2006) Female genital schistosomiasis as an evidence of a neglected cause for reproductive ill-health: a retrospective histopathological study from Tanzania. *BMC Inf Dis* 6: 134.


18. Kallestrup P, Zinyama R, Gomo E, Butterworth AE, Mudenge B, et al. (2005) Schistosomiasis and HIV-1 infection in rural Zimbabwe: effect of treatment of schistosomiasis on CD4 count and plasma HIV-1 RNA load. *J Infect Dis* 192:1956-1961.
19. Brown M, Mawa PA, Kaleebu P, Elliott AM (2006) Helminths and HIV infection: epidemiological observations on immunological hypotheses. *Parasite Immunol* 28: 613-623.
20. Secor WE (2005) Immunology of human schistosomiasis: off the beaten path. *Parasite Immunol* 27: 309-316.
21. Prabhakaran V, Brown CMS (2004) Cervical schistosomiasis and neoplasia in HIV-infected patients. *Int J Gynecol Pathol* 23: 403-404.
22. Noblick J, Skolnik R, Hotez PJ (2011) Linking global HIV/AIDS treatments with national programs for the control and elimination of the neglected tropical diseases. *PLoS Negl Trop Dis* 5: e1022.
23. Kjetland EK, Mduluzi T, Ndhlovu PD, Gomo E, Gwanzura L, et al. (2006) Genital schistosomiasis in women: a clinical 12 month in vivo study following treatment with praziquantel. *Trans Roy Soc Trop Med Hyg* 100: 740-752.
24. Gryseels B, Polman K, Clerinx J, Kestens L (2006) Human schistosomiasis. *The Lancet* 368: 1106-1118.
25. Stoeveer K, Molyneux D, Hotez P, Fenwick A (2009) HIV/AIDS, schistosomiasis, and girls. *The Lancet* 373: 2025-2026.
26. Mosunjac MB, Tadros T, Beach R, Majmudar B (2003) Cervical schistosomiasis, human papillomavirus (HPV), and human immunodeficiency virus (HIV): a dangerous coexistence or coincidence? *Gynecol Oncol* 90:211-214.
27. Zeier MD, Botha MH, van der Merwe, Eshun-Wilson I, van Schalkwyk M, et al. (2012) Progression and persistence of low-grade cervical squamous intraepithelial lesions in women living with human immunodeficiency virus. *J Low Genit Tract Dis* 16: 243-250.
28. Centers for Disease Control and Prevention (1992) 1993 revised classification system for HIV infection and expanded surveillance case definition for AIDS among adolescents and adults. *MMWR Recomm Rep* 41: 1-19.
29. Bower M, Mazhar D, Stebbing J (2006) Should cervical cancer be an acquired immunodeficiency-defining cancer? *J Clin Oncol* 24: 2417-2419.
30. Chaturvedi AK, Madeleine MM, Biggar RJ, et al. (2009) Risk of human papillomavirus-associated cancers among persons with AIDS. *J Natl Cancer Inst* 101: 1120-1130.

Author Affiliation

Top

¹National Health Laboratory Service, Polokwane/Mankweng Hospital Complex and the University of Limpopo, Polokwane, South Africa

Submit your next manuscript and get advantages of SciTechnol submissions

- ❖ 50 Journals
- ❖ 21 Day rapid review process
- ❖ 1000 Editorial team
- ❖ 2 Million readers
- ❖ More than 5000 
- ❖ Publication immediately after acceptance
- ❖ Quality and quick editorial, review processing

Submit your next manuscript at • www.scitechnol.com/submission