



Case Report

A SCITECHNOL JOURNAL

Spontaneous Resolution of an Iatrogenic Ureterovaginal Fistula after Clinical Treatment of Hypothyroidism: A Case Study with a Review of the Literature

Giovanni Favero^{1*}, Cristina Anton¹, Maria Del Pilar Estevez Diz², Edmund Chada Baracat¹ and Jesus Paula Carvalho¹

Abstract

Association of hypothyroidism and disturbances of healing process is well known, but its exact effect on tissue integrity and mechanisms of dehiscence remain unclear. The relationship between hypothyroidism and iatrogenic ureterovaginal fistula is scarcely reported in the literature. We report the case of a 46-year-old woman who underwent cytoreductive surgery for ovarian cancer and developed an ureterovaginal fistula that was conservatively and successfully managed with thyroid hormone replacement after being diagnosed with myxedema.

Keywords

Hypothyroidism; Ureterovaginal fistula; Spontaneous resolution; Ovarian cancer

Introduction

Fistulas of the urogynecologic organs are a distressing complication of surgical treatment for gynecologic malignancies and may significantly affect patient's quality of life. Following major oncologic pelvic surgery approximately 1-5% of the patients will develop a urogenital fistula [1,2]. Important risk factors include extension and complexity of the intervention, cancer stage, infection, association of radiotherapy and presence of co-morbidities that can potentially harm the healing process [2]. Hypothyroid patients have long been thought to have higher risk of surgical morbidity and mortality [3]. It is also known that hypothyroidism is considered to have a substantial negative impact on wound healing and leakage due to collagen metabolism impairment [3].

Ureterovaginal leakage is the second most common type of urogenital fistula and its management can be either conservative or operative. The actual efficiency of the expectant treatment is relative poor and spontaneous closure is rarely achieved [4]. Besides,

*Corresponding author: Giovanni Favero MD, Department of Gynecology, Instituto do Câncer do Estado de São Paulo- ICESP, Faculdade de Medicina da Universidade de São Paulo, São Paulo- SP, Tel: ++55-11-38932000; E-mail: gdfavero@hotmail.com

Received: January 08, 2013 Accepted: March 17, 2013 Published: March 22, 2013

endourological or surgical repair provide excellent results and must be considered the therapy of choice [5].

We intend to describe a patient who underwent to a complex cytoreductive surgery for advanced ovarian cancer who developed an iatrogenic ureterovaginal fistula that was conservatively and successfully managed by means of thyroid hormone replacement after being diagnosed with severe hypothyroidism. An extensive literature search identified few patients treated expectantly and, to our best knowledge, no similar approach was implemented.

Case Report

A 46-year-old healthy woman was diagnosed with a high-grade serous ovarian adenocarcinoma, FIGO - stage IIIC. Initially, due to the presence of tumor in critical areas for surgical resection (hepatic hilus and superior mesenteric artery), the patient underwent neoadjuvant chemotherapy (6 cycles of carboplatin - AUC of 6 and paclitaxel 175 mg/m²). A severe thrombocytopenia secondary to carboplatin developed, leading to reduction in the AUC to 5 after the second cycle. Chemotherapy was otherwise well tolerated with no other significant adverse events, though the patient complained of fatigue and generalized edema attributed to chemotherapy. Imaging studies and CA-125 levels showed a satisfactory response to chemotherapy, allowing cytoreductive surgery to proceed. The intervention was considerably complex and involved: pelvic peritonectomy, supra and infra-mesocolic omentectomy, intestinal resection, lymphadenectomy, total hysterectomy and bilateral salpingoophorectomy. No intra-operative or immediate post-operative complication was detected and the patient was discharged after 6 days of hospitalization.

Approximately 3 weeks after the procedure, the patient presented to our institution with constant fluid drainage from the vagina. Gynecologic examination revealed the occurrence of a urogenital fistula located in the vaginal vault and the instillation of methylene blue dye into urinary bladder showed no leakage. A CT scan observed unequivocal signs of an approximately 9-mm large communication between the vagina and the distal left ureter (ureterovaginal fistula - UVF) (Figure 1), but no evidence of urinary ectasia or regional liquid

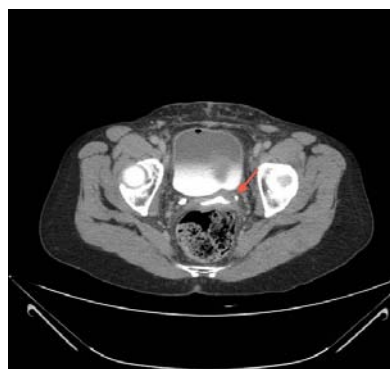

Figure 1: Axial CT-Scan shows contrast extravasations from the left distal ureter and free reflux of contrast material within the vagina (Red Arrow).

accumulation. Moreover, the patient's general performance and kidney function did not deteriorate. At this point, the woman was considered for an endourological fistula repair. Due to the persistence of general edema, thyroid function tests were now performed. Unexpectedly, we observed an elevated level of thyroid-stimulating hormone (TSH - 147.57 μ U/ml) associated with low concentrations of triiodothyronine (T3<39 ng/dL) and free-tetraiodothyronine (fT4<0.3 ng/dL). Consequentially, a surgical correction was contraindicated and thyroid hormone replacement (THR) was initiated with levothyroxine 100 mcg daily. The patient was also treated with a prophylactic antibiotic. An anti-thyroid peroxidase antibody level was elevated at 280 U/mL, consistent with autoimmune thyroid disease.

After 3 weeks of THR, the thyroid function tests had markedly improved (TSH- 81 μ U/mL; fT4- 0.53 ng/dL) and the clinical complaints and, surprisingly, the vaginal leakage had progressively disappeared. Another pelvic examination demonstrated no fluid drainage from the vagina and another CT scan confirmed the complete resolution of the left UVF (Figure 2). The thyroid-hormone levels completely normalized approximately 8 weeks after initiation of hormone replacement. Currently, oncologic follow-up reached 12 months and the patient exhibits evidence neither of tumor recurrence nor signs of urogenital fistula.

Discussion

Ureterovaginal fistula (UVF) is an abnormal opening between the vagina and the ureter, through which urine continually leaks. Naturally, UVF has a profound negative impact on patient's emotional well being and social life. Additionally, further complications such as recurrent urinary infection, damage of the vaginal tissue and kidney function may occur. The incidence of ureteral lesions secondary to major pelvic surgeries ranges between 1% and 5% [1]. They can be produced by different mechanisms, including: ureteral laceration or section, avulsion, extrinsic compression, total or partial ligation and revascularization [6]. Empirically, pelvic surgeons attribute the development of fistulas to local impairment of the ureter microvascularization and consequent tissue ischemia and necrosis that may lead to a slow and constant extravasation of urine and inflammation. In the reported case, this particular mechanism is probably responsible for the development of a genitourinary leakage, based on surgical and clinical findings.

Clinical or subclinical thyroid dysfunction is a relative common condition, particularly in women. The prevalence of clinical

hypothyroidism is about 1% percent of the female population, while subclinical hypothyroidism may affect approximately 8% percent of them [7]. Currently, it is well documented that hypothyroidism has a negative effect on tissue integrity and facilitates dehiscence [3]. However, its exact role in wound healing is a matter of discussion. The suppression of thyroid hormone probably cause disturbances in the synthesis and metabolic activation of collagen, as evidenced by the effects of thyroid hormone on hydroxyproline urinary excretion [8]. Additionally, hypothyroidism may impair the vascular supply to healing tissues [8,9]. In animal models, thyroid hormone is associated with the proliferation and secretion of fibroblasts in the process of wound healing [3]. Safer et al. [10] demonstrated that keratinocyte proliferation *in vitro* is retarded in T3-deficient medium relative to T3-replete medium; meanwhile, topical T3 stimulates epidermal proliferation *in vivo*. In the present case, the severe hypothyroidism was a likely contributor to the initial ureteral ischemic lesion and to the subsequent occurrence of a fistula.

Several antineoplastic agents can cause thyroid dysfunction in up to 20%-50% of patients [11]. Though the chemotherapeutic agents that this patient received are not known to cause thyroid dysfunction, they have also not been well studied in this regard, and it is possible that they led to an acute worsening of pre-existing autoimmune thyroid disease. Hypothyroidism can modify the kinetics and clearance of drugs, which may lead to undesirable side effects and in fact may have contributed to the severe thrombocytopenia noted [12]. Despite this, physicians frequently overlook drug-induced thyroid dysfunction because of the complexity of cancer treatment. Symptoms of hypothyroidism, such as fatigue, weakness, depression, memory loss, cold intolerance, and cardiovascular effects, may be incorrectly attributed to the primary disease or to the chemotherapy. In our case, underdiagnosis of thyroid dysfunction did have some important consequences for the patient. At a minimum, the symptoms have adversely affected her quality of life and one can speculate whether the fistula could have been avoided by a pre-operative thyroid hormone replacement. Although most international health organizations recommend against routine screening of asymptomatic patients, we now consider that it must be performed in all cancer patients.

Treatment of ureterovaginal fistula is surrounded by a number of controversies. Operative or endourologic treatments represent the most effective modalities with excellent rates of definitive resolution [4,5]. Spontaneous closure of ureterovaginal fistulas are rare, and only occur in about 2% of cases [13,14]. As a result, expectant management is only appropriate in patients who are clinically unsuitable for surgical intervention. However, our patient had closure of the fistula with initiation of thyroid hormone replacement. There are no prior reports of this in the literature, but the unexpected healing of the ureterovaginal fistula in this patient suggests that normalization of thyroid function may have contributed to the healing.

In conclusion, the reported case reinforces the association of thyroid disturbances and wound healing, and suggests that thyroid hormonal therapy in cases of hypothyroidism may be beneficial referring to ureterovaginal fistula resolution. Further studies are needed to provide explanations in regards to its metabolic pathophysiology and effect on tissue integrity and mechanisms of dehiscence.

References

1. Bai SW, Huh EH, Jung da J, Park JH, Rha KH, et al. (2007) Urinary tract

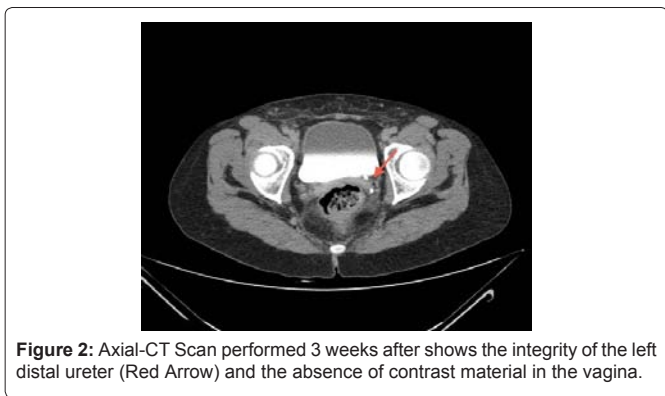


Figure 2: Axial-CT Scan performed 3 weeks after shows the integrity of the left distal ureter (Red Arrow) and the absence of contrast material in the vagina.

- injuries during pelvic surgery: incidence rates and predisposing factors. *Int Urogynecol J Pelvic Floor Dysfunct* 17: 360-364.
- Gerber GS, Schoenberg HW (1993) Female urinary tract fistulas. *J Urol* 149: 229-236.
 - Ekmektzoglou KA, Zografos GC (2006) A concomitant review of the effects of diabetes mellitus and hypothyroidism in wound healing. *World J Gastroenterol* 12: 2721-2729.
 - Singh O, Gupta SS, Mathur RK (2010) Urogenital Fistulas in Women: 5-year Experience at a Single Center. *Urol J* 7: 35-39.
 - Kumar A, Goyal NK, Das SK, Trivedi S, Dwivedi US, et al. (2009) Our experience with genitourinary fistulae. *Urol Int* 82: 404-410.
 - Vaidya B, Pearce SH (2008) Management of hypothyroidism in adults. *BMJ* 337: a801.
 - Hilton P, Ward A (1998) Epidemiological and surgical aspects of urogenital fistulae: a review of 25 years' experience in southeast Nigeria. *Int Urogynecol J Pelvic Floor Dysfunct* 9: 189-194.
 - Safer JD, Crawford TM, Holick MF (2004) A role for thyroid hormone in wound healing through keratin gene expression. *Endocrinology* 145: 2357-2361.
 - Smith TJ, Bahn RS, Gorman CA (1989) Connective Tissue, Glycosaminoglycans, and Diseases of the Thyroid. *Endocr Rev* 10: 366-339.
 - Safer JD, Crawford TM, Fraser LM, Hoa M, Ray S, et al. (2003) Thyroid hormone action on skin: diverging effects of topical versus intraperitoneal administration. *Thyroid* 13: 159-165.
 - Hamnvik OP, Larsen PR, Marqusee E (2011) Thyroid dysfunction from antineoplastic agents. *J Natl Cancer Inst* 103: 1572-87.
 - Nozières C, Damatte-Fauchery C, Borson-Chazot F (2011) Thyroid effects and anticancer treatment. *Ann Endocrinol* 72: 198-202.
 - Alonso Gorrea M, Fernandez Zuazu J, Mompó Sanchis JA, Jiménez-Cruz JF (1986) Spontaneous healing of ureterogenital fistulas: selection criteria. *Eur Urol* 12: 322-326.
 - Palacios Hernández A, Eguíluz Lumbreras P, Heredero Zorzo O, García García J, Cañada de Arriba F (2011) Spontaneous resolution of ureterovaginal fistula. *Arch Esp Urol* 64: 66-69.

Author Affiliations

Top

¹Department of Gynecology, Instituto do Câncer do Estado de São Paulo-ICESP, Faculdade de Medicina da Universidade de São Paulo

²Department of Medical Oncology, Instituto do Câncer do Estado de São Paulo- ICESP, Faculdade de Medicina da Universidade de São Paulo

Submit your next manuscript and get advantages of SciTechnol submissions

- ❖ 50 Journals
- ❖ 21 Day rapid review process
- ❖ 1000 Editorial team
- ❖ 2 Million readers
- ❖ More than 5000 
- ❖ Publication immediately after acceptance
- ❖ Quality and quick editorial, review processing

Submit your next manuscript at • www.scitechnol.com/submission