

Case Report

Community Acquired – Methicilin Resistant *Staphylococcus aureus* Neck Abscess with Bacteremia and Multiple Lung Abscesses

El Hammoui Mohammed Massine^{1*}, Abdellah Achir², Herrak Laila³, Mustapha El Ftouh³, Mohammed Toufik El Fassy Fihri³, El hassane Kabiri¹ and Abdellatif Benosman²

¹Department of Thoracic Surgery, Military teaching hospital Mohammed V, Faculty of Medicine and Pharmacy Souissi, Rabat, Morocco

²Department of Thoracic Surgery, Avicenne Hospital, Rabat, Morocco

³Department of Pneumology Avicenne Hospital, Rabat, Morocco

Abstract

A 17-year-old boy with no history of respiratory problems was admitted in our department because of cervical abscess with severe sepsis. Chest radiograph and computed tomography scan showed multiple lung abscesses and ground-glass opacities.

Cervical abscess was drained immediately, and cultures of the drainage material showed methicilin resistant *Staphylococcus aureus*.

The evolution was favorable after 10 days of mechanical ventilation and intravenous antibiotherapy (vancomycin). Radiological controls showed an evident favorable evolution with residual pneumatoceles. After a psychiatric evaluation the patient had a borderline personality with poor health conditions explaining probably the origin of the infection.

Keywords: Lung abscess; Neck abscess; *Staphylococcus aureus*; Methi resistant

Introduction

Staphylococcal Cervical abscess usually occur in children under 5 years old [1] after an upper respiratory illness or pharyngitis by *Staphylococcus aureus* (*S. aureus*) which is an important human pathogen in both hospitals and community. This bacteria is responsible of divergent clinical syndromes because of its capacity to produce several virulence factors [2].

S. aureus spread from initial sites of infection to the lymph nodes in the neck and is more likely to form an abscess more than cellulitis [1].

Community-acquired methicillin-resistant *S. aureus* (CA-MRSA) is a recent increasing proportion of *S. aureus* infections in people with no clear risk factors. This is why we report a new case of CA-

*Corresponding author: El Hammoui Mohammed Massine, Department of Thoracic Surgery, Military teaching hospital Mohammed V, Faculty of Medicine and Pharmacy Souissi, Rabat, Morocco-10000, Tel: (+212)0676017058; E-mail: hamoumimassine@hotmail.fr

Received: August 02, 2013 Accepted: September 20, 2013 Published: September 24, 2013

MRSA neck Abscess with bacteremia and multiple lung abscesses in a previously healthy young boy.

Case Report

A 17-year-old boy with no history of respiratory problems was admitted at the emergency department because of a 6 day history of fever and cervical painful mass. Physical examination revealed a right cervical abscess. Chest radiograph showed multiple bilateral lung nodules (Figure 1). Computed tomography scan with contrast showed a collection of the right neck, multiple lung abscesses and ground-glass opacities. Numerous well-defined cystic lesions (3-5 cm in diameter) throughout both lungs were visualized (Figure 2). The transthoracic echocardiogram noted no valvular involvement in particular no vegetations suggestive of infective endocarditic. Biology datas were abnormal with 21000 WBC/mm³ and C-reactive protein at 80 mg/l but fasting glucose was normal.

The cervical abscess was drained immediately, and cultures of the drainage material showed methicilin resistant *S. aureus* coagulase positive, the resistance was also to erythromycin and ofloxacin. The bacteria were sensitive exclusively to gentamycin, rifampicin and vancomycin. Blood cultures and bronchic material of aspiration revealed the same bacteria. Testing for HIV was negative. Even if the

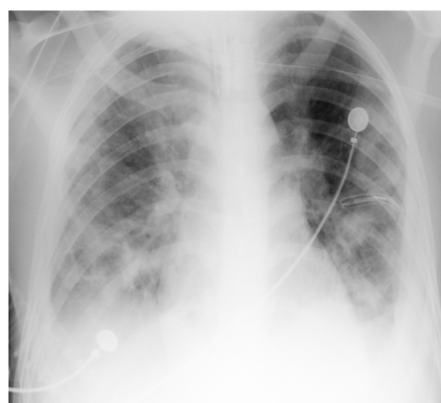

Figure 1: Chest Radiograph Showing Bilateral Lung Nodules.

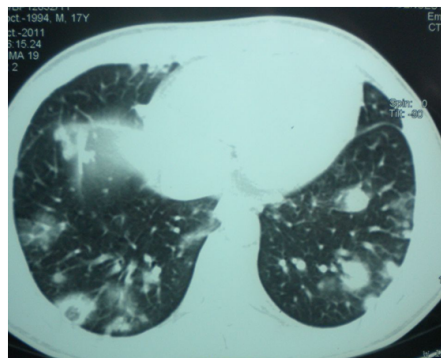


Figure 2: Computed Tomography Scan of the Chest shows Multiple Cysts and Abscesses.

patient had no increased rate of infections in the past. We test for complement and IgG and data showed no deficiency.

The patient had never been hospitalized or exposed to self injuries despite of his particular psychiatric profile. The evolution was favorable after 10 days of mechanic ventilation following surgery and intravenous antibiotherapy (vancomycin and gentamycin). Radiological controls showed an evident favorable evolution with residual pneumatoceles (Figure 3). After a psychiatric evaluation the patient seemed to have a borderline personality and behavior explaining poor health self-care.

Discussion

Methicillin-resistant *S. aureus* (MRSA) are identified as nosocomial pathogens throughout the world [3]. Risk factors for this infection include recent hospitalization or surgery, cardiovascular disease, malignancy, or diabetes mellitus, dialysis, and indwelling percutaneous medical devices and catheters [4].

Hospital-acquired MRSA contained the staphylococcal cassette chromosome (SCC) mec types I–III [5] and occurred in persons with known risk factors. However CA-MRSA is considered as a new pulmonary pathogen of young and previously healthy patients, it contains SCCmec type IV and produce Panton-Valentine leukocidin (PVL) [6] and shows resistance to four non beta lactam antimicrobial agents (erythromycin, clindamycin, tetracycline, and chloramphenicol) [7,8]. It has been associated with soft tissue abscesses and deep seated infections such as necrotizing pneumonia sometimes resulting in mortality rate up to 75% [6]. The MIC value of oxacillin for our case was low (11 µg/mL), and MRSA was susceptible to non-beta-lactam antimicrobial agents. These data of the molecular characteristics and drug susceptibility, together with the fact that MRSA was isolated from the abscess, are in close agreement with CA-MRSA.

The young immunocompetent patient had no evident risk factors and presented severe community lung and neck abscesses. The association of neck abscess and lung pneumonia explained that bacteria spread through systemic routes.

With similar clinical features an invasive infections with *S. aureus* is exhibiting the presence of virulent factors.

An hereditary deficit of NADPH oxydase associated with chronic granulomatosis hereditary disease can be suspected to explain this

severe infection, even if no similar cases in the patient family were reported. But according to our results this conditions wasn't done.

A particular attention should be given to people with psychiatric problems since they are easily exposed to have severe and resistant infections due to poor health care conditions.

Finally this reported case should invite particularly Moroccan physicians to include emerging CA-MRSA in the differential diagnosis of all various minor infections to prevent systemic diffusion of bacteria and life threatening complications in young immunocompetent patient particularly with psychiatric problems.

References

1. McAneney CM, Ruddy RM (2000) Chapter 45 - Neck Mass. In: Fleisher GR, Ludwig S (Eds), (4th edn). *Textbook of Pediatric Emergency Medicine*, Philadelphia: Lippincott Williams & Wilkins, 383-390.
2. Zetola N, Francis JS, Nuermberger EL, Bishai WR (2005) Community-acquired methicillin-resistant *Staphylococcus aureus*: an emerging threat. *Lancet Infect Dis* 5: 275-286.
3. Diekema DJ, Pfaller MA, Schmitz FJ, Smayevsky J, Bell J, et al. (2001) Survey of infections due to *Staphylococcus* species: frequency of occurrence and antimicrobial susceptibility of isolates collected in the United States, Canada, Latin America, Europe, and the Western Pacific region for the SENTRY Antimicrobial Surveillance Program, 1997–1999. *Clin Infect Dis* 32: S114-132.
4. Vandenesch F, Naimi T, Enright MC, Lina G, Nimmo GR, et al. (2003) Community-acquired methicillin-resistant *Staphylococcus aureus* carrying Panton-Valentine leukocidin genes: worldwide emergence. *Emerg Infect Dis* 9: 978-984.
5. Ito T, Ma XX, Takeuchi F, Okuma K, Yuzawa H, et al. (2004) Novel type V staphylococcal cassette chromosome mec driven by a novel cassette chromosome recombinase, ccrC. *Antimicrob Agents Chemother* 48: 2637-2651.
6. Yves Gillet, Bertrand Issartel, Philippe Vanhems, Jean-Christophe Fournet, Gerard Lina, et al. (2002) Association between *Staphylococcus aureus* strains carrying gene for Panton-Valentine leukocidin and highly lethal necrotising pneumonia in young immunocompetent patients. *Lancet* 359: 753-759.
7. Takano T, Higuchi W, Zaraket H, Otsuka T, Baranovich T, et al. (2008) Novel characteristics of community-acquired methicillin-resistant *Staphylococcus aureus* strains belonging to multilocus sequence type 59 in Taiwan. *Antimicrob Agents Chemother* 52: 837-845.
8. Enany S, Higuchi W, Okubo T, Takano T, Enany M, et al. (2007) Brain abscess caused by Panton-Valentine leukocidin-positive community-acquired methicillin-resistant *Staphylococcus aureus* in Egypt, April 2007. *Euro Surveill* 12: E070927.2.

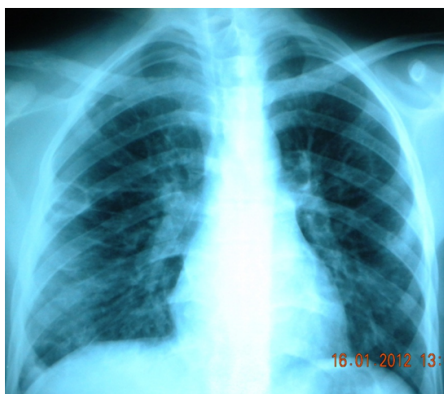

Figure 3: Chest Radiograph shows Residual Pneumatocoles.