Trabelsi et al., Analg Resusc: Curr Res 2013, S1
http://dx.doi.org/10.4172/2324-903X.S1-011

Analgesia & Resuscitation : Current Research

Case Report

A SCITECHNOL JOURNAL

An Uncommon Cause of Cardiac Arrest

Walid Trabelsi[1]*, Chihebeddine Romdhani[1], Anis Lebbi[1], Imen Naas[1], Haythem Elaskri[1], Iheb Labbene[1] and Mustapha Ferjani[1]

Abstract

A 23-year-old man presented with no previous medical history, was admitted for deep vein thrombosis of the left upper limb. After two days, he suffered severe dyspnea. A chest x-ray evidenced mediastinal nodes and cardiomegaly. A CT scan showed bilateral pulmonary thrombus with occlusion of the right pulmonary artery. Mediastinoscopy was performed and pathology examination of the nodeconfirmed the diagnosis of sarcoidosis. The patient's hemodynamic status worsened, with a sudden cardiac arrest caused by acute right-heart failure.

Keywords

Sarcoidosis; Acute heart failure; Echocardiography

Case Report

A 23-year-old male, with no previous medical history, was admitted into the Department of Internal Medicine for deep-vein thrombosis of the left upper limb. He was a young military recruit and showed no symptoms except for having mild exertional dyspnea for 1 year. A Doppler ultrasound showed a thrombus in the left basilic vein, which confirmed the diagnosis and an etiological research was commenced (including for cancer, antiphospholipid syndrome, and for inflammatory, autoimmune, or inherited diseases (antithrombin deficiency, protein C, and protein S deficiency).

After two days of receiving curative unfractionated heparin at an initial dose of 80 UI/kg body weight as a bolus, followed by infusion of 18 U/kg per h, the patient suffered severe dyspnea. A chest x-ray showed a bilateral hilar and mediastinal enlargement, reticulonodular opacities and cardiomegaly (Figure 1). A full blood count and serum biochemistry were normal, except for D-dimer, which was high (3500; normal range <500).

A chest CT-scan and arteriography of the pulmonary vessels showed bilateral pulmonary thrombus with occlusion of the right pulmonary artery and the left posterior pulmonary artery, in addition to a hypodense mediastinal mass that encompassed the mediastinal vessels with multiple paratracheal and paravertebral lymph nodes (Figure 2 and Figure 3).

The patient was transferred to the Pulmonology Department,



Figure 1: Chest X-ray showing mediastinal lymphadenopathy and cardiomegaly.



Figure 2: Non-contrast helical CT showing mediastinal paratracheal adenopathy (arrows). Small bilateral pleural effusions are also seen.

and a transthoracic echocardiograph showed normal left-ventricular (LV) function (LV ejection fraction, calculated using the modified Simpson's rule, was equal to 55%), a severely dilated right ventricular (end-diastolic right-ventricular diameter of 80 mm/10 mm, and an end-diastolic left-ventricle diameter of 42 mm); a flat inferior vena cava with no respiratory variability and a diameter of 29 mm; Figure 4) and a tricuspid regurgitant jet velocity of 4.75 m/s (Figure 5). Also noted, was a high estimated pulmonary pressure of 105 mmHg (central venous pressure measured with a central-vein catheter at 25 mmHg). The patient also had abundant ascites, portal hypertension, and moderately bleeding esophageal varices as assessed by esopho-gastro-duodenal endoscopy.

Because of the presence of mediastinal lymphadenopathy, a mediastinoscopic and anatomopathological examination was performed (Figure 6). Based on clinical, radiological, and pathological findings, a diagnosis of lymphadenopathy sarcoidosis was made and intravenous corticotherapy (methylprednisolone 1 mg/kg daily) was started.

After being hospitalized for 4 days, the hemodynamic status

***Corresponding author:** Walid Trabelsi, Department of Anesthesia and Intensive Care, Tunisian Military Hospital, Tunis, Tunisia, Tel: 00-216-24091983; Fax: 00-216-71391099; E-mail: walid_trabelsi2009@yahoo.fr

Received: April 17, 2013 **Accepted:** July 23, 2013 **Published:** July 26, 2013

SciTechnol
International Publisher of Science, Technology and Medicine

All articles published in Analgesia & Resuscitation : Current Research are the property of SciTechnol, and is protected by copyright laws. Copyright © 2013, SciTechnol, All Rights Reserved.

doi:http://dx.doi.org/10.4172/2324-903X.S1-011

of the patient worsened, with a sudden cardiac arrest caused by acute right-heart failure. In the intensive care unit, a Swan–Ganz catheter was applied and measured the following data: right atrial pressure of 41 mmHg, an end-diastolic right-ventricular diameter of 21 mm, systolic arterial pulmonary pressure of 120 mmHg, and a cardiac index of 0.9 L/min/m^2. Also noted was the paradoxical motion of the interventricular septum, as assessed by transthoracic echocardiography (Figure 7 and Figure 8).

The patient died a few hours later despite receiving cardiac vasopressors, NO, corticosteroids, and sildenafil.

Discussion

Sarcoidosis is asymptomatic in 50% of cases. Its prevalence, incidence, and severity disease are higher among black patients (39 cases per 100,000 in black women vs. 12.1 in white women) [1].

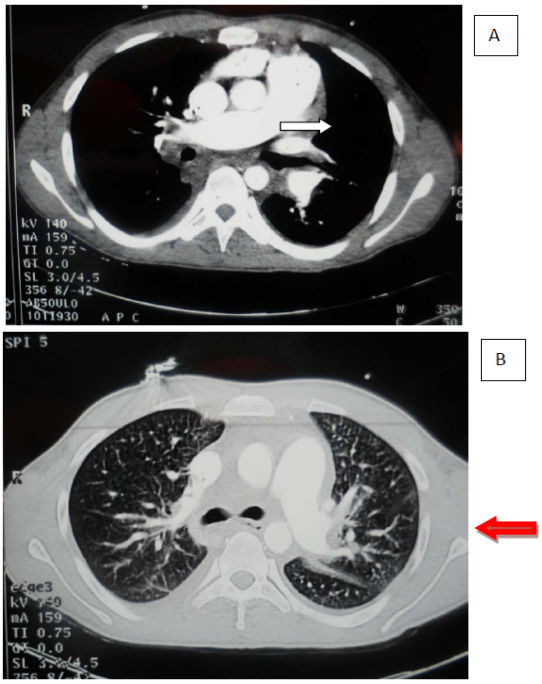

Figure 3: A) CT arteriograph showing occlusion of the right pulmonary artery due to external compression from a mass (white arrow). **B)** The left pulmonary artery is nearly completely occluded from the lymph-node mass (red arrow). Extensive mediastinal lymphadenopathy was also seen.

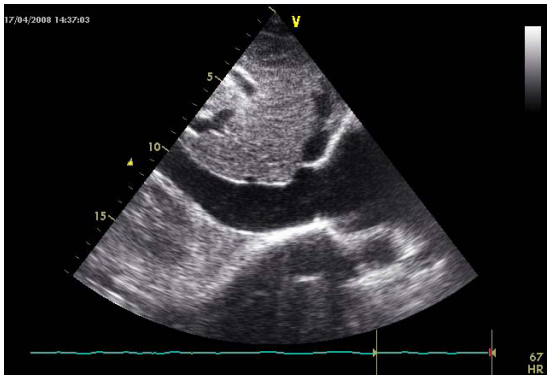

Figure 4: Longitudinal view of the inferior vena cava.

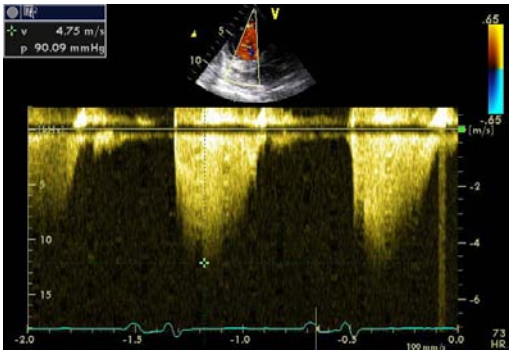

Figure 5: Tricuspid velocity regurgitation.

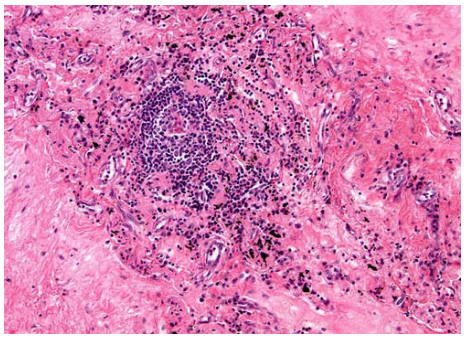

Figure 6: Histology images (intermediate-power; 400×) of a specimen from the lymphadenopathy biopsy. It showed well-formed, non-necrotizing epithelioid granuloma.

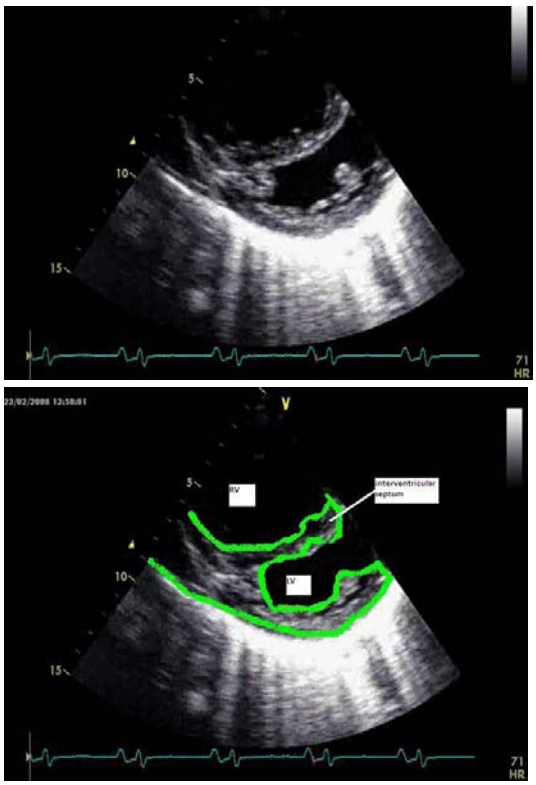

Figure 7: Parasternal short-axis view at the papillary-muscle level during cardiac systole.

doi:http://dx.doi.org/10.4172/2324-903X.S1-011

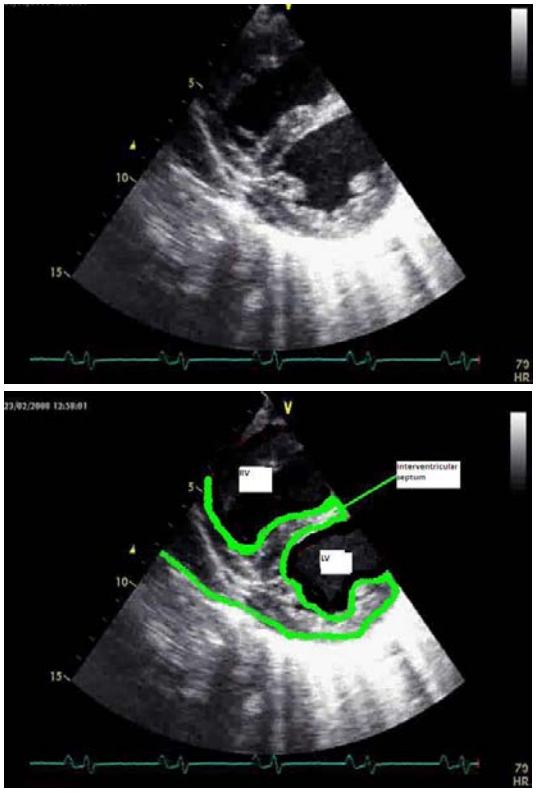

Figure 8: Parasternal short-axis view at the papillary-muscle level during cardiac diastole.

Several hypotheses have been suggested for the association between sarcoidosis and a pulmonary embolism (PE). It could be a result of compression caused by extrinsic lymphadenopathy. Indeed, in sarcoidosis type I, bilateral lymphadenopathy may compress the tracheo-bronchial tree, but also may affect a vascular tree that has a perfusion defect [2].

Goffman et al. have reported on a patient with mediastinal-pulmonary sarcoidosis, which was identified as an infusion disorder by scintigraphy with no ventilation disorder [3]. These authors considered a diagnosis of PE, but an angiograph found extrinsic compression without a defect in the vascular lumen (in contrast to our case where an intra-arterial thrombus was seen). This is why we started our patient on steroids and anticoagulant therapy, in contrast to Goffman et al.'s study where only steroids were given.

There are several possibilities to explain this clinical picture. The first is that this patient has had a pulmonary embolism secondary to venous thrombosis of the upper limb. The second is the extrinsic compression of the pulmonary artery and finally the presence of vascular granuloma. In fact, thrombosis, secondary to vascular granulomas, has been described in sarcoidosis [4]. One study reported on 128 biopsies performed in patients with sarcoidosis [5]. A breach of the pulmonary vessel was found in 88 samples (69%). Of these positive samples, venous involvement was the most frequent incident (92%), it was isolated in 61% of cases, and was associated with arterial disease in 31%. Only 8% of the samples showed arterial disease alone.

In-hospital cardiac arrests (IHCA) are a relatively common occurrence: their reported incidence varies, but occurs within the range of 1–5 per 1000 admissions [6]. The European Resuscitation Council defines several causes for this event; some cases of are reversible and are often referred to as the six H's (hypoxia, hypovolemia (associated with trauma, anaphylaxis, sepsis), hyperkalemia, hypokalemia, hypocalcemia (and other metabolic abnormalities) and hypothermia; and the four T's: thrombosis (coronary or pulmonary), tamponade (cardiac), toxins, and tension pneumothorax) [7]. Theses causes can be treated and, thus, many patients recover. However, in our case, we think that death was the consequence of an "untreatable" etiology of PE (sarcoidosis). This represents a new facet to practitioners, if treatable causes of cardiac arrest are secondary to a non-treatable etiology.

Funding Source

Financial support was provided by departmental and institutional funding from the Tunisian Military Hospital.

References

1. Rybicki BA, Major M, Popovich J Jr, Maliarik MJ, Iannuzzi MC (1997) Racial differences in sarcoidosis incidence: a 5-year study in a health maintenance organization. Am J Epidemiol 145: 234-241.
2. Westcott JL, DeGraff AC Jr (1973) Sarcoidosis, hilar adenopathy, and pulmonary artery narrowing. Radiology 108: 585-586.
3. Goffman TE, Bloom RL, Dvorak VC (1984) Topics in radiology/case of the month. Acute dyspnea in a young woman taking birth control pills. JAMA 251: 1465-1466.
4. Barst RJ, Ratner SJ (1985) Sarcoidosis and reactive pulmonary hypertension. Arch Intern Med 145: 2112-2114.
5. Rosen Y, Moon S, Huang CT, Gourin A, Lyons HA (1977) Granulomatous pulmonary angiitis in sarcoidosis. Arch Pathol Lab Med 101: 170-174.
6. Sandroni C, Nolan J, Cavallaro F, Antonelli M (2007) In-hospital cardiac arrest: incidence, prognosis and possible measures to improve survival. Intensive Care Med 33: 237-245.
7. Nolan JP, Soar J, Zideman DA, Biarent D, Bossaert LL, et al. (2010) European Resuscitation Council Guidelines for Resuscitation 2010 Section 1. Executive summary. Resuscitation 81: 1219-1276.

Author Affiliation

Top

[1]*Department of Anesthesia and Intensive Care, Tunisian Military Hospital, Tunis, Tunisia*

Submit your next manuscript and get advantages of SciTechnol submissions

- 50 Journals
- 21 Day rapid review process
- 1000 Editorial team
- 2 Million readers
- More than 5000 facebook fans
- Publication immediately after acceptance
- Quality and quick editorial, review processing

Submit your next manuscript at ● www.scitechnol.com/submission

This article is published in the special issue, **In-hospital Cardiac Arrest** and has been edited by Dr. Kasper Adelborg, Regional Hospital of Randers, Denmark