

Unusual presentation of diabetic ketoacidosis associated with ascariasis and fungal esophagitis: A case report

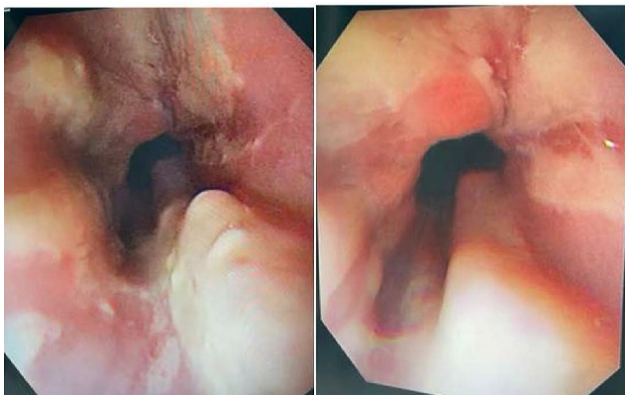
Rabia Khalid Alduraibi*, Elzaki Mohamed Elzaki and Ammar Alammari
King Fahad Specialist Hospital, KSA

Gastrointestinal symptoms are most commonly observed in patients with diabetic ketoacidosis (DKA), which usually resolves completely with therapy. However, gastrointestinal symptoms may persist after DKA is resolved. Patient concerns: A 22-year-old female was admitted to hospital for epigastric pain and persistent vomiting. The results of laboratory examination showed fungal esophagitis complicated by DKA.

Diagnosis: The patient was diagnosed with DKA associated with ascariasis and fungal esophagitis.

Outcome: The patient was discharged after treatment

Lessons: In this case, despite the correction of metabolic acidosis, persistent nausea, vomiting and dysphagia can be a sign of esophagitis in patients with type 1 diabetes. Therefore, physicians should be aware of fungal infections associated with type 1.



Recent Publications:

1. Yakoob J, Jafri W, Abid S, et al. Candida esophagitis: risk factors in non-HIV population in Pakistan. *World J Gastroenterol.* 2003;9:2328–31.
2. Saeed A, Assiri A, Zaidi Z, et al. Fungal esophagitis in a child with insulin dependent diabetes mellitus. *J Coll Phys Surg Pak.* 2016;26:712–13.

17th European Diabetes and Endocrinology Congress

November 20-21, 2023

Dubai, UAE

3. Badarinarayanan G, Gowrisankar R, Muthulakshmi K. Esophageal candidiasis in non-immune suppressed patients in a semi-urban town, Southern India. *Mycopathologia*. 2000;149:1–4.
4. Nassar Y, Eljabbour T, Lee H, et al. Possible risk factors for candida esophagitis in immunocompetent individuals. *Gastroenterol Res*. 2018;11:195–9.
5. Bonacini M, Young T, Laine L. The causes of esophageal symptoms in human immunodeficiency virus infection: a prospective study of 110 patients. *Arch Intern Med*. 1991;151:1567–72

Biography

Rabia Khalid Alduraibi has completed her Medical school from Qassim University and Family medicine resident from King Saud University Hospital. She is currently Diabetes follow at King Fahad Specialist Hospital.