



Research Article

A SCITECHNOL JOURNAL

The Micromorphological Course of Irradiation-Induced Oral Mucositis in Rat

Eva Lindell Jonsson^{1*}, Per-Olof Eriksson¹, Mohammad Saadat², Michael Blomquist³, Mikael Johansson⁴ and Karin Nylander⁵, Göran Laurell¹

Abstract

Objectives: To establish an experimental radiation-induced mucositis model in the Sprague-Dawley rat, and to use this model to study the temporal changes in morphology, including invasion by immune cells (polymorphonuclear (PMN) cells and macrophages – both activated M1 macrophages and wound healing M2 macrophages) following irradiation.

Materials and methods: Irradiation was given as a single fraction treatment to the entire head using a conventional high-energy linear accelerator (Varian Clinac 2300 C/D). Treatment was in as single fractions of 20 Gy, using 6 MV photons. Morphological changes in irradiated lingual and buccal tissues were assessed using a haematoxylin-eosin staining, while invasion by immune cells was established by immunohistochemistry.

Results: A single dose of 20 Gy gave rise to ulcerations and a manifest oral mucositis. Atrophy of the epithelial layer was seen on day 5 in the buccal specimens and on day 7 in the lingual specimens. Regeneration of the epithelial layer was observed day 13 in the buccal specimens and on day 17 in the lingual specimens. A peak influx of PMN cells was observed before a peak of macrophages was seen. The concentration of PMN cells decreased after the acute phase had passed – and was then lower than in control samples. A peak in the influx of general macrophages (ED 1 stain) was observed day 9, and also on day 11 of M2 macrophages (ED 2 stain).

Conclusion: An experimental model of irradiation-induced oral mucositis was established in the Sprague-Dawley rat, using a high-energy linear accelerator, which provides a research platform for the study of radiotherapy-induced oral mucositis pathogenesis. A uniform morphological pattern was observed, showing a rapid healing process following irradiation. An influx of PMN cells peaked before the macrophage peak, whereas those peak of M2 macrophages occurred 2 days after the peak of general macrophages.

Keywords

Radiotherapy; Oral mucositis; Experimental model; Animal model

Introduction

Squamous cell carcinoma of the head and neck, SCCHN, is the 6th most common malignancy worldwide with more than half a

million new cases and 350,000 deaths annually. The vast majority of these cases constitutes of patients with cancer of the oral cavity or the oropharynx [1]. Curative treatment for SCCHN can be achieved through surgery, radiotherapy (RT), chemotherapy or a combination of these modalities. RT combined with surgery is the mainstay of curative treatment in advanced clinical stages (III and IV) of oral cancer due to the aggressiveness of these lesions. Oral mucositis (OM) is the most common adverse effect of RT, presenting clinically as a continuum of erythema, oedema and ulceration, with or without pseudomembrane formation of the oral mucosa (Figure 1) [2]. For nearly all patients treated with RT to the oral cavity [3,4], OM causes significant acute morbidity [5]. OM has been reported by patients to be the worst acute side effect of RT [6], constituting the main dose-limiting side effect [5] resulting from secondary side effects such as oral pain, dysphagia, weight loss or the need for enteral nutrition [6]. OM can indirectly affect the success of RT by limiting the patient's ability to tolerate optimal tumour-killing treatment, thus reducing the efficacy of the treatment. In cases where it causes the patients to interrupt their scheduled treatment, it may even affect the long-term survival [7]. In a clinical setting, OM usually begins after a cumulative exposure to 15 Gy, worsening markedly if the total dose exceeds 60 Gy [8]. The standard therapy for OM is topical analgetics and systemical opioids, as no approved standard remedy against inflammation has yet been found to prevent or treat RT-induced OM [9], which has led to a questioning of the theory that inflammation is the chief cause of OM. It is important that the molecular events leading to RT-induced mucosal injury should be identified so that they can provide targets for mechanistically based interventions to prevent or treat OM. A serious problem with determining the appropriate treatment for OM is that the immunological mechanisms underpinning the condition have not been elucidated. It is known that irradiation leads to an accumulation of immune cells in the subepithelial layer [10], but the immunological mechanisms of mucosal injury are relatively difficult to study in humans. Instead, laboratory animal models form the platform from which a basic understanding of RT-induced OM can be sought. Any new potential treatment must first be subjected to rigorous testing in well studied animal models to test its efficacy and safety

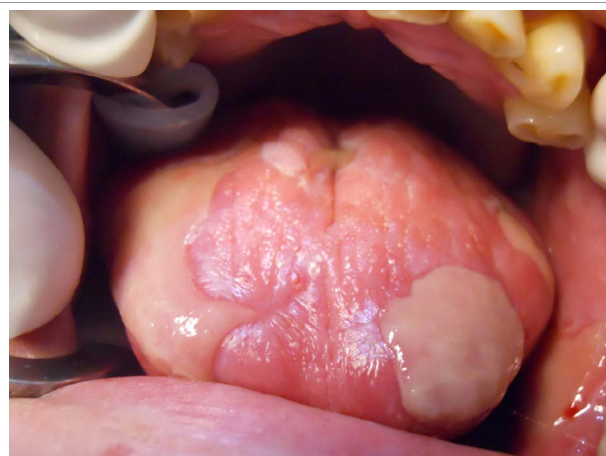


Figure 1: OM is presenting clinically as a continuum of erythema, oedema and ulceration, with or without pseudomembrane formation of the oral mucosa.

*Corresponding author: Eva Lindell Jonsson, (MD), Department of Surgical Sciences, ORL section, Uppsala University, Uppsala, Sweden, Tel: +46186119197; E-mail: eva.lindell.jonsson@surgsci.uu.se

Received: September 02, 2015 Accepted: October 21, 2015 Published: October 28, 2015

before proceeding to preliminary clinical trials. A variety of animal models have been used in research into OM [11], including mouse [12] and hamster [13-15], but the more physiologically stable rat models have the advantage of the size of the tongue and cheeks, which can be handled more easily than those of smaller rodents. There are several different immune cells that are of interest to study in relation to OM. Polymorphonuclear cells (PMN cells) are white blood cells that in peripheral tissues consist mostly of neutrophil granulocytes. Neutrophils are a type of phagocyte and the most abundant white blood cell type in mammals. They are an essential element in the innate immune system and major contributors to its response to infection, inflammation, and tissue damage such as irradiation-induced injury. Development of oral mucositis due to radiotherapy is linked to an increased number of oral neutrophils [16]. Macrophages are another category of white blood cells that play a critical role in the innate immune system. They gradually replace neutrophils as the predominant cell type in the wound. As a group, macrophages show considerable differences among themselves as regards morphology, phenotypic marker expression, and effect or function. This results from the specialization of circulating monocytes depending on the local micro-environment to which they are exposed during differentiation [17]. There are two major types of activated macrophages: classically activated macrophages (M1 macrophages) and wound-healing macrophages (M2 macrophages or so-called alternatively activated macrophages) [18]. Irradiation causes a shift to M1 macrophages [19]. In rat, ED1 and -2 are cellular markers for activated microglia, monocytes, and macrophages. ED1 is a general macrophage marker expressed by the majority of tissue macrophages but only weakly by peripheral blood granulocytes, whereas ED2 is expressed by M2 macrophages in most tissues. When studying inflammation, it is of interest to study the different form of macrophages, since they have different functions. To gain further knowledge, we conducted a study on the morphological course of mucositis in radiation-exposed rats over time using immunohistochemistry to describe the invading inflammatory cells during RT-induced mucositis [20].

Material and Methods

The study was divided into two stages. The first stage of the study was to establish a reproducible model where oral mucositis could be induced in the Sprague-Dawley rat following a single irradiation fraction. The second part of the study aimed at mapping recruitment of inflammatory cells during development of radiation-induced mucositis.

Animal care

The animals were kept in a 12 hour light / 12 hour dark cycle and were fed *ad libitum*, 3 or 4 animals in each cage. Before irradiation, animals were anaesthetized with an intravenous injection of propofol solution (Diprivan®, AstraZeneca, Södertälje, Sweden), 10 mg/mL (20 mg/kg), through a tail vein, and by adding a bolus dose of pentobarbital sodium (Pentobarbitalnatrium, Apoteksbolaget, Stockholm, Sweden), 100 mg/mL (40 mg/kg), given intraperitoneally. At the end of the experiment the rats were killed with an intraperitoneal overdose of sodium pentobarbital.

Irradiation procedure

Radiotherapy was given as a single fraction dose to the entire head using a conventional high-energy linear accelerator (Varian Clinac 2300 C/D). The individual fractions were of 16, 18 or 20 Gy using 6 MV photons at a dose rate of 3 Gy/min. Irradiation was performed on

anaesthetized rats, each temporarily immobilized in a net restrainer. This was positioned in the beam so that the rat's head was located at the isocenter plane of the treatment machine (100 cm). The whole head was irradiated, but the oral tissue in themselves were not directly exposed. The rats were irradiated two at a time with a set-up of double net restrainers placed side by side. Beam size was 30 × 9 cm². Perspex plates were placed both above and beneath the net restrainers to provide photon build-up (thickness of 15 mm) and back-scatter. For practical reasons, the Perspex plates were not in direct contact with the rat's head, thus introducing a narrow air-gap both upstream and downstream in the beam longitudinal direction. The air gap causes a loss of transient electronic equilibrium and hence a small dose reduction. By increasing the quantity of monitor units delivered by 5%, we compensated for this effect.

Establishing a dose-response relationship

A total of 14 female Sprague-Dawley rats weighing between 201 and 225 grams were used in the first part of the study. These were randomly divided into four groups of 3-4 animals each. Three groups were irradiated with a one-time radiation dose to the head and neck region. Each group was exposed to a dose of 16, 18 or 20 Gy respectively. The 4th group was the control group.

Assessment of mucositis *in vivo*

The macroscopic criteria for an established OM were: widespread ulceration and pseudomembrane formation. All animals were assessed and weighed daily. In this dose-response part of the study, animals with a 10% loss of initial weight and poor general condition was given a daily subcutaneous injection of 10 ml 5% glucose to help sustain them. Animals were sacrificed if they had lost at least 20% of initial body weight. Tissue specimens were then harvested and fixed for morphological study.

Longitudinal morphological characterization of mucositis and invasion of immune cells

A total of 30 male Sprague-Dawley rats weighing between 210 and 230 grams were used for the second part of the study the animals were divided into 8 groups, of which 7 with 4 animals each were irradiated in the head and neck region with a single dose of 20 Gy. The 8th group was the control group of 2 animals. Two animals died on day 1. The remaining 28 animals (26 in the irradiation groups and 2 controls) were consequently sacrificed and dissected at 5, 7, 9, 10, 11, 12, 14 and 17 days after irradiation. Four animals were sacrificed in each of these days. On day 17 the 2 controls were sacrificed, together with the remaining 2 irradiation group animals. The tongue and cheek mucosa of each animal were dissected and fixed separately.

Paraffin wax embedding

All dissected specimens were fixed in 4% buffered formalin solution containing 0.0027 mol/L potassium chloride, 0.0015 mol/L potassium dihydrogen phosphate, 0.1369 mol/L sodium chloride, and 0.0080 mol/L disodium hydrogen phosphate. The skulls were immersed in the same fixative for 1 week. The specimens were then dehydrated in graded ethanol and embedded in paraffin wax. The paraffin-embedded specimens were sectioned 5 µm thick and deparaffined in xylene and rehydrated in a graded series of ethanol.

Immunohistochemical procedure

Endogenous peroxidase activity was blocked with 0.3% H₂O₂ (3% H₂O₂ for the ED1 antibody) and the slides were then rinsed in

PBS. After rinsing, non-specific binding-sites were blocked with 5% rabbit (ED1, ED2) or 5% swine (PMN) serum for 30 minutes at room temperature. The sections were incubated with the primary antibody (Table 1) at the manufacturer's recommendation for 60 minutes at room temperature and then rinsed with PBS. A biotinylated rabbit anti-mouse antibody was applied for 30 minutes. The slides were washed in PBS, followed by incubation with an avidin-biotin peroxidase complex (Vector Elite Pk 6100 standard, Vector Laboratories, Burlingame, CA, USA). The peroxidase activity was visualized by diaminobenzidine (DAB) (Vector Peroxidase substrate kit SK-4100, Vector Laboratories, Burlingame, CA, USA). Slides incubated with normal serum only, excluding the primary antibody, were used as negative controls. Standard haematoxylin-eosin stainings were performed for all specimens.

Photodocumentation

The haematoxylin-eosin stained sections analysed using the scanning microscope Aperio Scan Scope XT and the accompanying software Image Scope™ (Leica, Germany). The Immunohistochemical sections were examined and photo documented using a Zeiss (Germany) AxioPhot light microscope fitted with an Axio Cam MRc camera under control of Zen 2012 blue edition software (Zeiss, Germany).

Morphological assessment

This study is a double blind evaluation that was carried out by properly calibrated evaluators. All samples were blinded and reviewed by one of the authors (ELJ), assisted by one author (MS) for the haematoxylin-eosin staining. The grade of ulceration and epithelial status was evaluated for all samples and the presence or absence of filiform papillae was noted for the lingual samples in the second part of the study using the following scale (Table 2). The staining results for ED1, ED2 and PMN were scored in the submucosa, using an 1125 µm² grid in snapshots of 20 x magnifications, where 60 squares were counted per sample.

Ethical considerations

The study was approved by the University of Umeå Institutional Review Board (registration number A 120-10).

Results

Establishing a dose-response relationship

Part I aims at establishing the correct irradiation-dose for the longitudinal morphological characterization of OM.

Table 1: The different antibodies used for detection of macrophages (ED1, ED2) and polymorphonuclear cells (PMN).

Target	Name of antibody
ED1	Serotec MCA341R, Mouse-anti-Rat
ED2	Serotec MCA342R, Mouse-anti-Rat ED2
PMN	Cedarlane CL AD 51140, absorbed Rabbit-anti-Rat PMN

Table 2: The microscopic grading scale used to evaluate ulceration and epithelial status; and in the tongue, the presence or absence of filiform papillae.

Haematoxylin-eosin staining			
Score	Epithelial thickness grading	Ulceration	Filiform papillae
0	None	None	Presence
1	Decreased	Early signs	Absence
2	Normal	Evident	
3	Increased		

Assessment of weight loss and OM

A uniform weight loss was seen after day 5. Between day 11 and day 14 a weight gain was seen in all groups, accelerated in those animals that had previously shown the greatest weight loss, i.e. those treated with higher radiation doses (Figure 2). Twenty animals with a 10% loss of initial weight and poor general condition were given a daily subcutaneous injection of 10 ml 5% glucose and the 4 animals that had received an irradiation dose of 20 Gy and one animal that had received 18 Gy were sacrificed on day 9 due to >20% weight loss

Histological assessment

Only at 20 Gy was the effect on the epithelium severe enough to cause ulceration (Table 3).

Longitudinal morphological characterization of mucositis and invasion by immune cells

Assessment of weight loss and mucositis: In part two weight losses during the experiment ranged between 0 and 75 grams for the irradiated animals, whereas the controls showed a weight gain during the study (Figure 3). Oral mucositis was evident from day 7 to 14, when a noticeable repair process started. By day 17 all animals showed almost complete resolution of mucositis, with only minimal mucosal erythema remaining (Table 3).

Morphological observations

Haematoxylin-eosin: On day 7, lingual specimens started to show atrophy of the epithelial layer, and the filiform papillae had disappeared by day 9 after irradiation. A peak in ulceration was observed on day 10. Pseudomembrane formation was simultaneously demonstrated in areas exhibiting progression of mucositis, with focal areas of ulceration including an increased number of inflammatory cells in the lamina propria and total absence of submucosal papillae.

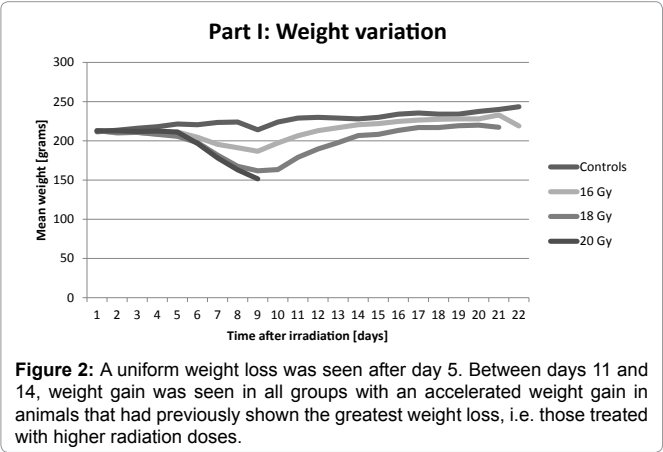


Figure 2: A uniform weight loss was seen after day 5. Between days 11 and 14, weight gain was seen in all groups with an accelerated weight gain in animals that had previously shown the greatest weight loss, i.e. those treated with higher radiation doses.

Table 3: The macroscopic evaluation of mucositis at different time points.

Day	Clinical signs of mucositis
5	No evident macroscopic signs of mucositis.
7	Red, swollen and fibrin-covered mucosa.
9	Macroscopic evident severe mucositis in the whole oral cavity.
11	Macroscopic evident severe mucositis in the whole oral cavity.
12	Macroscopic evident severe mucositis in the whole oral cavity.
14	Regression of mucositis, with persistent erythema, but no fibrin pseudomembranes or macroscopically evident ulceration.
17	Complete regression of oral mucositis in all sites except for persisting mild gingivitis.

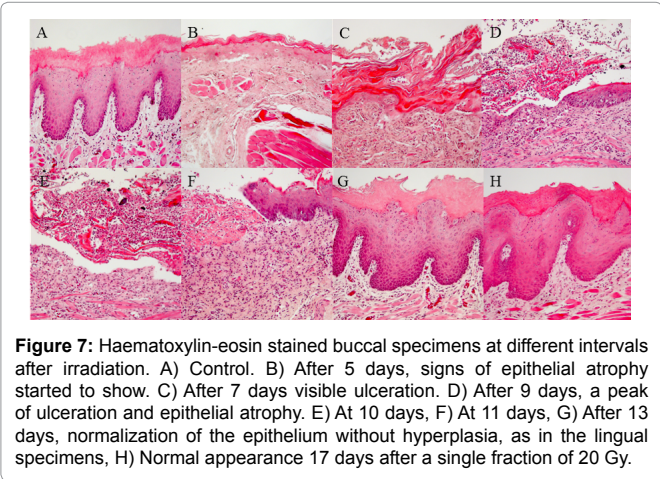
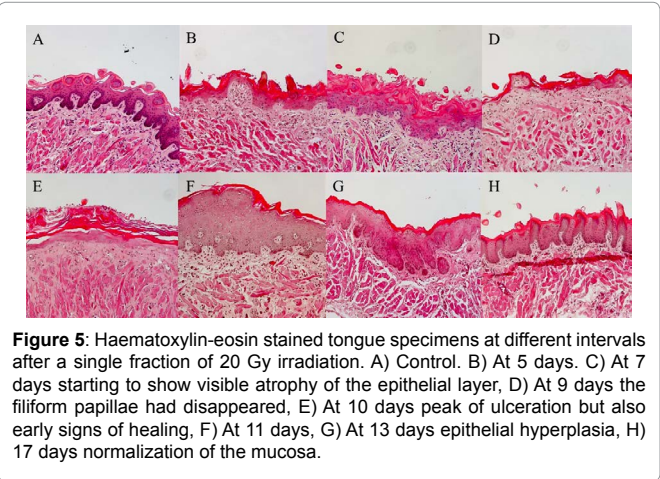
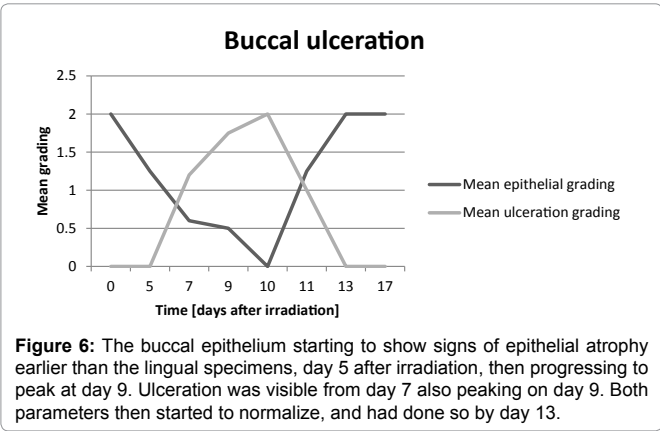
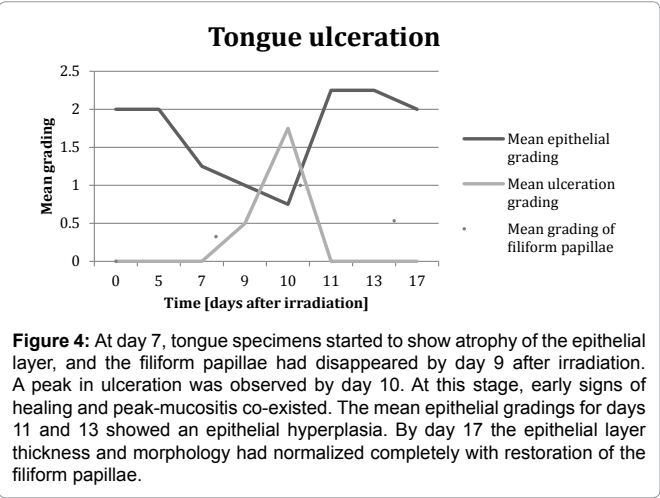
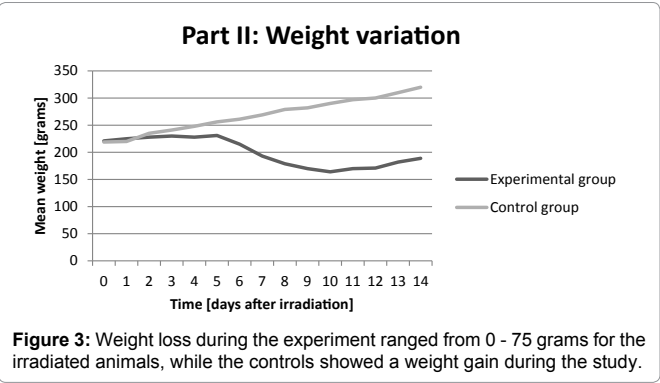
At this stage, early signs of healing, and peak-mucositis co-existed. The mean epithelial gradings for days 11 and 13 revealed epithelial hyperplasia, including an epithelial thickening exceeding that of the controls, a so-called over-shoot phenomenon [21-23]. By day 17 the epithelial layer thickness and morphology had normalized completely with restoration of the filiform papillae (Figures 3-5). The buccal epithelium started to show signs of epithelial atrophy earlier than the lingual specimens, day 5 after irradiation, then progressing to peak on day 9. The ulceration was visible from day 7, also peaking on day 9. Both parameters then started to normalize, and had done so by day

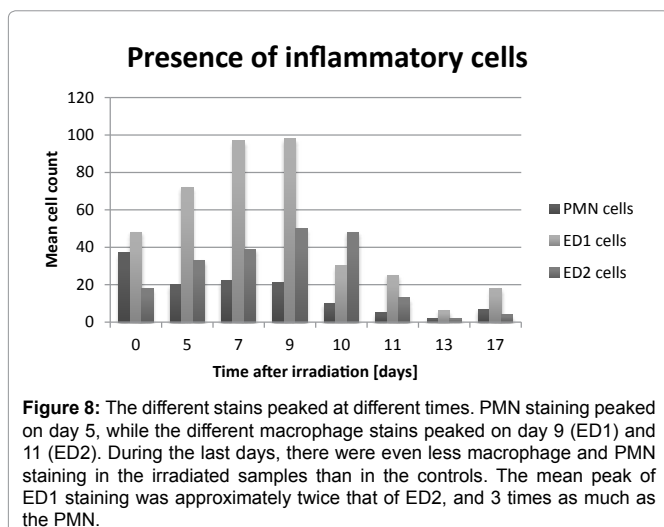
13, though not with such a clear so-called over-shoot phenomenon in the lingual histological sections (Figures 6 and 7).

Immunohistochemistry: Figure 7 shows the longitudinal pattern of immune cell invasion. The peak of PMN staining was on day 5, earlier during the acute phase than for the macrophage stains. The peaks for the different macrophage stains were day 9 (ED1) and 11 (ED2), respectively, and after the acute phase terminated. There were even less macrophage and PMN staining in the irradiated samples than in the controls. The mean peak of ED1 staining was approximately twice that of ED2, and 3-folds that of PMN (Figure 8).

Discussion

By using a high-energy linear accelerator, an experimental model for oral mucositis was developed in the Sprague-Dawley rat. A single irradiation dose of 20 Gy to the entire head region induced a reproducible OM leading to a significant weight loss. A time-dependent loss of epithelial cells and regeneration as well as recruitment of inflammatory cells in the oral mucosa during the development of OM was demonstrated. The dose used to induce OM is slightly lower than reported in some other studies [24]. This can be attributed to the larger target-volume in this study [25]. Previous experimental studies on radiation-induced OM have frequently been performed on mouse models[26-32], but due to the small size of the mouse it is technically difficult to produce a normative irradiation dose. The hamster OM model introduced by Stephen Sonis and colleagues revolutionized the research of chemotherapy-induced mucositis, but the mucositis





model induced by irradiating the everted hamsters's buccal pouch [33] is a more invasive approach than the one used here. Radiation-induced glossitis in Sprague-Dawley rats has been studied earlier, most likely because it is the most accessible sub-site in which to study OM [34-36], but in agreement with other studies we found that radiation-induced injuries of the lingual and buccal mucosa are not identical [34,37]. This variability in OM between different subsites in the oral cavity has not previously been fully elucidated. For instance by pulling the tongue out of the mouth, using forceps, as in earlier studies on rat [34], one risks injuring the tongue in ways other than just irradiation. This might partly explain the longer duration of the mucositis. Li et al. reported 35 days to complete healing, compared with day 17 in lingual specimens in the present study. However, they used X-ray radiation and a larger dose of 30 Gy compared with our dose of 20 Gy. The use of a conventional high-energy linear accelerator (Varian Clinac 2300 C/D) in this study instead of X-ray radiation or radioactive plaques also makes results easier to compare with the radiotherapy given in a clinical setting. The weight loss of the animals in this study correlates to the actual weight loss of patients undergoing radiotherapy for head and neck cancer [38,39], which is a serious side effect affecting the ability of the patient to tolerate the treatment. In the ethical guidelines for animal studies, weight loss is considered a humane endpoint, but has more and more been questioned as such since it is a late sign of the lack of well-being for the animal [40]. In the lingual histological sections, a hyperplasia of the epithelium was observed in the aftermath of OM, these-called over-shoot phenomenon, also known as epithelial keratosis [38]. In the buccal epithelium signs of epithelial atrophy started to show earlier than in the lingual specimens, and did not show epithelial hyperplasia during recovery. The ulceration in the buccal mucosa was more severe and persisted longer than in the tongue, and since it most probably corresponds to the ulcerative phase of human mucositis it emphasizes the difference between subsites within the oral cavity. A number of molecular differences in the epithelium may occur between individuals, which might explain why some individuals develop more severe OM than others, even if treatment regimes are similar. The individual variability remains to be elucidated and our animal model could be of further use in examining the differences between individuals at the same irradiation-dose. Earlier histological investigation of OM in humans has not revealed an increase in granulocytes or other leukocytes, except for the M2 subtype of macrophages [41,42], which seems to be the most prevalent

inflammatory cell in OM. This has led to the conclusion in some publications that OM might not even be an inflammatory disorder [9]. However, in this experimental rat model, we can see a marked increase in both granulocytes and M1 macrophages preceding the increase in M2 macrophages. Immuno histochemistry of the lingual histological sections showed that polymorphonuclear cells are involved in the induction of immune cell response. An early phase, 5 days after irradiation, with a peak of PMN cells, was followed by a later phase with an expression of macrophages, both M1 and M2, which peaked on day 10. The different peaks of the number of inflammatory cells in the irradiated tissue, as well as the subsequent low numbers of PMN cells after the acute phase, pinpoint that inflammatory cells might have an impact on the development of mucositis. These findings indicate that inflammation elicited by irradiation is both part of the induction as well as a down-regulatory repair phase of OM. The precise role of PMN cells in irradiation-induced OM is still unknown. PMN cells are generally considered injurious in mucosal inflammation. But in radiation-induced colitis in mice, increased PMN chemo attractant expression and subsequently higher PMN cell numbers were linked to less tissue damage in mast cells-deficient mice [43]. Studies in SMAD3 knockout mice have reported a potential tissue protective role of acute PMN cell influx in irradiation-induced tissue injury [44]. RT works by directly damaging cellular DNA, which results in cellular apoptosis and also inhibits normal cell regeneration. The apoptosis-generated debris causes inflammation via numerous biomolecular cascades, including Toll-like receptor signalling and NF κ B activation, which in turn up-regulate more than 200 genes where the gene products are involved in tissue toxicity during radiation-induced OM [45]. Clearance of these pro-inflammatory signals by M2 macrophages helps to down-regulate the immune response, thus limiting the damage [46]. Poor clearance by macrophages has been shown to contribute to a number of both acute and chronic disease states [47]. The M1 polarization of macrophages, which is known to develop by stimulation of interferon gamma and lipopolysaccharide, applies proinflammatory and/or microbicidal functions via the Th-1 cell-mediated immune response [48]. However, excessive or prolonged M1 polarization leads to tissue injury and contributes to pathogenesis [48]. On the other hand, M2 macrophages observed at late in the acute phase of mucositis have immunosuppressive and tissue-repairing functions and play a critical role in the resolution of harmful inflammation by producing anti-inflammatory mediators [48]. Long-term effects of radiation, such as mucosal atrophy and osteoradionecrosis, are reportedly related to the severity of the acute radiation response [49]. It is therefore of great importance that further research is conducted in this field in order to extend our understanding of the mechanisms underlying RT-induced OM and in order to develop new forms of prevention and treatment. Identification of therapeutic targets and the development of new treatment forms require well-validated and clinically relevant animal models. To sum up: a novel model of OM in the Sprague-Dawley rat using an irradiation-dose of 20 Gy has been developed that permits quantitation of the degree of injury and the influx of various immunological cells over time in irradiated tissue. The epithelial reaction to radiation in rat was shown to vary between different subsites of the oral mucosa. In rat tongue there was an initial increase in PMN cells, followed by a much larger increase in macrophages, where the wound-healing M2 macrophages peaked slightly later than the general macrophage marker. Our model of OM may prove useful for the evaluation of irradiation-induced mucositis in oesophagus and larynx as well as for further elucidating the pathogenesis of mucositis associated with radiation treatment of head and neck cancer, and also to evaluate new forms of therapy.

Acknowledgements

We gratefully thank Cathrine Johansson for skilful technical assistance. This study received financial support from Umeå University, Uppsala University and the Acta Otolaryngologica Foundation.

Declaration of interest

The authors report absence of any conflict of interest. The authors alone are responsible for the content and writing of the paper.

References

1. Ferlay J, Shin HR, Bray F, Forman D, Mathers C, et al. (2010) Estimates of worldwide burden of cancer in 2008: GLOBOCAN 2008. *Int J Cancer* 127: 2893-2917.
2. Vissink A, Jansma J, Spijkervet FK, Burlage FR, Coppes RP (2003) Oral sequelae of head and neck radiotherapy. *Crit Rev Oral Biol Med* 14: 199-212.
3. Rezvani M, Alcock CJ, Fowler JF, Haybittle JL, Hopewell JW, et al. (1991) Normal tissue reactions in the British Institute of Radiology Study of 3 fractions per week versus 5 fractions per week in the treatment of carcinoma of the laryngo-pharynx by radiotherapy. *Br J Radiol* 64: 1122-1133.
4. Vera-Llonch M, Oster G, Hagiwara M, Sonis S (2006) Oral mucositis in patients undergoing radiation treatment for head and neck carcinoma. *Cancer* 106: 329-336.
5. Rubenstein EB, Peterson DE, Schubert M, Keefe D, McGuire D, et al. (2004) Clinical practice guidelines for the prevention and treatment of cancer therapy-induced oral and gastrointestinal mucositis. *Cancer* 100: 2026-2046.
6. Trotti A, Bellm LA, Epstein JB, Frame D, Fuchs HJ, et al. (2003) Mucositis incidence, severity and associated outcomes in patients with head and neck cancer receiving radiotherapy with or without chemotherapy: a systematic literature review. *Radiother Oncol* 66: p. 253-262.
7. Peterson DE (1999) Research advances in oral mucositis. *Curr Opin Oncol* 11: 261-266.
8. Plevová P (1999) Prevention and treatment of chemotherapy-and radiotherapy-induced oral mucositis: a review. *Oral Oncol* 35: 453-470.
9. Sonis ST (2004) The pathobiology of mucositis. *Nat Rev Cancer* 4: 277-284.
10. Handschel J, Prott FJ, Sunderkötter C, Metze D, Meyer U, et al. (1999) Irradiation induces increase of adhesion molecules and accumulation of beta2-integrin-expressing cells in humans. *Int J Radiat Oncol Biol Phys* 45: 475-481.
11. Bowen JM, Gibson RJ, Keefe DM (2011) Animal models of mucositis: implications for therapy. *J Support Oncol* 9: 161-168.
12. Dörr W, Spekl K, Martin M (2002) Radiation-induced oral mucositis in mice: strain differences. *Cell Prolif* 35 Suppl 1: 60-67.
13. Sonis ST, Tracey C, Shklar G, Jensen J, Florine D (1990) An animal model for mucositis induced by cancer chemotherapy. *Oral Surg Oral Med Oral Pathol* 69: 437-443.
14. Ara G, Watkins BA, Zhong H, Hawthorne TR, Karkaria CE, et al. (2008) Velafermin (rhFGF-20) reduces the severity and duration of hamster cheek pouch mucositis induced by fractionated radiation. *Int J Radiat Biol* 84: 401-412.
15. Murphy CK, Fey EG, Watkins BA, Wong V, Rothstein D, et al. (2008) Efficacy of superoxide dismutase mimetic M40403 in attenuating radiation-induced oral mucositis in hamsters. *Clin Cancer Res* 14: 4292-4297.
16. Schmidberger H, Rave-Fränk M, Kim S, Hille A, Pradier O, et al. (2003) Radiation-induced mucositis and neutrophil granulocytes in oral mucosa. *Strahlenther Onkol* 179: 667-672.
17. Takahashi K, Naito M, Takeya M (1996) Development and heterogeneity of macrophages and their related cells through their differentiation pathways. *Pathol Int* 46: 473-485.
18. Mosser DM, Edwards JP (2008) Exploring the full spectrum of macrophage activation. *Nat Rev Immunol* 8: 958-969.
19. Gabriels K, Hoving S, Gijbels MJ, Pol JF, te Poele JA, Biessen EA, et al. (2014) Irradiation of existing atherosclerotic lesions increased inflammation by favoring pro-inflammatory macrophages. *Radiother Oncol* 110: p. 455-460.
20. Hamilton S, Yoo J, Hammond A, Read N, Venkatesan V, et al. (2008) Microvascular changes in radiation-induced oral mucositis. *J Otolaryngol Head Neck Surg* 37: 730-737.
21. Segel LA, Goldbeter A, Devreotes PN, Knox BE (1986) A mechanism for exact sensory adaptation based on receptor modification. *J Theor Biol* 120: 151-179.
22. Knox BE, Devreotes PN, Goldbeter A, Segel LA (1986) A molecular mechanism for sensory adaptation based on ligand-induced receptor modification. *Proc Natl Acad Sci U S A* 83: 2345-2349.
23. Behar M, Hao N, Dohlman HG, Elston TC (2007) Mathematical and computational analysis of adaptation via feedback inhibition in signal transduction pathways. *Biophys J* 93: 806-821.
24. Lee SW, Jung KI, Kim YW, Jung HD, Kim HS, et al. (2007) Effect of epidermal growth factor against radiotherapy-induced oral mucositis in rats. *Int J Radiat Oncol Biol Phys* 67: 1172-1178.
25. Ottosson S, Söderström K, Kjellén E, Nilsson P, Zackrisson B, Laurell G (2014) Weight and body mass index in relation to irradiated volume and to overall survival in patients with oropharyngeal cancer: a retrospective cohort study. *Radiat Oncol* 9: p. 160.
26. Parkins CS, Fowler JF, Yu S (1983) A murine model of lip epidermal/mucosal reactions to X-irradiation. *Radiother Oncol* 1: 159-165.
27. Xu FX, van der Schueren E, Ang KK (1984) Acute reactions of the lip mucosa of mice to fractionated irradiations. *Radiother Oncol* 1: 369-374.
28. Fehrmann A, Dörr W (2005) Effect of EGFR-inhibition on the radiation response of oral mucosa: experimental studies in mouse tongue epithelium. *Int J Radiat Biol* 81: 437-443.
29. Dörr W, Hirler E, Hönig M (1993) Response of mouse tongue epithelium to single doses of bleomycin and radiation. *Radiother Oncol* 27: 237-244.
30. Moses R, Kummermehr J (1986) Radiation response of the mouse tongue epithelium. *Br J Cancer Suppl* 7: 12-15.
31. Dörr W, Kummermehr J (1990) Accelerated repopulation of mouse tongue epithelium during fractionated irradiations or following single doses. *Radiother Oncol* 17: p. 249-259.
32. Dörr W, Kummermehr J (1991) Proliferation kinetics of mouse tongue epithelium under normal conditions and following single dose irradiation. *Virchows Arch B Cell Pathol Incl Mol Pathol* 60: p. 287-294.
33. Murray LA, Kramer MS, Hesson DP, Watkins BA, Fey EG, et al. (2010) Serum amyloid P ameliorates radiation-induced oral mucositis and fibrosis. *Fibrogenesis Tissue Repair* 3: 11.
34. Li CY, Chen XH, Tao XA, Xia J, Cheng B (2011) The development and inflammatory features of radiotherapy-induced glossitis in rats. *Med Oral Patol Oral Cir Bucal* 16: e348-353.
35. Li CY, Hong Y, Tao XA, Xia J, Cheng B (2011) The correlation between the severity of radiotherapy-induced glossitis and endothelial cell injury in local tissues in a rat model. *Med Oral Patol Oral Cir Bucal* 16: e711-715.
36. Nakashima T, Uematsu N, Shibamori M, Sakurai K, Ishida T (2013) Establishment of an X-ray irradiation-induced glossitis model in rats: biphasic elevation of proinflammatory cytokines and chemokines. *J Pharmacol Exp Ther* 347: 660-668.
37. Rezvani M, Ross GA (2004) Modification of radiation-induced acute oral mucositis in the rat. *Int J Radiat Biol* 80: 177-182.
38. Ottosson S, Söderström K, Kjellén E, Nilsson P, Zackrisson B, et al. (2014) Weight and body mass index in relation to irradiated volume and to overall survival in patients with oropharyngeal cancer: a retrospective cohort study. *Radiat Oncol* 9: 160.
39. Brown T, Banks M, Hughes BG, et al. (2015) New radiotherapy techniques do not reduce the need for nutrition intervention in patients with head and neck cancer. *Eur J Clin Nutr* 69: 1119-1124.
40. Nuno HF, Margarida CN, Anna SIO, (2012) How "humane" is your endpoint? Refining the science-driven approach for termination of animal studies of chronic infection. *PLoS Pathog* 8: p. e1002399.
41. Bonan PR, Kaminagakura E, Pires FR, Vargas PA, de Almeida OP (2007) Histomorphometry and immunohistochemical features of grade I (WHO) oral radiomucositis. *Oral Dis* 13: 170-176.

42. Handschel J, Sunderkötter C, Prott FJ, Meyer U, Kruse-Lösler B, et al. (2001) Increase of RM3/1-positive macrophages in radiation-induced oral mucositis. *J Pathol* 193: 242-247.
43. Blirando K, Milliat F, Martelly I, Sabourin JC, Benderitter M, et al. (2011) Mast cells are an essential component of human radiation proctitis and contribute to experimental colorectal damage in mice. *Am J Pathol* 178: 640-651.
44. Flanders KC, Benzamin MH, Arany P, Stuelten C, Mamura M, et al. (2008) Absence of Smad3 induces neutrophil migration after cutaneous irradiation: possible contribution to subsequent radioprotection. *Am J Pathol* 173: 68-76.
45. Sonis ST (2002) The biologic role for nuclear factor-kappaB in disease and its potential involvement in mucosal injury associated with anti-neoplastic therapy. *Crit Rev Oral Biol Med* 13: 380-389.
46. Gregory CD, Devitt A (2004) The macrophage and the apoptotic cell: an innate immune interaction viewed simplistically? *Immunology* 113: 1-14.
47. Weigert A, Jennewein C, Brüne B (2009) The liaison between apoptotic cells and macrophages—the end programs the beginning. *Biol Chem* 390: 379-390.
48. Murray PJ, Wynn TA (2011) Protective and pathogenic functions of macrophage subsets. *Nat Rev Immunol* 11: 723-737.
49. Dörr W, Hendry JH (2001) Consequential late effects in normal tissues. *Radiother Oncol* 61: 223-231.

Author Affiliations

[Top](#)

¹Department of Surgical Sciences, ORL section, Uppsala University, Uppsala, Sweden

²Department of Clinical Sciences, Umeå University, Umeå, Sweden

³Department of Radiation Sciences, Radiophysics, Umeå University, Umeå, Sweden

⁴Department of Radiation Sciences, Oncology, Umeå University, Umeå, Sweden

⁵Department of Medical Biosciences, Umeå University, Umeå, Sweden

Submit your next manuscript and get advantages of SciTechnol submissions

- ❖ 50 Journals
- ❖ 21 Day rapid review process
- ❖ 1000 Editorial team
- ❖ 2 Million readers
- ❖ Publication immediately after acceptance
- ❖ Quality and quick editorial, review processing

Submit your next manuscript at • www.scitechnol.com/submission