



## Research Article

# Assessment of Endovascular Coiling versus Neurosurgical Clipping of Intracranial Aneurysms in Patients with Subarachnoid Hemorrhage

Mujahid Alizada<sup>1\*</sup>, Yang Fuyi<sup>1</sup>, Ngwayi James Reeves Mbori<sup>2</sup> and Shahid Alam<sup>3</sup>

### Abstract

**Objective:** To evaluate the outcome and length of hospitalization of Endovascular Coiling and Surgical Clipping methods in the treatment of intracranial aneurysms in patients with subarachnoid hemorrhage.

**Method:** A total of 200 (n=200) intracranial aneurysms patients with subarachnoid hemorrhage were studied in a retrospective study. The patients were randomly divided into two groups, Group A (n=100) who were treated with neurosurgical clipping and Group B (n=100) who were treated with endovascular coiling. Both groups were followed up during their stay in the hospital and 6 months postoperatively, their clinical outcome was evaluated based on Modified Rankin Scale scoring system six months after operation.

**Results:** The length of hospitalization for Group A patients was median  $\pm$  IQR (18  $\pm$  14) days and for Group B patients was median  $\pm$  IQR (14  $\pm$  13).

The outcome for Group A patients, 61(61%) achieved good clinical outcome, 31 (31%) dependency and 8 (8%) death. Group B patients, 73 (73%) achieved good short term clinical outcome, 22 (22%) dependency and 5 (5%) death after six months follow up.

**Conclusion:** Our study shows that endovascular coiling treatment of ruptured intracranial aneurysms has short length of hospitalization and better clinical outcome with a relatively low mortality, low dependency and higher good outcome rates than surgical clipping in patients feasible for either method.

### Keywords

Endovascular coiling; Neurosurgical clipping; Intracranial aneurysm; Subarachnoid hemorrhage; Clinical outcome

## Introduction

Cerebral aneurysm is a cerebrovascular disorder in which weakness in the wall of cerebral artery or vein results in a localized dilation or ballooning of blood vessel. Most unruptured aneurysms remain undetectable. A minority of aneurysms are detected when

they cause symptoms either by mass effect or when they rupture causing subarachnoid hemorrhage (SAH) [1]. Intracranial aneurysm is not an uncommon entity, with a prevalence of 0.5% to 6% in adults in general population [2]. The rate of (SAH) due to rupture of intracranial aneurysms is 6-8 per 100 000 cases in western countries and 7-11 per 100 000 cases in Korea [3-8]. Patients with ruptured aneurysms present with severe headache, coma or with severe neurologic compromise. More than 10% of patients with ruptured intracranial aneurysms die before reaching the hospital, about 50% patients die within first month from progressive deterioration and 30% of survivors have moderate to severe disability [9-11]. The exact mechanism by which cerebral aneurysm develop are unknown. However a number of factors are believed to contribute to the formation of cerebral aneurysms. These include 1) hypertension (high blood pressure) 2) cigarette smoking 3) congenital (genetic) predisposition 4) injury or trauma to blood vessels 5) complications from some types of blood infections. An unruptured aneurysm is one whose sac has not previously leaked. An aneurysm ruptures when a hole develops in the sac of aneurysm. There are three treatment options for people with diagnosis of cerebral aneurysm. 1) medical (non-surgical therapy) which is basically smoking cessation and blood pressure control with antihypertensive. 2) Surgical therapy or clipping 3) endovascular therapy or coiling [12]. Intracranial aneurysm is not an uncommon entity, with a prevalence of 0.5%-6% in adults in general population. They are multiple in 10-30% cases [9].

Making the decision of whether to treat or not an aneurysm is a complex issue and these factors are favoring treatment for incidental aneurysm. 1) size >7 mm 2) posterior circulation including PcoA 3) presence of daughter sac (representing a weak point in the aneurysm) 4) long life expectancy (young age) 5) history of SAH in the past 6) family history of SAH 7) patient with ADPKD [13].

In the past, neurosurgical clipping of the aneurysmal neck was the only effective method to prevent re-bleeding of aneurysm. In 1990 a detachable platinum coil device the Guglielmi detachable coil was first introduced in clinical practice since that time, coiling has gained worldwide acceptance as an alternative treatment [14]. Since the introduction of GDCs into clinical practice multiple clinical trials have been published comparing functional outcome at 1 year after coil embolization versus surgical clip ligation for ruptured intracranial aneurysms. These published trials show that the odds of poor outcome are higher after surgical treatment than after endovascular treatment, despite higher early risk of re-bleeding from the target aneurysm after coil embolization. Furthermore risks of seizures, delayed cerebral ischemia, ischemic lesions on MRI imaging and in hospital complications are lower after coil embolization than after surgical clip ligation [15-18].

## Methodology

A total of 200 (n=200) intracranial aneurysms patients with subarachnoid hemorrhage were studied in a retrospective study from January 2012 to January 2015 in our hospital. The patients were randomly divided into two groups, Group A (n=100) who were treated with neurosurgical clipping and Group B (n=100) who were treated with endovascular coiling. Both groups pretreatment clinical status were recorded and both groups were followed up during their

\*Corresponding author: Mujahid Alizada, Department of Neurosurgery, The 1st affiliated Hospital of Jiamusi University, China, Tel: 0086 15504542749; E-mail: alizadamujahid@gmail.com

Received: January 11, 2016 Accepted: June 14, 2016 Published: January 20, 2017

stay in the hospital and six months postoperatively. Their clinical outcome was evaluated based on Modified Rankin Scale scoring system after six months of operation. All the patients were stratified according to the Hunt and Hess (H&H) scale and Glasgow Coma Scale (GCS) [19,20]. Standard CT, CTA and DSA were performed for participants and location of bleeding was determined. All the patients or their attendants provided written informed consent before treatment with either method. Modified Rankin Score was used to determine clinical outcome [2]. ●score 0-2: Good outcome ●score 3-5: Dependency (cannot attend own bodily needs and carry out daily activities without assistance. ●score 6: Death

**Statistical analysis**

IBM SPSS Statistics v20-32bit software was used to evaluate the statistical significance between the outcomes of two methods. The p values for good outcomes, dependency and death are (0.30, 0.22 and 0.41) where α=0.05 with 95% confidence interval. Even though the difference is not statistically significant but it is definitely clinically significant.

**Criteria of inclusion**

The patients observed to have Subarachnoid Hemorrhage (SAH) due to an intracranial aneurysm which was ruptured and there diagnosis was confirmed with CT, CTA and specially DSA which is the golden standard and provided informed consent by themselves or their attendant where chosen as candidates for the procedure.

**Criteria of exclusion**

Withdrawal of consent, patients having serious ECG results of structural and/or functional variations and patients with severe respiratory compromised conditions.

**Results**

200 patients of intracranial aneurysm with subarachnoid hemorrhage (SAH) were treated, 100 patents with endovascular coiling and 100 patients with surgical clipping. Patients were evaluated preoperatively with Hunt and Hess (H&H) and Glasgow Coma Scale (GCS). The length of hospitalization for endovascular coiling was median ± IQR (14 ± 13) days and for surgical clipping was medina ± IQR (18 ± 14) days. The number of female was more than male in both groups, in endovascular coiling 37 (37%) male and 63 (63%) female which makes a ratio F:M (1.7:1) and in surgical clipping 44 (44%) male and 56 (56%) female which makes a ratio of about F:M (1.3:1). Table 1 summarizes baseline characteristics of the participants (n=200) (Figure 1).

Modified Rankin Score [9] was used to determine clinical outcome and based on mRS (modified Rankin score) the clinical outcome for endovascular coiling was, 73 (73%) had good outcome, 22 (22%) dependency and 5 (5%) death. Of 100 (n=100) patients treated with surgical clipping, 61 (61%) had good outcome, 31 (31%) dependency and 8 (8%) death. Table 2 summarizes the clinical outcome of all the participants.

**Discussion**

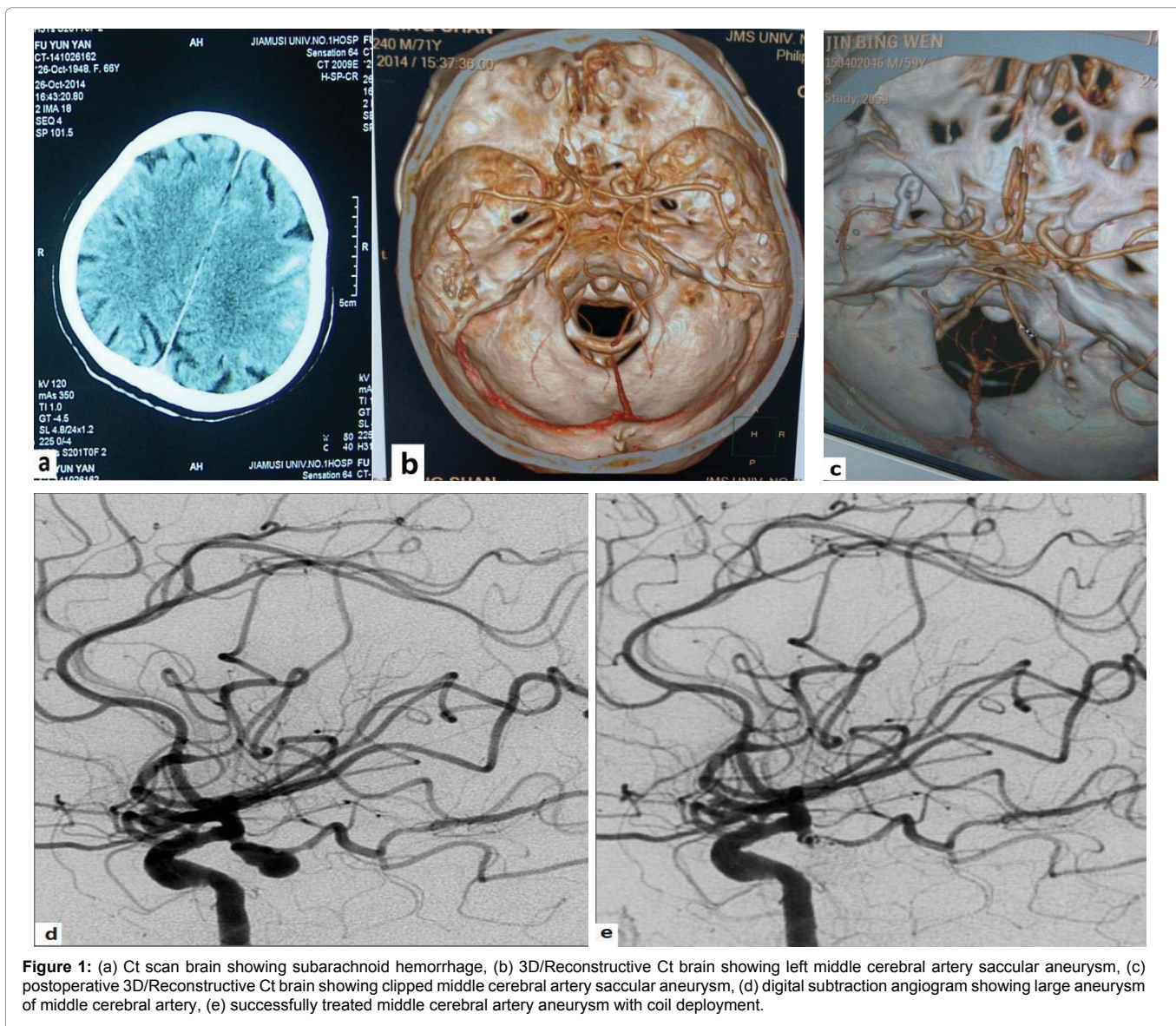
Even though clipping was regarded as golden standard for ruptured intracranial aneurysms, a second new method of endovascular coiling has been increasingly used for treatment of intracranial aneurysm from the time this method was invented which was 1990. Timing of surgical measures applying remains a controversial issue even though different timing frames have been chosen with time. Previously it was thought that surgery should be done 10 days post ictus later on it was decided to have immediate or early surgery at

**Table 1:** Baseline characteristics of the participants (n=200), H&H: Hunt and Hess, GCS: Glasgow Coma Scale.

Method	H&H		GCS		Sex		Age(y), mean ± SD	Total	Length of Hospitalization(d), median ± IQR
	Grade	No.	score	No.	M	F			
Clipping	I	3	3-8	16	44	56	52 ± 10	100	18±14
	II	34		37					
	III	20							
	IV	36							
	V	7	9-12	47					
			13-15						
Method	H&H		GCS		Sex		Age(y), mean ± SD	Total	Length of Hospitalization(d), median ± IQR
	Grade	No.	score	No.	M	F			
Coiling	I	9	3-8	19	37	63	55±10	100	14±13
	II	41		28					
	III	15							
	IV	29							
	V	6	9-12	53					
			13-15						

**Table 2:** Clinical outcome of the participants (n=200) based on mRS. mRS: modified Rankin Score

Method	Participants(n)	mRS		Clinical Outcome
		Score	No.	
Clipping	100	0-2	61	Good
		3-5	31	Dependency
		6	8	Death
		Score		(short term)
Coiling	100	0-2	73	Good
		3-5	22	Dependency
		6	5	Death
		Score		(short term)



**Figure 1:** (a) Ct scan brain showing subarachnoid hemorrhage, (b) 3D/Reconstructive Ct brain showing left middle cerebral artery saccular aneurysm, (c) postoperative 3D/Reconstructive Ct brain showing clipped middle cerebral artery saccular aneurysm, (d) digital subtraction angiogram showing large aneurysm of middle cerebral artery, (e) successfully treated middle cerebral artery aneurysm with coil deployment.

least for those patients who have good clinical condition and recently it is preferred to have early surgery for those who are even not in good clinical condition despite no accurate study has shown that early surgery leads to an overall better clinical outcome than that of late [21]. The probability of rupture is related to the size of aneurysm. Aneurysm rupture is a devastating event. Approximately 15 percent of patients die prior to reaching the hospital and of those who make it on time only one third will have good result after treatment. Therefore salvage treatment is not effective [13]. Aneurysms are of several types. Saccular (berry) aneurysm (congenital aneurysm) is the most common type of intracranial aneurysm. Other rare types of aneurysms include atherosclerotic (fusiform, mostly of the basilar artery), mycotic, traumatic and dissecting aneurysms. These latter three like saccular aneurysms are most often found in the anterior circulation. They usually present with cerebral infection rather than subarachnoid hemorrhage [22].

Human decision making in the presence of uncertainty is a complex, poorly understood process. Yet humans are condemned to

choice and action [23,24]. In the univariate analysis, SAH (ruptured cerebral aneurysm) was significantly associated with longer hospitalizations, higher hospital costs and higher hospital collections regardless of the treatment methods. Patients with SAH were associated with a 6.3 times longer median length of hospitalization 3.2 times higher median hospital costs 1.6 times higher median hospital collections and 0.8 times lower median surgeon collections compared with patients without SAH [25]. The selection of neuroradiological techniques requires the careful consideration of the various available neurosurgical techniques. Just as the selection of neurosurgical treatment requires an analysis of the endovascular alternatives [26]. In the majority of published studies and meta-analysis the risk of death and morbidity after clipping rated for few to over a dozen percent [27,28].

In this study, the length of hospitalization and short term clinical outcome of endovascular coiling versus surgical clipping are evaluated in a large sample of Chinese patients of Third River District of Jiamusi city treated in our hospital.



## Conclusion

Results of endovascular coiling treatment of ruptured intracranial aneurysms showed short length of hospitalization and better clinical outcome with a relatively low mortality, low dependency and higher good outcome rates than surgical clipping in patient feasible for either method in our hospital.

## References

1. Mousavi M, Hairchian MH, Morteza A, Khalilzadeh O, Tafakhori A, et al. (2012) The prospective profile of endovascular coiling of cerebral aneurysms: The impact of clinical presentation, procedural results, aneurysm ruptured and location 1: 489.
2. Schievink WI (1997) Intracranial aneurysms. *N Engl J Med* 336:28-40.
3. Choi SS, Jeon SJ (2010) Comprehension of two modalities: endovascular coiling and microsurgical clipping in treatment of intracranial aneurysms. *Neurointervention* 5:1-7
4. Zubair Tahir M, Enam SA, Pervez Ali R, Bhatti A, ul Haq T (2009) Cost-effectiveness of clipping vs. coiling of intracranial aneurysms after subarachnoid hemorrhage in a developing country—a prospective study. *Surg Neurol* 72: 355-360.
5. Natarajan SK, Sekhar LN, Ghodke B, Britz GW, Bhagawati D, et al. (2008) Outcomes of ruptured intracranial aneurysms treated by microsurgical clipping and endovascular coiling in a high volume center. *AJNR Am J Neuroradiol* 29: 753-759.
6. de Oliveira JG, Beck J, Ulrich C, Rathert J, Raabe A, et al. (2007) Comparison between clipping and coiling on the incidence of cerebral vasospasm after aneurysmal subarachnoid hemorrhage: a systematic review and meta-analysis. *Neurosurg Rev* 30: 22-30.
7. Im SH, Han MH, Kwon OK, Kwon BJ, Kim SH, et al. (2009) Endovascular coil embolization of 435 small asymptomatic unruptured intracranial aneurysms: procedural morbidity and patient outcome. *AJNR Am J Neuroradiol* 30: 79-84.
8. Molyneux A, Kerr R, Stratton I, Sandercock P, Clarke M, et al. (2002) International Subarachnoid Aneurysm Trial (ISAT) of neurosurgical clipping versus endovascular coiling in 2143 patients with ruptured intracranial aneurysms: a randomised trial. *Lancet* 360: 1267-1274.
9. Hamid RS, Haq T, Chishti I, Azeemuddin M, Sajjad Z, Salam B (2010) Treatment of intracranial aneurysms using detachable coils: Initial results at a University Hospital in Pakistan. *J Pak Med Assoc* 60: 638-641.
10. Wijdicks EF, Kallmes DF, Manno EM, Fulgham JR, Piepgras DG (2005) Subarachnoid haemorrhage: neurointensive care and aneurysm repair. *Mayo Clin Proc* 80: 550-559.
11. Johnston SC, Selvin S, Gress DR (1998) The burden, trends and demographics of mortality from subarachnoid haemorrhage. *Neurology* 50: 1413-1418.
12. Soni D (2003) Treatment options for cerebral aneurysms: medical therapy, surgical clipping and endovascular coiling. *American association of neurological surgeons/congress of neurological surgeons* 114:1-3.
13. Fan YW, Lui WM (2011) Management of unruptured intracranial cerebral aneurysms. *Medical Bulletin* 16:6-8.
14. Li H, Pan R, Wang H, Rong X, Yin Z, et al. (2013) Clipping versus coiling for ruptured intracranial aneurysms: a systemic review and meta-analysis. *Stroke* 44: 29-37.
15. Lanzino G, Murad MH, dUrso PI, Rabinstein A (2013) A coil embolization versus clipping for ruptured intracranial aneurysms: A meta-analysis of prospective controlled published studies. *AJNR Am J Neuroradiol* 1-5.
16. Molyneux AJ, Kerr RS, Yu LM, Clarke M, Sneade M et al. (2005) International Subarachnoid Aneurysm Trial (ISAT) of neurosurgical clipping versus endovascular coiling in 2143 patients with ruptured intracranial aneurysms: a randomised comparison of effects on survival, dependency, seizures, rebleeding, subgroups, and aneurysm occlusion. *Lancet* 366: 809-817.
17. Dorhout Mees SM, Kerr RS, Rinkel GJ, Algra A, Molyneux AJ (2011) Occurrence and impact of delayed cerebral ischemia after coiling and after clipping in the International Subarachnoid Aneurysm Trial (ISAT). *J Neurol* 259: 679-83.
18. Vergouwen MD, Fang J, Casaubon LK, Stamplecoski M, Robertson A (2011) Higher incidence of in-hospital complications in patients with clipped versus coiled ruptured intracranial aneurysms. *Stroke* 42: 3093-3098.
19. Nica DA, Rosca T, Dinca A, Stroi M, Renta M, et al. (2010) Multiple cerebral aneurysms of middle cerebral artery: case report. *Romanian Neurosurgery* 17: 449-455.
20. Lindsay KW, Bone I, Fuller G, Callander R, Gijin JV (2010) *Neurology and Neurosurgery Illustrated (5th Edition)* Elsevier, Netherlands.
21. J Lafuente, Maurice-Williams RS (2002) Ruptured intracranial aneurysms: the outcome of surgical treatment in experienced hands in the period prior to the advent of endovascular coiling. *J Neurol Neurosurg Psychiatry* 74: 1680-1684.
22. Frosch MP, Anthony DC, Girolami UD (2004) *The Central nervous system (8th Edtn)* Kumar V, Abbas AK, Fausto N, Robbins and Cotran Pathologic Basis of Disease 28:1366-1367.
23. Darsaut TE, Kotowski M, Raymond J (2012) How to choose clipping versus coiling in treating intracranial aneurysms. *Neurochirurgie* 58:61-75.
24. Platt ML, Huettel SA (2008) Risky business: the neuroeconomics of decisionmaking under uncertainty. *Nat Neurosci* 11: 398-403.
25. Hoh BL, Chi YY, Dermott MA, Lipori PJ, Lewis SB (2009) The effect of coiling versus clipping of ruptured and unruptured cerebral aneurysms on length of stay, hospital cost, hospital reimbursement and surgeon reimbursement at the university of Florida. *Neurosurgery* 64:614-621.
26. Kaku Y, Yamashita K, Kokuzawa J, Hatsuda N, Andoh T (2010) Treatment of ruptured cerebral aneurysms-Clip and coil, not clip versus coil. *Acta Neurochir Suppl* 107: 9-13.
27. Birski M, Walesa C, Gaca W, Paczkowski D, Birska J, et al. (2014) A clipping versus coiling for intracranial aneurysms. *Neurologia I neurochirurgia Polska* 48: 122-129.
28. Bohman L, Winn H, LeRoux P (2011) Surgical decision making for the treatment of intracranial aneurysms: Youmans neurological surgery. Winn HR, Philadelphia, Saunders 1: 3756-3771.

## Author Affiliations

Top

<sup>1</sup>Department of Neurosurgery, The 1st affiliated Hospital of Jiamusi University, China

<sup>2</sup>Department of Orthopedics -III, The 1st affiliated Hospital of Jiamusi University, China

<sup>3</sup>Department of Vascular Surgery, The 1st affiliated Hospital of Jiamusi University, China

### Submit your next manuscript and get advantages of SciTechnol submissions

- ❖ 80 Journals
- ❖ 21 Day rapid review process
- ❖ 3000 Editorial team
- ❖ 5 Million readers
- ❖ More than 5000 
- ❖ Quality and quick review processing through Editorial Manager System

Submit your next manuscript at • [www.scitechnol.com/submission](http://www.scitechnol.com/submission)