



Original Article

A SCITECHNOL JOURNAL

Developing Ideal Solution for Acute Wound Treatment by Regenerative Medicine

Sandeep Shrivastava^{1*}, Mahakalkar C², Tayde S¹, Moin Mehmood¹ and Gupta A¹

Abstract

People tend to get injured, leading to wounds with losses of multiple tissues including skin, subcutaneous tissue, tendons and bones. There effective management is a complex process, but the outcomes many a time remain unpredictable. The complications involve further tissue loss, infections and non healing ulcers leading to huge morbidity. Throughout the world large resources are spent, consuming billions of dollars, towards manage these wounds and lessen the morbidity. A simple therapy for effective wound management if evolved will transform this health problem and save lot of sufferings.

Method: The "Sandeep's Technique's for Assisted Regeneration of Skin" (STARS) is therapy for complete healing of wounds with Autologous self activated Platelet Rich Plasma (PRP), imparted as local subcutaneous infiltrate in the wound margin or underneath the necrotic Flap, on every 4th day, till complete regeneration takes place and wound heals. The wounds are dressed daily / alternate day with only moist saline. It is a prospective case series of 36 cases of acute wounds over limbs associated with problems such as compound fracture, amputations, infections, post surgical necrotising flaps treated with STARS, treated at Acharya Vinobha Bhawe Rural Hospital, J. N. Medical College, Wardha, INDIA.

Finding: The final outcome is complete / near complete healing of all the wounds without requiring any surgical or intense medical intervention.

Interpretation: This method of treatment assisted with Platelet rich plasma as regenerative medicine product is safe, easy, effective and efficient mode of wound management. It is simple innovation, which can be adopted universally as an ideal treatment for wounds, minimising the morbidity and preserving the resources across the globe.

Keywords

Acute wounds; Platelet rich plasma; Sandeep's technique for assisted regeneration of skin

Introduction

An Injury associated with open wounds in orthopaedics is a huge challenge. It is not uncommon to come across fractures associated with wounds such as grade III A, B compound fractures, de-gloving injuries, large lacerations, crush injuries etc. These wounds have tissue

losses and cannot undergo primary repair. Such wounds are managed initially by debridements, than intense local care including negative suction therapy & local application of antimicrobial solutions/ointments [1-3]. Further as they heal, a coverage is required through surgical reconstruction by Skin graft or Flap. During these treatments, intense medical management with antibiotics and analgesics is also needed. Despite all these active interventions, outcomes may be associated with complications such as donor site morbidity, infection and non healing ulcer. There is also emergence of antimicrobial resistance and risk of drug induced side effects including renal failures. It also involves undertaking the surgical and anaesthesia risk. Patients with old age, cardiac problems, uncontrolled diabetes etc; may fail to undergo adequate treatment due to such high risks. Such complex management needs Plastic reconstruction expert's care under higher health centres. It is not possible to give adequate care at primary or secondary care centres. It's estimated that care of such wounds in US exceeds 50 billion dollar per year, which is 10 times of WHO health care budget [4].

Aim and Objective

This study is undertaken to evaluate Platelet Rich Plasma (PRP); also known as Plasma rich in growth factors (PRGF) or Platelet concentrate (PC); assisted innovative technique - "Sandeep's technique for assisted regeneration of Skin" (STARS) as definitive management for healing of acute wounds in orthopaedic situations.

Study Design

It is a prospective interventional study of 35 patients treated by STARS. The consenting patients with acute wounds having tissue losses including exposed underlying structure such as bones & tendons; infection; fractures; post surgical necrosis of flaps are included. The Patients of bleeding dyscrasia disorders; Haematological disorders; with haemoglobin of less than 10 gm % and low platelet counts of less than 1.5 million were excluded from the study.

Preparation of PRP

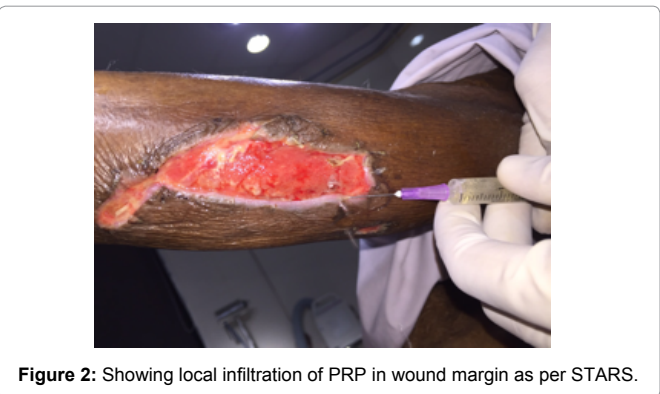
It is prepared by double spin method from 20 ml of autologous venous blood [5] (Figure 1). Transferring 5 ml each to 4 EDTA tubes. First spin is at a 1200 rpm, at room temperature, for 10 minutes. Subsequently transferring the upper buffy layer to a plain tubes and re-centrifuging it at 2000rpm for 10 minutes; which separates the PRP and WBC's, as PRP settles down and eventually extracting 2-4 ml of PRP and transferring it into a 5 ml syringe.

"STARS" technique

This is a refutative and conserving approach using Autologous PRP as definite therapy. It basically consists of local subcutaneous infiltration of PRP in the progressively healing wound margin. A dose of 0.2 ml at an approximate distance of 1cm; just like local anaesthesia, with 22 G needle, is infiltrated (Figure 2). Occlusive local dressing with moist saline is done on alternate days. The infiltration are repeated every 4th day, till a near complete healing is achieved (less than 1 cm at the widest / length or breadth). No further surgical debridements, reconstructions are done. No antibiotics are given. In infected wounds a pus culture is done, repeatedly at weekly interval till

*Corresponding author: Sandeep Shrivastava, Dean and Professor, Department of Orthopaedics, J. N. Medical College, Datta Meghe Institute of medical sciences (DU), Wardha, India, 442001, Tel: 917152287757; Fax: 917152287714; E-mail: drsandeepshrivastava@hotmail.com

Received: March 28, 2016 Accepted: May 04, 2016 Published: May 09, 2016



it became negative. Antibiotics and other drugs were given only for associated risk and co-morbidities.

Outcome measurement

Each wound was evaluated and photographed at the end of every session. The wound margins were drawn over a transparent sheet and subsequently measured with the help of chart paper, determining its area in square centimetres. The final outcomes in terms filling up with the granulation tissue, regeneration of skin through epithelization and its maturation is noted and analysed. The PRP induced healing is also analysed microscopically by taking a histopathological study of tissue from 3 wound (random selection) at the end of 3rd day, 21st day and at the end of treatment with matured coverage. The control of infection was evaluated with the help of serial pus-culture and sensitivity reports. Pain was measured with VAS score on a scale of 10. The drug history for every case was maintained.

Observations and Results

36 wounds in 34 Patients, with a follow-up of minimum 1 months are included in this study. The mean age is 34.7 years; with minimum of 4 years and maximum of 72 years. Of these 25 were male and 7 were female. The mean duration for wound was 8.2 days before the start of STARS therapy. The mean size of wound was 157.9.sq. cms, with minimum of 2 sq cms and maximum of 450 sq cms. The distribution of wound aetiology is as per Table 1.

Underlying critical structure exposed in the wounds were bone (tibia) in 3 cases, tendons in 24 cases, both in another 3 cases; and rest 6 were subcutaneous / muscle deep. In both cases of amputations the intention was to salvage adequate length of stump to give a bio-efficient prosthesis, and avoid amputation through the proximal fracture (Table 2). The postoperative flap was in one case was after primary repair of degloved injury and in other two, after wide excision of tumours. Of 36 wounds 11 were infected. The key organisms were MRSA, Staphylococcus Aureus and Pseudomonas Areuginosa. In

all such wounds swabs for pus culture and sensitivity were taken and repeated weekly, till they became negative. The STARS sessions and wound size correlated as per Table 3, with a mean wound size of 157.9 sq cms needing a mean of 9.6 sessions. Average healing time being 29.2 days. Final Outcome in terms of wound healing, infection control, pain control is as per Table 4. All the wounds healed completely with adequate infection control and none required intense pain management for wounds under consideration. After average follow-up of 32 days post healing, the wounds do not show any complications such as dehiscence or recurrences (Figures 3-6). No Patient had any systemic problems, rather most of them showed an improved in general conditions after two-three sessions and were pain free and mostly mobilised and rehabilitated as per the desired protocols.

Stages of PRP assisted healing and Histopathological correlation: The PRP induced wound healing through STARS typically undergoes 4 stages of healing. The 1st stage is suppression of unhealthy tissue including auto debridement. This lasts typically for 3-7 days. During this stage there is rush of macrophages to the site (Figure 7A) leading to intense phagocytosis auto-debridement. All necrotic and unhealthy tissue underwent auto debridement and showed speckles of angiogenesis over the exposed tendons or bones. In the next stage, filling up of the wound with healthy granulation tissue was noticed. This typically started after 3-4 sessions. It usually spread uniformly across the site, from periphery to central. Gradually the defect was filled up. In the IIIrd stage epithelization progressed from the wound margins towards centre. This is typically violate-purple coloured fragile tissue. It regenerated almost at the rate of 10 mm/week. The stages II and III infact overlapped each other, depending on the level-ling of defect. It is under this progressively healing wound margin that repeated dose of PRP was infiltrated, keeping the caution that it does not rupture and the leak due to needle insertion is minimised. Hence only 0.2 ml quantity was infiltrated per centimetre of length. Histopathologically this tissue typically is collagen led (Figure 7B) unlike the fibrotic tissue as in natural regeneration leading to scars. This

Table 1: Diagnosis and wound description.

S. No	Aiteology	Number	Status of infection
1	Acute post traumatic	24	6/24
2	Compound fracture	7	4/7
3	Post surgical flap nerosis	3	1/3
4	Post Amputation	2	0/2
Total		36	11

Table 2: Site distribution.

Site	No. of wounds
Upper limb	3
Low er limb	14
Sole	8
Hand	4
Injuries more than one site (including amputation)	7
Total	36

Table 3: Therapy details.

Size of wound sq cms	No. of Cases	Mean size	Mean No. of Session
10-50	24	18.7	7
50-100	0	-	-
100-150	1	105	9
>150	2	350	13
Total	36	157.9	9.6

Table 4: Final outcome.

Outcome	No. of Patients	Remark s
Complete healing	36 (100%)	All w ounds have healed to complete or near complete status.
Control of Infection	10/11 (90.9%)	<ul style="list-style-type: none">• In all 11 cases of infections, adequate infection control happened leading to normal w ound healing. There w as no delay in w ound healing as compared to other non-infected w ounds.• Averagely it took 4.2 Sessions for infection control to achieve (Pus Culture becoming negative)• 1 Patient needed I/V antibiotics for Co-morbid Pleural effusion, though his w ound healed w ell.
Control of pain	33/36 (91.6%)	<ul style="list-style-type: none">• 33 Patient didn't required active pain medication.• The average VAS score w as 2.1.• 3 had other severe other injuries for w hich I/V Analgesics w ere given for more than 3 days.
Residual Scarring	1 /36 (2.7%)	<ul style="list-style-type: none">• 35 had near normal skin except at centre w here a residual primary linear scar is seen.• 1patients discontinued the treatment in betw een and developed a scarring w ith mild claw ing of toes in one.
Dehiscence	0/36	None had any recurrence or dehiscence of w ound.

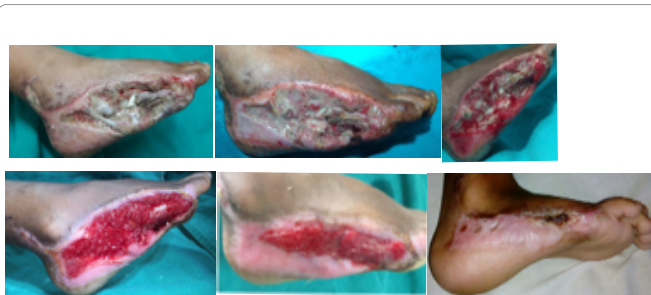

Figure 3: 4 years old boy with left foot injury after road traffic accident: Complete healing of wound with spontaneous clearance of all necrotic tissue and re-vascularisation of exposed necrotising bone.

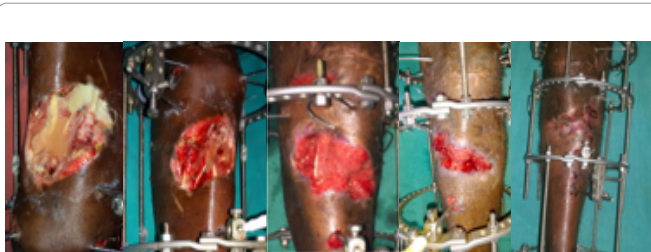


Figure 4: 32 years male with compound Grade IIIA infected fracture of right Tibia: Complete healing of wound with complete control of infection.

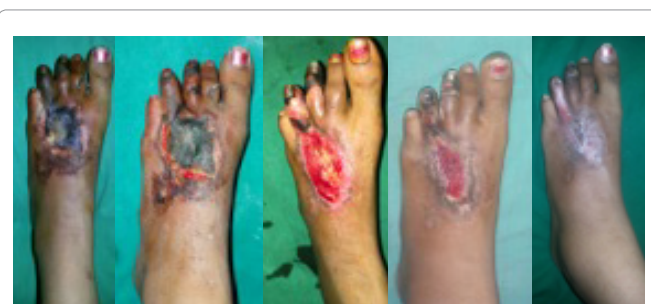

Figure 5: 20 year female after right foot injury with gangrenous changes in III and IV toes: Note the reversal of gangrenous changes in both the toes along with complete healing of wound.

difference is due to the fact that the PRP led healing is mediated by Interleukin4 against the natural scar which is led by Interleukin 6. The last stage is stage of maturation of the epithelized tissue. Again the last two stage overlaps; in about two-three weeks, the epithelized skin matures (Figure 7C). The defect is filled up with mature collagen

tissue and not fibrotic tissue. This is the major shift in the outcome of PRP assisted wound healing through assisted regeneration of skin. A qualitatively a better outcome is observed with matchable natural skin, including of the sole, which is as thick and of same colour as surrounding one. This is again not possible with any other modality of treatment developed till now. This the reason why no dehiscence and recurrence has been seen. In cases of necrotic flaps, the necrosis started getting limited (the wet gangrene turned into dry gangrene) and eventually only a portion of blackened eschar remained which spontaneously got removed, during subsequent dressings. The underneath tissue was salvaged. Perhaps this is for the first time such an observation is being reported in the history of medicine, where in with the help of PRP, salvage of necrotising tissue was also possible.

The characteristic difference between PRP assisted and natural healing is observed in Figure 8A,B,C, where in the case was undergoing STARS treatment regularly and a good quality skin was being regenerated , but she missed her regular STARS sessions and the last gap of 4 -6 sq.cm was filled in by cicatrized tissue (Figure 8D) leading to mild clawing of toes (though functionally not significant).

Discussion

The role of Platelet and PRP for wound healing is getting established along with standard wound management. This is based on the immense potentials of Platelets having alpha granules which on activation liberate many different growth factors including angiogenic, endothelial and endodermal. The PRP is being used now for wound healing as an adjunct to the wound management, specially as local application [5-10]. Though only few attempts have been made to infiltrate it in the wound as well [11-13].

Through the STARS, a therapy has been developed based on scientific observations. Though commercial gels/ solutions of platelet rich Plasma is available but they are costly and not easily accessible, especially in remote part of world as is ours. Fresh autologous venous blood is used in STARS with intention to make the therapy accessibility and safe. The patients own blood is used, hence risk is minimised for any transmission of diseases. Also low volume (20 ml) is used, ensuring no further risks are created due to blood loss. 20 ml usage is also based on the fact that in literature weekly 50 ml of blood has been safely used, in our therapy we need to do two times weekly, so a safe approach of low volume is taken. In addition, if we draw large volume Patient is affected psychologically and may withdraw from the study, hence 20 ml option is safest. Though in case of large wounds requiring more PRP volume, it has been adequately expanded to 50 ml with no risks observed, in such cases (4 /35).

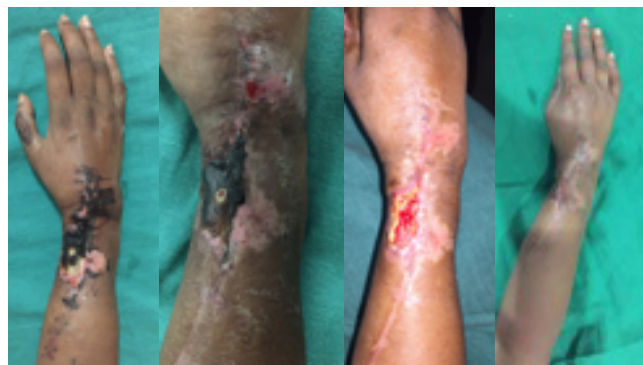

Figure 6: 32 years female showing salvage of post operative necrotising flap, over right wrist after GCT removal.

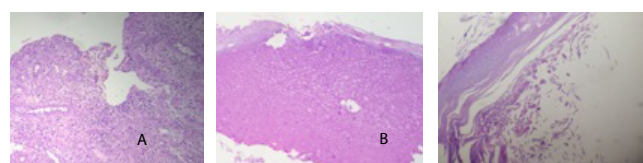


Figure 7 A,B,C: Microscopic picture of PRP assisted healing.

A- Showing macrophages and phagocytic activity at the site of injury; **B-** Progressive healing with laying of collagen tissue; **C-** Full thickness healing with collagen tissue.

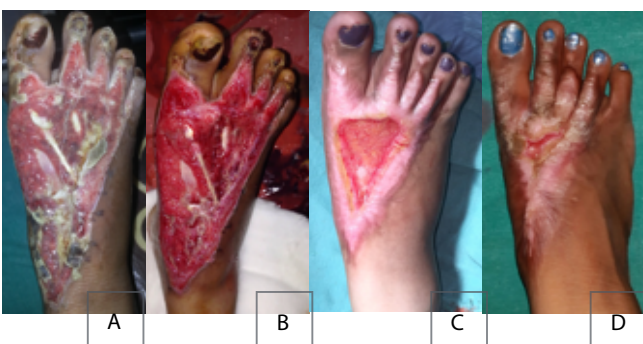

Figure 8 A,B,C: 20 year old female showing healing of wound of right foot after treatment with STARS and **D:** subsequent natural healing with residual scar formation.

Purposely the PRP preparation is kept at the simplest form so that it remains easily reproducible. There is still no definite evidence concentrate of platelet makes the plasma to be called as platelet rich plasma. The concentrate varies from 3-10 times. We have intermittently checked for the Platelet count and it had been always in the range of 3-8 times. The infiltration technique is developed from the hypothesis that the local application of PRP may not be sufficient as it may not be retained long enough locally to act adequately and as intended. The local application is just like another local dressing protocol and may just act by inducing the repair changes but not really affecting the local biology towards the regeneration. We took a major shift in this thinking and in STARS, the focus is on assisting regeneration of skin through platelet regeneration potentials. This is the single most significant shift in the use of PRP till now. Our aim is to promote the healing through regeneration of skin from the margins,

hence infiltration in the progressive wound margin is adopted. A low dose of 0.2 ml to 0.5 ml/ cm ensures that this precarious epithelized tissue maintains its integrity.

In a study on bacterial growth in PRP, we found that PRP being blood product promotes the bacterial growth, per se. Hence its assumed that it's the PRP induced local biological changes (High Macrophage activity and pH change to less than 7) which controls infection.

The PRP application dose is repeated in most of referred studies on 7-10 days, based on assumption that the platelet life is about 8 days. Our hypothesis for repeat dose is that the release of growth factors as present in the alpha granules [5-7] of platelets which promote healing, should be timed to maintain the peak of proliferative phase of wound healing. The Proliferative phase of wound healing peaks on 3rd day. Hence the repeat dose of PRP is timed on every 4th day. Similarly the platelets get self activation when PRP is injected and may not need clotting cascade activation with platelet activators, which are essential to produce a activated platelet gel. The PRP is being used as regenerative medicine product for tendon healing, bone healing and in dental sciences. In all such instances its use is in the form of autologous Platelet rich Plasma liquid form, which injected at the site [6-8]. During piloting we also did a study on rabbit model tendon healing to correlate the inflammatory load of PRP assisted healing, through serial C-reactive Proteins estimations. We found that C-reactive protein peak is on 3rd day. Based on these we have included the repeat dose of the PRP repeat infiltration's on every 4th day. This has affected the results immensely. We did a pilot study on 25 cases with infiltration and repeat dose on 4th day, as adjunct to standard wound care, the results were very encouraging we developed the STARS protocol where in PRP is used as mainstay and as regenerative product without any further surgical or medical intervention, including obviating the intense local dressings.

The inclusion of Vitamin C is intended to be used as a placebo medicine towards patient satisfaction. Vitamin C is chosen on the basis that it's the only vitamin which has role towards angiogenetic tissue stabilisation, low in cost and good in taste, safe and has no significant side effects hence is most acceptable & appropriate to the Patients.

Conclusion

The STARS technique for PRP led wound healing in acute wounds is a safe, effective, easily reproducible and widely accessible way of treating even complex wounds. It can be imparted in a very standard manner across all the health care centre from territory to primary, without any risks. It needs just a little training towards PRP preparation and a low cost centrifuge machine. The results are predictable and good quality wound healing is ensured with control of infection and Pain. It obviates the need for surgical, medical interventions and intense local care. STARS may be the turning point in the history of wound management. A regenerative product (autologous PRP), is being used widely and easily, to overcome one of the largest problem of the humans; hoping to bring relief to millions who continue to suffer because of affordability and accessibility of expert health care. It is single, simple, cheaper and effective therapy for wound management, just as an ideal treatment should be.

Funding: Institutional support.

Conflict of Interest: Nil.

References

1. Gupta S, Jensen BB, Gabriel A, Holloway A, Niezgoda JA, et al. (2007) Differentiating negative pressure wound therapy devices: an illustrative case series. *Wounds* 19: 1-9.
2. Waniczek DA, Rudzki MK, Buda KK, Arendt J (2011) Searching for new wound healing strategies--problems and pitfalls. *Wiad Lek* 64: 313-319.
3. Skórkowska- Telichowska K, Czemplik M, Kulma A, Szopa J (2013) The local treatment and available dressings designed for chronic wounds. *J Am Acad Dermatol* 68: 117-126.
4. Fife CE, Carter MJ, Walker D, Thomson B (2012) Wound care outcomes and associated cost among patients treated in US outpatient wound centers: Data from the US wound registry. *Wounds* 24: 10-17.
5. Dhurat R, Sukesh M (2014) Principles and methods of preparation of platelet-rich plasma: A review and author's perspective. *J Cutan Aesthet Surg* 7: 189-197.
6. Cobos Campos R, Parraza Diez N, Aizpuru Barandiaran F (2013) Platelet-rich plasma in skin ulcer treatment. *Wounds* 25: 256-262.
7. Wang L, Gu Z, Gao C (2014) Platelet-rich plasma for treating acute wounds: a meta-analysis. *Zhonghua Yi Xue Za Zhi* 94: 2169-2174.
8. Gao F, Wang JX, Han Y (2009) Research advance on application of platelet-rich plasma in wound repair—review. *J Exp Hematol* 17: 840-843.
9. Kazakos K, Lyras DN, Verettas D, Tilkeridis K, Tryfonidis M (2009) The use of autologous PRP gel as an aid in the management of acute trauma wounds. *Injury* 40: 801-805.
10. Guo Y, Qiu J, Zhang C (2008) Follow-up study on platelet-rich plasma in repairing chronic wound nonunion of lower limbs in 47 cases. *Zhongguo Xiu Fu Chong Jian Wai Ke Za Zhi* 22: 1301-1305.
11. Salazar-Álvarez AE, Riera-del-Moral LF, García-Arranz M, Álvarez-García J, Concepción-Rodríguez NA (2008) Use of platelet-rich plasma in the healing of chronic ulcers of the lower extremity. *Actas Dermosifiliogr* 105: 597-604.
12. Sampson S, Gerhardt M, Mandelbaum B (2008) Platelet rich plasma injection grafts for musculoskeletal injuries: a review. *Curr Rev Musculoskelet Med* 1: 165-174.
13. Wanden-Berghe C, Granell L, Giménez JL, De Dios Praes J, Muñoz-Puller P (2014) Autologous growth factors in the treatment of chronic wounds. *Rev Enferm* 37: 51-54.


Author Affiliations

[Top](#)

¹Department of Orthopaedics, J. N. Medical College, Datta Meghe Institute of Medical Sciences, (DU) Wardha, India

²Department of Surgery, J. N. Medical College, Datta Meghe Institute of Medical Sciences, (DU) Wardha, India

Submit your next manuscript and get advantages of SciTechnol submissions

- ❖ 50 Journals
- ❖ 21 Day rapid review process
- ❖ 1000 Editorial team
- ❖ 2 Million readers
- ❖ More than 5000 
- ❖ Publication immediately after acceptance
- ❖ Quality and quick editorial, review processing

Submit your next manuscript at • www.scitechnol.com/submission