



Early Results of a Novel Mitral Valve Repair Procedure: The Interpapillary Polytetrafluoroethylene Bridge Formation

Nasri Alotti^{1*}, Károly Gombocz¹, Kiddy L Ume¹, Amer Sayour², Daniel Alejandro Lerman^{3*} and Aref Rashed¹

Abstract

Background: Surgical repair of ischemic mitral regurgitation (IMR) associated with chordal rupture in patients with ischemic cardiomyopathy is challenging as it aims to correct several structural pathologies at once. There are ongoing studies evaluating multiple approaches, however long term results are still scarce.

Methods and Results: 19 patients with IMR underwent mitral valve repair with interpapillary polytetrafluoroethylene (PTFE) bridge and neochordae formation at the Zala County Teaching Hospital. Concomitant coronary artery bypass grafting was performed in all patients. Post-procedural Transesophageal Echocardiogram (TEE) showed no mitral regurgitation (MR) in eighteen (94.7%) patients, with a leaflet coaptation mean height of 8 ± 3 mm. No operative mortality was observed. At the follow up (mean 17.7 ± 4.6 months; range 9 to 24 months), 17 (89%) patients showed no leakage and 2 had regurgitation grade ≤ 1 , with documented NYHA functional class I or II in all patients.

Conclusion: This retrospective study presents the first results of a novel surgical approach to treating ischemic mitral regurgitation. The interpapillary PTFE bridge formation is a safe and feasible surgical procedure that is reproducible, time sparing and effectively eliminates mitral valve regurgitation with promising long-term results.

Keywords

Mitral regurgitation; Mitral valve repair; Neochordae; Papillary muscle

Introduction

Ischemic heart disease is the most frequent cause of mitral regurgitation (MR) today, particularly in developed countries where rheumatic mitral valve disease has been nearly eradicated [1]. Ischemic mitral regurgitation (IMR) is caused by a complex interplay

of abnormal structural and functional processes [2]. The surgical treatment of choice for most cases of IMR is mitral valve repair, because it preserves the mitral apparatus and competence, does not require the lifelong anticoagulation, [3] and is associated with an improved quality of life with less morbidity as well as better long-term survival as opposed to replacement [4].

Since the mitral apparatus is a 3-dimensional functional valvular unit that comprises the left atrial wall, the mitral annulus, the two mitral leaflets, the subvalvular chordae tendineae, the papillary muscles, and the adjacent left ventricular wall, [5] the pathophysiologic processes that eventually lead to IMR are manifold, including left ventricle wall motion abnormalities; left ventricular remodelling leading to lateral and apical displacement of papillary muscles; annular dilation; alterations in the geometry of the inflow tract; restricted leaflet motion in systole; leaflet prolapse; and/or chordal rupture. We believe that such complex pathology suggests that proper approaches to its repair should target both valvular and subvalvular apparatus equally.

Although several procedures have been described to correct chronic IMR [6-8], an optimal procedure that is time sparing and corrects most aspects of the pathology have not yet been defined, and the long-term follow-up data are still scarce. Our study sought to present the first results of a novel method that approximates the displaced papillary muscles and implants sufficient neochordae as an adjunct procedure to annuloplasty and myocardial revascularization.

Methods

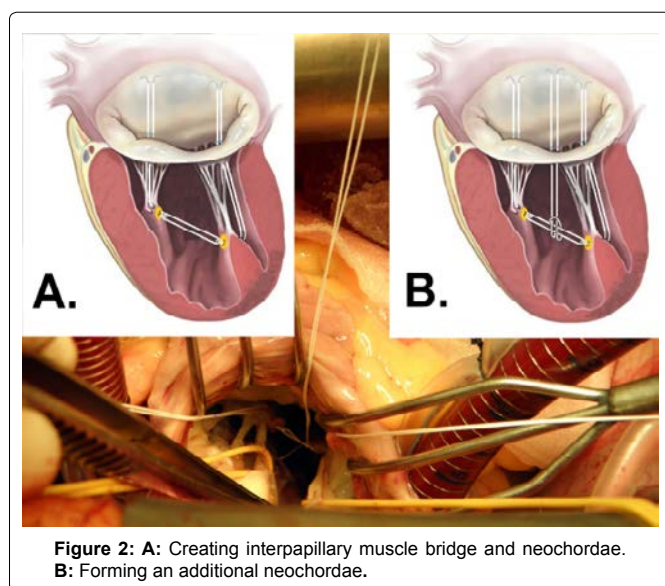
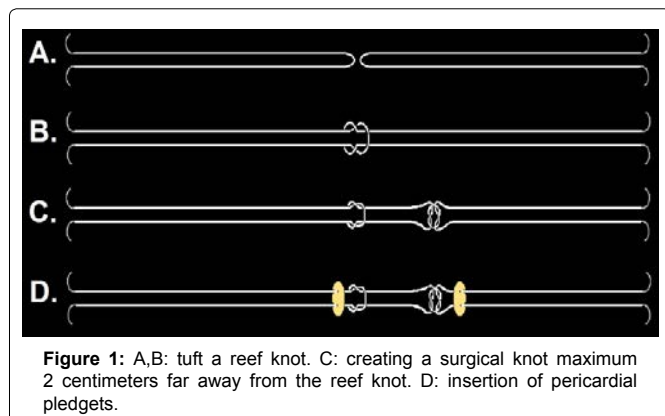
The study was designed as a single-center prospective feasibility study of patients who underwent mitral valve repair at the Zala County Hospital. Patients must have had ischemic mitral valve regurgitation (IMR) to be eligible for inclusion. All study protocols were approved by the Zala County Teaching Hospital & Pécs University of Science. Written patient's consent was obtained in all cases. We began performing this technique in the beginning of 2007.

19 patients underwent mitral valve repair for ischemic mitral regurgitation (IMR) using a novel procedure that involved interpapillary polytetrafluoroethylene (PTFE) bridge and neochordae formation. For all 19 cases our surgical technique was as follows: after pericardiotomy reef and surgical knots were performed maximum 2 centimeters from each other with two double armed, 4-0 PTFE threads (Figure 1A-1C). Autologous pericardial pledgets were attached to lock these knots (Figure 1D). After completing the coronary artery bypass procedure either with or without cardiopulmonary bypass, the mitral valve was exposed through left interatrial groove cardiomy. Marks indicating the length of the reference chordae were made on the PTFE free threads using a skin marker pen. One of the knotted threads was inserted through the posteromedial papillary muscle from the middle to the right, and the other thread through the anterolateral papillary muscle from the middle to the left forming an interpapillary muscle bridge, which approximates the papillary muscles to a distance of ≤ 2 cm (Figure 2A). Pledgets (which prevent their potential penetration into the scarring muscle) are not needed on the lateral sides of the papillary muscles, as knots are not placed on this side. The free ends of this bridge on the lateral side of the

*Corresponding authors: Nasri Alotti, Department of Cardiac Surgery, Zala County Hospital & Pécs University, Hungary. Tel: +36-92-507500; Ext.: 1290; Fax: +36-92-507500; Ext.: 1295; E-mail: nalotti@hotmail.com

*Daniel Alejandro Lerman, Department of Cardiothoracic Surgery, Royal Infirmary Hospital of Edinburgh (NHS Lothian) The University of Edinburgh, United Kingdom, Tel: 44-7854059667; E-mail: s0978484@staffmail.ed.ac.uk

Received: January 18, 2016 Accepted: February 06, 2016 Published: February 12, 2016



papillary muscles were used as neochordae and were passed through the prolapsed or ruptured coaptation zone and tied on the level of the pen marks. When necessary, additional neochordae were anchored to the interpapillary bridge, by forming a lark's head knot (Figure 2B). Restrictive mitral annuloplasty was performed subsequently.

Outcomes were evaluated on two separate occasions: preoperatively, and at a long-term follow-up visit. Perioperative assessment of immediate outcomes was performed by transesophageal echocardiography (TEE). Long-term postoperative evaluation was done on an outpatient basis at a mean of 17.7 months after surgery with cardiologic assessment and trans-thoracic echocardiography (TTE).

Results

Nineteen patients (15 males), aged 63 ± 7.7 years with chronic IMR were operated on using our novel procedure. Thirteen patients (68%) had New York Heart Association (NYHA) functional class III or IV congestive heart failure preoperatively. Mean data of preoperative echocardiographic findings were as follows: left ventricular ejection fraction: $37 \pm 7\%$, mitral regurgitation grade: 3.3 ± 0.6 , left ventricular end-diastolic diameter: 63 ± 8 mm, regurgitant volume: 42 ± 8 mL, and distance between the two papillary muscle heads in systole: 31 ± 3 mm (Table 1). Posterior or anterior leaflet prolapses were detected in

three cases and chordal rupture of P2, P3, A2 and A3 segments were detected in case number 12, 3, 1 and 2, respectively. The implanted ring's median size was 32 mm. Concomitant coronary artery bypass grafting was performed in all patients, and total aortic cross clamp mean time was 74 ± 7 min. TEE at the end of surgery showed no MR in eighteen (94.7%) patients, with a leaflet coaptation mean height of 8 ± 3 mm (Table 2). No operative mortality was observed. At the follow up (mean 17.7 ± 4.6 months; range 9 to 24 months) 17 (89%) patients showed no leakage and 2 had regurgitation grade ≤ 1 . Mean left ventricular ejection fraction was $48 \pm 9\%$ and mean left ventricular end-diastolic diameter was 56.3 ± 5.2 . No valve-related complications were observed and no re-interventions were necessary. One patient died at 13 months postoperatively due to extracardiac morbidity. Overall survival was 94.7%. NYHA functional class I or II was documented in 83.3% of these patients (Table 3).

Discussion

Although surgical treatment for primary mitral regurgitation is relatively straightforward, the management for chronic IMR is considerably more controversial [9]. Carpentier's techniques which generally involve resection of abnormal or pathologic tissue with precise reconstruction toward 'normal valve anatomy' remain the most commonly performed world-wide, and are associated with excellent long-term outcomes [10,11]. However, a new concept of 'respect rather than resect' tissue has become popular in recent years. It is based on the use of polytetrafluoroethylene (PTFE) neochordae to reconstruct support of the free edge of prolapsing segments, and to 'displace' abnormal excess tissue into the ventricle ensuring a good surface of coaptation [12]. Although our approach falls into the category of the latter, tissue preserving methodology, to our best knowledge, the technique of approximating the papillary muscles with an interpapillary bridge, have never been published before.

Our team believes that the complexity of chronic IMR pathology indicates that surgical repair of this disease must target the dysfunctions of the valvular and subvalvular apparatus equally. This

Table 1: Main preoperative patient's and echocardiographic variables.

Age	63 ± 7.7
Male	15
EF	$37 \pm 7\%$,
MR grade	3.3 ± 0.6
LVED	63 ± 8 mm
Regurgitant Volume	42 ± 8 mL
Interpapillary distance*	31 ± 3 mm

EF: Ejection Fraction; MR, Mitral Regurgitation; LVED: Left Ventricular End-diastolic Diameter

*Diameter was measured during systole

Table 2: Main intraoperative variables.

Aortic cross clamp time	74 ± 7 minutes
CABG, graft No.	2.3 ± 0.9
Coaptation height on TEE	8 ± 3 mm
Operative mortality	0%

Table 3: Main follow-up variables.

Follow-up time	17.7 ± 4.6 months
EF at follow-up	$48 \pm 9\%$
LVED at follow-up	56.3 ± 5.2
Overall survival	94.70%

EF: Ejection Fraction; LVED: Left Ventricular End-diastolic Diameter

concept is re-enforced by the fact that there is a high recurrence rate of MR after performing mitral annuloplasty alone in chronic IMR [13]. A variety of techniques on the subvalvular apparatus have been described to correct chronic IMR offering good results [6-8], but almost all of them are time consuming and technically demanding. Leaflet prolapse and/or chordae rupture as a combined pathology to chronic IMR can cause additional surgical challenges [14].

Taking the above mentioned concepts into consideration we developed and successfully applied a novel surgical approach to repairing IMR, by approximating the papillary muscles using interpapillary PTFE thread in a “bridge like” fashion, which also functions as artificial chordae on the sides. By anchoring additional threads to the interpapillary muscle bridge we can easily raise the number of the neochordae. We hypothesize that the joint power of papillary muscles can be increased by approximating them to each other, which redistributes the left intraventricular pressure, which in turn leads to a reduction of shear forces on the two muscles, the artificial chordae, and the reconstructed scallop. This method is effective in eliminating chronic IMR and theoretically it could be useful in reconstruction of other forms of mitral regurgitation demanding neochordal implantation or in minimally invasive approaches. According to our experience this technique is simple, reproducible and time sparing.

Limitations

While this is a single-center study with a small sample size, it was designed as a feasibility study to propose a novel procedure, which will need to be further validated by additional studies. Control groups, long term follow up and force measurements on the mitral valve apparatus are mandatory for further evaluation of this method.

Conclusions

The interpapillary polytetrafluoroethylene bridge formation is a safe and feasible surgical procedure that is reproducible, time sparing and effectively eliminates mitral valve regurgitation in the postoperative phase with promising long-term results.

Funding

This study was supported by “Zalaegerszeg Foundation for Heart Medicine”

References

1. Madesis A, Tsakiridis K, Zarogoulidis P, Katsikogiannis N, Machairiotis N et al. (2014) Review of mitral valve insufficiency: repair or replacement. *J Thorac Dis* 6: 39-51.
2. Pierard LA and Carabello BA (2010) Ischaemic mitral regurgitation: pathophysiology, outcomes and the conundrum of treatment. *Eur Heart J* 31: 2996-3005.
3. Stein PD, Alpert JS, Bussey HI, Dalen JE, Turpie AG (2001) Antithrombotic therapy in patients with mechanical and biological prosthetic heart valves. *Chest* 119: 220-227.
4. Gillinov AM, Blackstone EH, Nowicki ER, Slisatkorn W, Al-Dossari G, et al. (2008) Valve repair versus valve replacement for degenerative mitral valve disease. *J Thorac Cardiovasc Surg* 135: 885-893.
5. Bonow RO, Carabello BA, Chatterjee K, de Leon AC Jr, Faxon DP, et al. (2008) 2008 Focused update incorporated into the ACC/AHA 2006 guidelines for the management of patients with valvular heart disease: a report of the American College of Cardiology/American Heart Association Task Force on Practice Guidelines (Writing Committee to Revise the 1998 Guidelines for the Management of Patients With Valvular Heart Disease): endorsed by the Society of Cardiovascular Anesthesiologists, Society for Cardiovascular Angiography and Interventions, and Society of Thoracic Surgeons. *Circulation* 118: 523-661.

6. Hvass U, Tapia M, Baron F, Pouzet B, Shafy A (2003) Papillary muscle sling: A new functional approach to mitral repair in patients with ischemic left ventricular dysfunction and functional mitral regurgitation. *Ann Thorac Surg* 75: 809-811.
7. Rama A, Praschker L, Barreda E, Gandjbakhch I (2007) Papillary muscle approximation for functional ischemic mitral regurgitation. *Ann Thorac Surg* 84:2130-2131.
8. Isoda S, Osako M, Kimura T, Yamanaka N, Nakamura S, et al. (2011) Papillary muscle approximation and relocation with a loop technique for mitral complex repair. *Gen Thorac Cardiovasc Surg* 59: 454-458.
9. Carabello BA (2008) The current therapy for mitral regurgitation. *J Am Coll Cardiol* 52: 319-326.
10. Carpentier A (1983) Cardiac valve surgery--the “French correction”. *J Thorac Cardiovasc Surg* 1983. 86: 323-337.
11. Braunberger E, Deloche A, Berrebi A, Abdallah F, Celestin JA, et al. (2001) Very long-term results (more than 20 years) of valve repair with Carpentier's techniques in nonrheumatic mitral valve insufficiency. *Circulation* 104: 1-8-1-11.
12. Falk V, Seeburger J, Czesla M, Borger MA, Willige J, et al. (2008) How does the use of polytetrafluoroethylene neochordae for posterior mitral valve prolapse (loop technique) compare with leaflet resection? A prospective randomized trial. *J Thorac Cardiovasc Surg* 136: 1200-1206.
13. McGee EC, Gillinov AM, Blackstone EH, Rajeswaran J, Cohen G, et al. (2004) Recurrent mitral regurgitation after annuloplasty for functional ischemic mitral regurgitation. *J Thorac Cardiovasc Surg* 128: 916-924.
14. Jouan J, Tapia M, R CC, Lansac E, and Acar C (2004) Ischemic mitral valve prolapse: mechanisms and implications for valve repair. *Eur J Cardiothorac Surg* 26: 1112-1117.

Author Affiliations

Top

¹Department of Cardiac Surgery, Zala County Teaching Hospital & Pécs University of Science, Hungary

²Department of Cardiology, Petz Aladár Teaching Hospital & Pécs University of Science, Hungary

³Department of Cardiothoracic Surgery, Royal Infirmary Hospital of Edinburgh (NHS Lothian) The University of Edinburgh, United Kingdom

Submit your next manuscript and get advantages of SciTechnol submissions

- ❖ 50 Journals
- ❖ 21 Day rapid review process
- ❖ 1000 Editorial team
- ❖ 2 Million readers
- ❖ More than 5000 followers
- ❖ Publication immediately after acceptance
- ❖ Quality and quick editorial, review processing

Submit your next manuscript at • www.scitechnol.com/submission