



## Case Report

## A SCITECHNOL JOURNAL

Genital Well-Demarcated Plaques:  
What's your Diagnosis?

Bennani M\*, Dahouki S, Benkirane S, Elloudi S, Baybay H and Mernissi FZ

Department of Dermatology, University Hospital Hassan II of Fez, Fes 30050, Morocco

\*Corresponding author: Bennani M, Department of Dermatology, University Hospital Hassan II of Fes 30050, Morocco, Tel: +212660120505; E-mail: mouniaabennani24@gmail.com

Received date: August 13, 2019; Accepted date: August 26, 2019; Published date: September 04, 2019

## Abstract

Multiple small erythematous plaques of different size, well-defined with regular contours and smooth surface in place and scaly by others, at the level of the body of the penis of a young man of 28 years, and the balano-preputial groove. A cutaneous biopsy was performed demonstrating a moderately acanthotic epidermis with moderate papillomatosis surmounted by a thickened orthokeratotic corneal layer with a continuous compact continuous parakeratosis with focally rare polynuclear neutrophils.

## Keywords:

Penis; Chronic inflammatory; Genital psoriasis; Lymphocytes

## Case Presentation

28-year-old man, no notion of atopic personal or family or history of lesion evolving by thrust remission in the body or the scalp, no unprotected sex, who has had 15 days of genital lesions pruriginous at the beginning then becoming asymptomatic.

The rest of the clinical examination didn't show any other anomalies.

The patient and his wife were very worried.

Dermatological examination: Multiple small erythematous plaques of different size well-defined with regular contours and smooth surface in place and scaly by others, at the level of the body of the penis, and the balano-preputial groove.

The edematous papillary dermis contains a few elongated vessels, accompanied by slight perivascular inflammatory cuff essentially made of lymphocytes and some histiocytes. PAS staining does not show mycelium.

A cutaneous biopsy was performed demonstrating a moderately acanthotic epidermis with moderate papillomatosis surmounted by a thickened orthokeratotic corneal layer with a continuous compact continuous parakeratosis with focally rare polynuclear neutrophils (Figure 1).

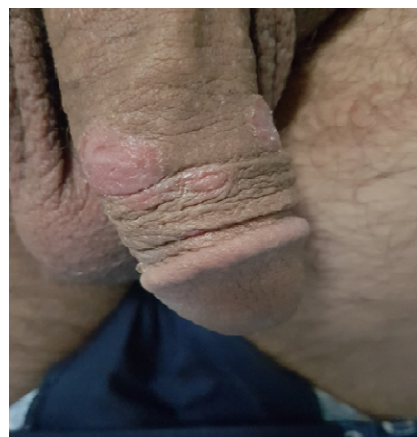

Figure 1: Multiple erythematous plaques at the penis.

Note that the patient was circumcised. Dermoscopy found homogeneous Dotted vessels with some white scales on erythematous background (Figure 2).

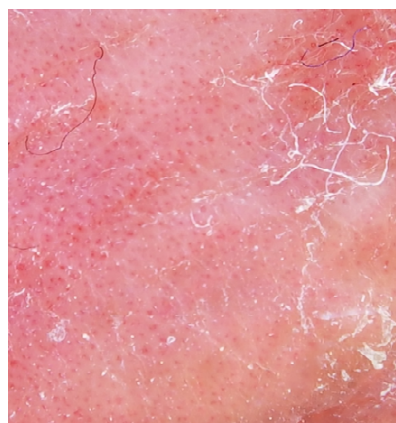


Figure 2: Dotted vessels with homogeneous and regular on erythematous background distribution.

## Discussion

## What's your diagnosis?

**Exclusively Genital Psoriasis:** Psoriasis is a chronic inflammatory skin disorder with a significant impact on social functioning [1]. Genital psoriasis has semiotic and therapeutic features. It can be classified into 3 categories: exclusive genital location of psoriasis, genital psoriasis associated with inverted psoriasis, and genital location associated with non-inverted extra-genital psoriasis [2].

The exclusively genital form of psoriasis seems to be rare and is seen in only 2 to 5% of psoriatic patients [3]. This is probably due to the modesty of patients about the discussion of the genital area, as well as the majority of patients do not know which doctor to consult, this

ocalisation can affect the quality of life and be a source of marital problems [4].

Clinically, genital psoriasis is manifested by one or more small, well-defined erythematous plaques.

usually finely scaly in the circumcised subject and non-scaly in the uncircumcised, most often localized in the glans and the inner foreskin, but can reach the entire external genital tract [2] Sometimes the lesions may be accompanied by painful rhagades or fissures [5].

These lesions can be maintained by the Koebner effect given the location: urine, rubbing (tight clothing), sex, wearing a condom [2].

The functional signs are generally mild to moderate and are represented by pruritus, a burning sensation or even skin pain [6,7].

Dermoscopy shows red dots of homogeneous distribution and white scales on erythematous background.

The diagnosis of psoriasis is usually clinical and dermoscopy remains a non-invasive technique that facilitates it. However, unusual presentations do exist and may cause difficulties in differentiating from similar-looking inflammatory conditions. In such cases, histopathology plays a significant role in confirming the clinical diagnosis [8,9], objectifying at the level of the glans and of the inner face of the foreskin, where the epidermis and the dermis leave respectively place to the epithelium and the chorion, a constant parakeratosis, an exocytosis of neutrophils sometimes forming pustules, a psoriasiform acanthosis and a dermal lymphocytic infiltrate of variable intensity sometimes associated with plasma cells, in the rest of the external genital tract, the histology is similar to that of cutaneous psoriasis [2].

## Conclusion

The treatment of genital psoriasis is generally based on topicals, as well as a good education to avoid the koebner effect. The recommended treatments for genital psoriasis are topical corticosteroids first-line, vitamin D preparations or tar based and

immunomodulators should be considered after failure of topical corticosteroid. Phototherapy and laser therapy are not recommended in the genital area.

## References

1. Ryan C, Sadlier M, De Vol E, Patel M, Lloyd AA, et al. (2015) Genital psoriasis is associated with significant impairment in quality of life and sexual functioning. *J Am Acad Dermatol* 72: 978-83.
2. Dauendorffer JN, Renaud-Vilmer C, Cavelier-Balloy B (2014) Male genital psoriasis. *Ann Dermatol Venerol* 141: 466-472.
3. Van de Kerkhof PCM (2003) Clinical Features. *Textbook of Psoriasis*. Oxford, Blackwell Publishing Ltd. pp:3-29.
4. Czuczwar P, Stępnia A, Goren A, Wrona W, Paszkowski T, et al. (2016) Genital psoriasis; A hidden multidisciplinary problem: A review of literature. *Ginek Pol* 87:717-721.
5. El Jouari O, Zaougui AA, Gallouj S, Senhaji G, Farih MH, et al. (2018) Isolated Genital Psoriasis. *Int J Pediat Health Care Adv* 5: 84-85.
6. Meeuwis KA, de Hullu JA, Int'Hout J, Hendriks IM, Sparreboom EE, et al. (2015) Genital psoriasis awareness program: Physical and psychological care for patients with genital psoriasis. *Acta Derm Venereol* 95: 211-216.
7. Ankad BS, Madarkar M (2017) Red dots caught red handed: Dermoscopy of genital psoriasis. *Clin Dermatol Rev* 1: 25-26.
8. James WD, Berger TG, Elston DM, Neahtaus IM (2006) Seborrheic dermatitis, psoriasis, recalcitrant palmoplantar eruptions, pustular dermatitis, and erythroderma. In: *Andrews' Diseases of the Skin. Clinical Dermatology* (12th edn) Philadelphia: Elsevier Saunders 185-98.
9. Menter A, Korman NJ, Elmetts CA, Feldman SR, Gelfand JM, et al. (2010) Guidelines of care for the management of psoriasis and psoriatic arthritis: Section 5. Guidelines of care for the treatment of psoriasis with phototherapy and photochemotherapy. *J Am Acad Dermatol* 62: 114-135.