



Outcomes of Impaction of Unusual Foreign Bodies in the Aero-digestive Tracts

Hussein Elkhayat* and Mohamed AK Salama Ayyad

Abstract

Backgrounds: Foreign body aspiration and swallow is principal cause of accidental death in children. all foreign bodies should not be placed in the aero-digestive tracts but some are common to find others are not that common which confuse the thoracic surgeon while trying to extract them successfully.

Methods: A retrospective descriptive study from 2011 till 2015. Inclusion criteria were all patient with history or radiological evidence of foreign body aspiration or swallow on the esophagus that underwent at least a trial of extraction either via scope, open surgery or VATS. unusual foreign body was described as foreign body that found in less than 0.5% of cases.

Results: Eighteen different unusual foreign bodies were occurred in 35 patients including sharp bottle cover, hair clip, pressure pin, ear ring, part of endotracheal tube, common bile duct stent, magnet and others. Eleven were impacted in esophagus and 24 were inhaled. Failed first attempt for bronchoscopic extraction was occurred in 6 cases, 4 of them need surgery and 2 were succeeded in the second bronchoscopic trial. Cases required surgery were 2 sharp objects that can't extracted safely via bronchoscopy and the other 2 were for slippery objects (marble ball and stone) that can't be grasped via forceps.

Conclusion: Unusual foreign body that face thoracic surgeon can be troublesome with a higher than usual morbidities and need for surgery. Every attempt should be made for increase awareness among parents and primary health care doctors about the possibility of inhaled or swallow of such objects.

Keywords

Foreign body; Thoracoscopy; VATS; Thoracotomy; Bronchoscopy/bronchus

Introduction

Foreign body aspiration (FB) is principal cause of unintentional death in children [1]. It is assessed that 1,000 children die annually in the USA because of FB aspiration [2]. In Egypt incidence are thought to be much more because of poverty and illiteracy, though no such data available [3]. Children below 3 years of age tend to discover things and have the trend to put most objects in their mouths, and are therefore at risk for a FB due to narrow airways and immature

protective mechanisms. FB may present with atypical or a misleading history. Presence of associated conditions such as asthma, pneumonia, croup and reactive airway diseases with bronchiectasis and atelectasis may lead to delay in diagnosis. Child's Parents must also be consulted and told about the risks of late presentation, which is the main cause of long-term complications such as recurrent airways infection or chronic pneumonia.

The classic presence of coughing, wheezing, and diminished breath sounds is seen in almost 40% of patients with foreign body aspiration. Air leak syndrome, comprising pneumothorax, pneumomediastinum, and subcutaneous emphysema, is seen in 1% to 2% of cases; and 25% of cases may remain asymptomatic for long periods [4].

all foreign bodies should not be placed in the aero-digestive tracts but some are common to find others are not that common which confuse the thoracic surgeon while trying to extract them successfully. We hypothesizes that unusual foreign body can be described as foreign body that found in less than 0.5% of cases to evaluate if a rare / usual finding of a foreign body would present with usual presentation and would this affect the management strategy or the outcome.

Objectives

To describe the different unusual foreign bodies that can goes into the aero digestive tracts, any difference in its presentation and the possible ways of its extraction in comparison of the usual foreign bodies on the daily practice.

Patients and Methods

A retrospective descriptive study from 2011 till 2015. Inclusion criteria were all patient admitted to the service with history or radiological evidence of foreign body aspiration or swallow on the esophagus that underwent at least a trial of extraction either via scope, open surgery or VATS. Patients' data were analyzed according to age, sex, type of foreign body, location of the foreign body, mode of extraction, number of endoscopic trials of removal prior to open surgery or VATS. complications and timing of the first intervention. unusual foreign body was described as foreign body that found in less than 0.5% of cases.

Results

Between 2011-2015 there were 1096 patients admitted to our service to have rigid bronchoscopy or esophagoscopy to extract or exclude foreign body inhalation or swallow with average 18.3 cases/month (Figure 1). Eighteen different unusual foreign bodies were occurred in 35 patients including sharp bottle cover, hair clip, pressure pin, ear ring, part of endotracheal tube, common bile duct stent, magnet, football valve, safety pin, rosary bead, marble ball, fragments of tracheostomy, syringe needle, tooth, stone, simple black hair clip and bullet (Figure 2). Eleven were impacted in esophagus and 24 were inhaled in tracheobronchial tree. History was positive in 34 patients.

*Corresponding author: Hussein Elkhayat, Cardiothoracic surgery department, Assiut university hospitals, Assiut, Egypt, Tel: +201005549653, Fax: +20882333327; E-mail: dr_khayat@hotmail.com

Received: October 23, 2016 Accepted: November 06, 2017 Published: November 14, 2017

Number of cases per month

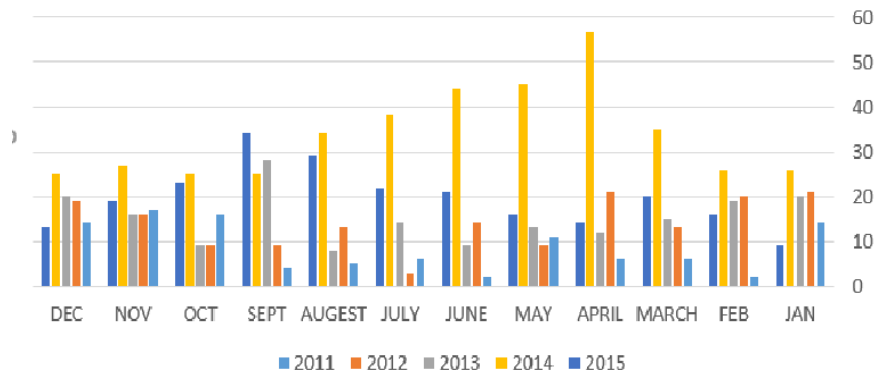


Figure 1: Distribution of cases per years and months.

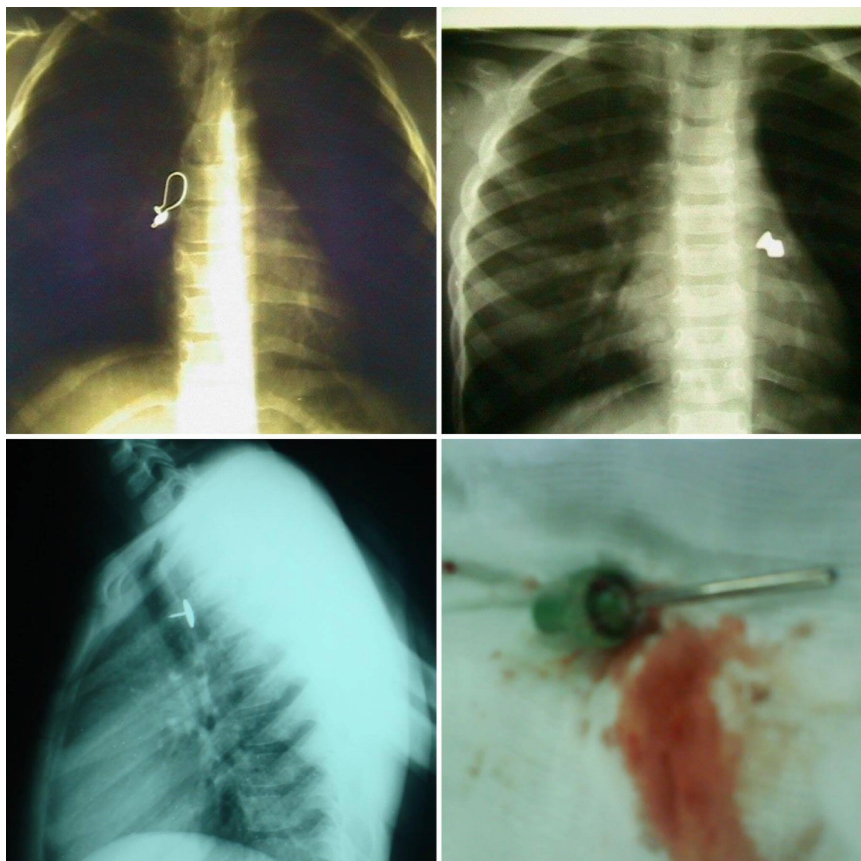


Figure 2: Different unusual FB extracted from aero Digestive tracts. Right upper; ear ring in the right main bronchus. Left upper; bullet inhaled in the left main bronchus. A pressure pin in the oesophagus. Football valve extracted from the right main bronchus.

Failed first attempt for bronchoscopic extraction was occurred in 6 cases, 4 of them need surgery and 2 were succeeded in the second bronchoscopic trial. Cases required surgery were 2 sharp objects (ear ring and pressure pin) that can't be extracted safely via bronchoscopy/ esophagoscopy and the other 2 were for slippery objects (marble ball and stone) that can't be

grasped via forceps. Surgery was done using open thoracotomy and bronchotomy for inhaled FB and open thoracotomy and esophagotomy with repair using mattress sutures for impacted swallowed FB.

There was no mortality in the cases of unusual foreign bodies despite the presence of 4 cases of death after bronchoscopy for

severely distress children whom aspirate nuts representing 0.36 % of all studied cases.

Discussion

Despite the fact that inhaled foreign bodies are different from swallowed ones in presentation and way of extraction but they both, Foreign body aspiration and swallow, are principal cause of accidental death in children and thoracic surgeon need to be familiar with dealing with them and there subsequent possible complications.

History, as always, is the best determinant of how suspicious one should be of a potential aspiration. However, this is often not recognized or discovered, or recognized by an older brother or sister who may have had a role in the aspiration and chooses not to say anything [5].

Bronchoscopy is of vital significance for diagnosis and treatment of bronchial foreign body aspiration. Traditionally, the instrument of choice for the management of tracheobronchial foreign body is the rigid bronchoscopy, especially if extraction is attempted [6].

Obstruction of the upper airway by food or other foreign objects is a well-known cause of accidental death in pediatric age group. It commonly occurred in children because (a) they tend to discover and place objects in their mouths (b) learning to walk and run; (c) inadequate dentition; (d) immature swallowing coordination; and (e) supervision by an older sibling [5].

But in children below 6 months of age, they are non-ambulatory and it is the elder child/ caretaker who puts the FB into younger child's mouth without knowing consequences [7]. so there is a considerable risk of foreign body aspiration. The morbidity and mortality increase in the younger age group, apparently because children of this age group have narrow airways and immature protective mechanisms, of those who died after a foreign body aspiration, 78% were aged between 2 months and 4 years [8].

1096 case of aero-digestive foreign body cases were enrolled in our study which could be consider as a large number of cases in 5 years in comparison to 1015 cases with the diagnosis of foreign body aspiration were evaluated and treated over 20 years In study by Nader Saki [9], in 2011 Albirmawy and Elsheikh [3] publish another 20 years' experience with 3600 cases. This could be explained as we merge cases of aspiration and swallow whereas they include only cases of aspiration and by the fact that our tertiary level hospital serves patients from more than 7 governorates exceeding 20 million people.

Most of the aspirated foreign bodies mentioned in literatures are organic materials, such as nuts and seeds in children, and food and bones in adults. The most common type of inorganic aspirated substances in children are beads, coins, pins, small parts of varies toys, and small parts of school equipment such as pen caps [10]. As nuts are the most frequently inhaled FBs in the Europe and United States, [11,12] but seeds, including watermelon and sunflower seeds, are reported to be the most commonly aspirated objects in the Middle East [13,14].

We define the unusual foreign body as foreign body that found in less than 0.5% of cases. We found 18 different types including sharp bottle cover, hair clip, pressure pin, ear ring, part of endotracheal tube, common bile duct stent, magnet, football valve, safety pin, rosary bead, marble ball, fragments of tracheostomy, syringe needle, tooth, stone, simple black hair clip and bullet.

Most publications were discussing the unusual presentation or chest x ray finding in cases of FB [15-17] except few publications which were concerned with the type of FB in relation to method of extraction and the possible complications [18,19].

Unusual FB represents 3% out of the whole number of cases presented in this series. We agree that the most important elements in diagnosing FB aspiration or swallow are clinical awareness, thorough clinical examination and adequate history taking.

When having a high level of clinical doubt with positive history corresponds to clinical findings, the proper next step is bronchoscopy, both for a final confirmation of the diagnosis and also for optimal treatment and extraction of foreign body [20].

Any lag in further intervention to remove the FB will lead to serious complications may necessitate surgical intervention to deal with. In our series, 4 cases only need further surgical intervention 2 sharp objects that can't extracted safely via bronchoscopy and the other 2 were for slippery objects, this is in agree and addition with indications for bronchotomy which includes failure to remove the foreign body despite repeated attempts under bronchoscopy or inability of bronchoscope to access the foreign body located below the subsegmental bronchial tree [21].

Conclusion

Unusual foreign body that faced thoracic surgeon can be troublesome with a higher than usual morbidities and need for surgery. Every attempt should be made for increase awareness among patients and primary health care doctors about the possibility of inhaled or swallow of such objects.

References

1. Abellán Martínez MC, Méndez Martínez P, Sánchez Gascón F, Hernández Martínez J, Ruiz López FJ (2000) Repeated hemoptysis for foreign body bronchial aspiration: presentation of a case and review of literature. *An Med Interna* 17: 652-654.
2. Orr DL (1993) Protection of the airway against foreign body aspiration. *J Oral Maxillofac Surg* 51: 1161.
3. Albirmawy OA, Elsheikh MN (2011) Foreign body aspiration, a continuously growing challenge: Tanta University experience in Egypt. *Auris Nasus Larynx* 38:88-94.
4. Akelma AZ, Cizmeci MN, Kanburoglu MK, Mete E (2013) An overlooked cause of cough in children: foreign body aspiration. *J Pediatr* 163: 292-293.
5. Fong EW (2002) Foreign body aspiration, in Case based pediatrics for medical students and residents. Bloomington. Honolulu, Hawaii.
6. Duan L, Chen X, Wang H, Hu X, Jiang G (2014) Surgical treatment of late-diagnosed bronchial foreign body aspiration: a report of 23 cases. *Clin Respir J* 8: 269-273.
7. Mundra RK, Agrawal R, Sinha R (2014) Unusual Foreign Body Aspiration in Infants Below 6 months of Age. *Indian J Otolaryngol Head Neck Surg* 66: 145-148.
8. Ozdemir C, Uzun I, Sam B (2005) Childhood foreign body aspiration in Istanbul, Turkey. *Forensic Sci Int* 153: 136-141.
9. Saki N (2009) Foreign body aspirations in infancy: a 20-year experience. *Int J Med Sci* 6: 322-328.
10. Dikensoy O, Usalan C, Filiz A (2002) Foreign body aspiration: clinical utility of flexible bronchoscopy. *Postgrad Med J* 78: 399-403.
11. Zerella JT (1998) Foreign body aspiration in children: value of radiography and complications of bronchoscopy. *J Pediatr Surg* 33: 1651-1654.
12. Black RE, Johnson DG, Matlak ME (1994) Bronchoscopic removal of aspirated foreign bodies in children. *J Pediatr Surg* 29: 682-684.

13. Aytac A (1977) Inhalation of foreign bodies in children. Report of 500 cases. J Thorac Cardiovasc Surg 74: 145-151.
14. Abdulmajid OA (1976) Aspirated foreign bodies in the tracheobronchial tree: report of 250 cases. Thorax 31: 635-640.
15. Etter H (1956) Unusual thoracic x-ray findings in aspiration of foreign body. Schweiz Med Wochenschr 86: 1394-1395.
16. Franchi D, Brero P, Poncini L, Cali M, Mancuso M (1985) Inhalation of a foreign body. Presentation of a case with an unusual clinical course. Minerva Pediatr 37: 883-885.
17. Ramadan HH, Bu-Saba N, Baraka A, Mroueh A (1992) Management of an unusual presentation of foreign body aspiration. J Laryngol Otol 106: 751-752.
18. Losacco T, Cagiano R, Luperto P, Bera I, Santacroce L (2009) An unusual foreign body in the upper aerodigestive tract: esophageal obstruction due to bran impaction. Eur Rev Med Pharmacol Sci 13: 475-478.
19. Tsagkaropoulos S, Francioni F, Ferretti G, Venuta F (2009) An unusual case of foreign body aspiration: a lobster's antenna. Eur J Cardiothorac Surg 36:185.
20. Sandhofer MJ, Salzer H, Kulnig J (2015) Foreign body aspiration - Sometimes a tough nut to crack. Respir Med Case Rep 15: 18-19.
21. Sersar SI (2006) Inhaled foreign bodies: presentation, management and value of history and plain chest radiography in delayed presentation. Otolaryngol Head Neck Surg 134: 92-99.

Author Affiliation

[Top](#)

Cardiothoracic surgery department, Faculty of Medicine, Assiut University, Assiut, Egypt

Submit your next manuscript and get advantages of SciTechnol submissions

- ❖ 80 Journals
- ❖ 21 Day rapid review process
- ❖ 3000 Editorial team
- ❖ 5 Million readers
- ❖ More than 5000 
- ❖ Quality and quick review processing through Editorial Manager System

Submit your next manuscript at • www.scitechnol.com/submission