



Case Report

A SCITECHNOL JOURNAL

Successful Treatment of Keratoconus using Allogenic Fresh Myopic Lenticule Implantation and Autologous Serum

Faruk Semiz*, Anita Sylva Lokaj, Njomza Hima-Musa, and Ceren Ece Semiz

Abstract

Purpose: We present a case study of a 19-year-old patient with severe keratoconus and chronic hydrops with a corneal scar who was treated with Fresh Myopic Lenticule (FML) implantation and autologous serum.

Methods: A 19-year-old female patient with keratoconus, chronic hydrops cornea, thin cornea (378 μm), and mild dry eye symptoms consulted our clinic. FML implantation was performed with Small Incision Lenticule Extraction (SMILE), and application of autologous serum was done postoperatively for 8 weeks.

Results: The central corneal thickness improved on the same day of the surgery, and vision improved 1 week postoperatively. The corneal topography showed a significant decrease in the anterior K1 and K2 values. The graft in the recipient cornea was clearly visible on anterior segment optical coherence tomography. On the 1-year follow up, the central corneal thickness remained stable at 474 μm without any complications.

Conclusion: A fresh lenticule was used in this lenticule implantation procedure with postoperative application of autologous serum on a patient with keratoconus which resulted in an increase in corneal thickness and improvement in visual acuity without any complications.

Keywords

Keratoconus; Fresh myopic lenticule; Stromal implantation; Smile surgery; Autologous serum

Introduction

Keratoconus is associated with progressive corneal ectasia and scarring. Corneal ectasia ultimately leads to irregular astigmatism, central anterior scarring, and reduced vision [1]. Although its exact etiology is unknown, corneal biochemical instability is considered to be one of the main causes [1]. Corneal hydrops is a rare complication of keratoconus characterized by stromal edema due to leakage of aqueous humor into the corneal stroma through a rupture in the Descemet's membrane [2]. The majority of cases are unilateral and

occur more frequently in males than in females, and is typically present in the second or third decade of life.

The current primary operative corrections for keratoconus are Corneal Collagen Cross-linking (CXL) therapy and corneal transplantation [3,4]. However, CXL halts the progression of keratoconus rather than cures it. Corneal transplantation is the most preferred procedure for severe keratoconus; however, it may lead to complications such as transplant rejection or infections especially in the absence of care and proper medications [5]. Moreover, this procedure is limited due to the deficit of corneal donor tissue [5].

Lenticule implantation has been previously performed on patients with keratoconus as an alternative to corneal transplantation [4]. However, the method described in this study is unique in that the donor lenticule used is fresh and myopic [6]. In this case, it was noted that FML implantation with SMILE surgery is a safe alternative to keratoplasty because it is less invasive and has no adverse effects based on the study's long-term results. In addition, autologous serum played a crucial role in the treatment by recuperating the corneal surface [7, 8].

Case Presentation

Patient history

A 17-year-old female patient with overall good health was first seen with complaints of visual impairment. She was diagnosed with high myopic astigmatism and prescribed glasses to enhance her vision by the primary ophthalmologist. She had not received any treatment or check-up for a period of time afterwards, and her vision problem progressed with no clear diagnosis. When her symptoms worsened, she consulted another eye clinic. She was diagnosed with keratoconus with an indication of keratoplasty by the second ophthalmologist. The patient could not receive any treatment because of her family's financial instability; moreover, she was uncomfortable with the keratoplasty procedure. She was then referred to us by the second clinic. Two years after the initial examination of the patient's visual acuity, she was seen at our clinic as an outpatient due to right/left eye vision and discomfort issues. Clinical examination and corneal topography, in addition to medical history, indicated development of her keratoconus with long-term scarring, dry eye syndrome, and chronic allergic conjunctivitis in her right eye. The patient denied any past ocular surgery or ocular trauma. Her past medical history was unremarkable, with no history of prior use of systemic medications. The only significant finding in the family history was keratoconus (male sibling). Social history was negative for tobacco, alcohol, and recreational drug use. She had no known allergies or drug allergies.

Ethical considerations

The study was conducted according to the International Conference on Harmonisation-Good Clinical Practice (ICH-GCP) guidelines. All procedures were approved by the Ethics Committee of the Ministry of Health of the Republic of Kosovo. The protocol was registered on clinicaltrials.gov (ClinicalTrials Reg: NCT04594512). Both donor and recipient patients were assessed according to designated standard operation procedures. Both patients then signed consent letters. A panel of blood tests were performed one week prior to the surgery as standard screening procedure on the donor's blood,

*Corresponding author: Faruk Semiz MD, Department of Refractive Surgery, Prishtina Eye Hospital, Postal Code: 10000 Prishtina, Republic of Kosovo, E-mail: faruksemiz@yahoo.com

Received: February 04, 2021 Accepted: February 19, 2021 Published: February 26, 2021

testing for Human Immunodeficiency Virus (HIV), hepatitis - A, - B, and - C viruses, wherein the tests came out negative. Treponema pallidum, and the outcome of antibody or molecular screening, and of cumulative results were negative. Blood glucose and rapid plasma regain levels were normal.

Clinical findings

Ocular examination of the right eye showed a dry oval cone and scarring of the ocular surface. (Figure 1) The manifest refraction and Corrected Visual Acuity (CDVA) were -8.50-6.00x10 (0.08 sc/0.1 cc) in the right eye. Left eye visual acuity was 0.9 sc/1.0 cc. Corneal Topography (ATLAS, Carl Zeiss Meditec Jena, Germany) showed a steep cornea with increased anterior posterior corneal elevation. The minimum corneal thickness in the right eye was 378 μ m, as measured by optical coherence tomography (optical coherence tomography) (AS-OCT-Zeiss) (Figure 2). ATLAS corneal topography showed steep K-values of 82.60 ax 37 and flat K-values of 75.15 D ax 127 with -7.45 corneal astigmatism. Her best-corrected visual acuity was 0.05 in the right eye and 1.0 in the left eye. A slit lamp examination revealed intense punctate epitheliopathy, and Tear Film Break-Up Time (TBUT) was measured as 7–8 s. Schirmer's test was used to assess the patient's tear production with 10 mm being measured in the right eye, indicating mild dry eye syndrome. Other eye examinations were normally performed.

Based on pachymetry and corneal topography, we decided that implantation via FML was a more favorable treatment compared to other treatments because her cornea was still intact and had a scar but no perforation. Hence, there was a chance that lenticule implantation could prevent the need for keratoplasty. After a comprehensive discussion with the patient regarding our experiences, the patient decided to receive the treatment.

Surgical technique

The SMILE surgery was performed on both donor and recipient patients on the same day in Eye Hospital Pristina, Kosovo, by the surgeon (F.S) using the VisuMax FS laser system (Carl Zeiss Meditec AG, Jena, Germany) [6].

Preparation of donor cornea

The donor patient underwent SMILE surgery. The refractive power of the donor was -6.00 D with a maximum lenticule thickness of 118 μ m. The optical zone (lenticule diameter) and cap diameters were 6.5 and 7.5 mm, respectively. After dissections of both anterior and posterior planes, the lenticule was extracted through a 120-degree superior 3.5 mm incision and marked with a sterile marker (Viscot-Medster). The lenticule was immersed in BSS solution for 10 min and was then implanted into the recipient's eye [6].

Lenticule implantation technique in the recipient patient

The VisuMax FS laser flap-cut procedures (Carl Zeiss Meditec AG), with an energy cut index of 30 nJ (150 nJ), spot and track spacing surface cuts of 4.5 μ m, and spot and trackside cuts of 2.0 μ m, were used to create an intrastromal pocket in the patient's cornea for implantation of the donor lenticule. The stromal pocket diameter was set to 7.5–8.0 mm (1 mm larger than the optical zone of the donor lenticule). The cap thickness was set to 130 μ m from the corneal surface through a 4-mm superior incision. The hinge position flap was set at 90°, hinge angle at 50°, hinge width at 4 mm, and side cut angle at 90°. The pocket was dissected using a blunt spatula. The lenticule, with the anterior aspect facing upward, was held with lenticule forceps, and then gently inserted into the pocket through the

4 mm superior incision. The incision position was changed according to the position of the highest K-values (82.60 ax 37). The lenticule was positioned around the marked center of the cone and ironed out from the surface using a blunt spatula. In the post-operative therapy, antibiotic eye drops (Vigamox), lubricant eye drops, and steroid eye drops (Maxidex) were applied 5 times daily for 1 month. In order to support the scar healing process and to treat the dry eye syndrome, autologous serum eye drops were used 6 times daily for 8 weeks [6].

Results

Postoperative examinations

1 Day: The patient returned for a postoperative check-up. A slit-lamp examination revealed minimal corneal edema and no stromal haze. The graft was well-centered and extended around 360°. No adverse effects were observed. The CDVA was 0.08 sc/0.05 cc. The central corneal thickness was approximately 787 μ m as measured by anterior segment OCT.

1 Week: The Uncorrected Visual Acuity (UDVA) improved by 0.1 sc in the right eye. The CDVA was 0.1 cc with a manifest refraction of -12.50 -5.25 ax 92. A slit-lamp examination showed improvement with no edema. ATLAS corneal topography showed -5.25 corneal astigmatism. The central corneal thickness was 538 μ m.

1 Month: The UDVA was 0.1 sc. The CDVA was 0.2 cc with a manifest refraction of -7.00-2.75x110. A slit-lamp examination showed no corneal edema and a well-placed lenticule in the stromal pocket. ATLAS corneal topography showed a steady decrease in corneal astigmatism as compared to the preoperative values. The central corneal thickness decreased to 518 μ m.

3 Months: The UDVA was 0.1 sc in the right eye. The CDVA was 0.2 cc with a manifest refraction of -7.00-3.00x27. A slit-lamp examination showed a well-integrated stromal graft. ATLAS corneal topography showed -3.25 total corneal astigmatism with a K-reading of 56.00 D. Total corneal thicknesses was 525 μ m.

6 Months: The central corneal thickness was stable in the right eye by the sixth month after operation. The UDVA was 0.1 sc, and CDVA was 0.2 cc with a manifest refraction of -6.50-3.50x65. ATLAS corneal topography measured a steep K-value of 48.41 D ax 143, and a flat K-value of 43.45 D ax 53 with -4.06 corneal astigmatism. The total corneal thickness arrived at the target point of 496 μ m.

1 Year: The UDVA was 0.1 sc, CDVA was 0.2 cc, slit lamp biomicroscopy show corneal transparency and regeneration of corneal thickness (Figure 3) and the central corneal thickness was 484 μ m by the first year after operation (Figure 4).

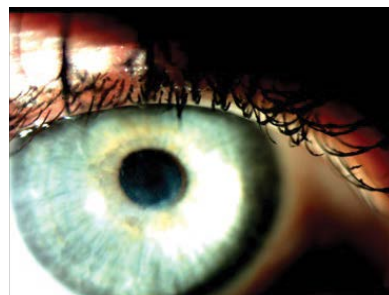

Figure 1: Biomicroscopic appearance of the right eye reflecting a dry oval cone and scarring the ocular surface.

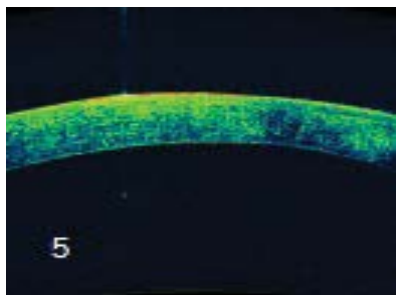


Figure 2: Show that corneal thickness in the right eye was 378 μm , as measured by optical coherence tomography (optical coherence tomography) (AS-OCT-Zeiss).

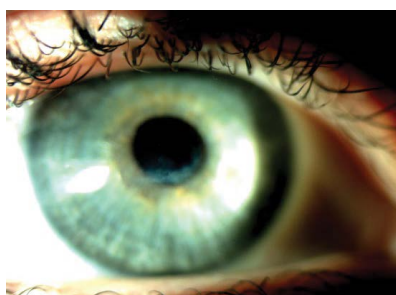

Figure 3: Biomicroscopic appearance of the right eye after 1 year after showing the regeneration of corneal thickness.

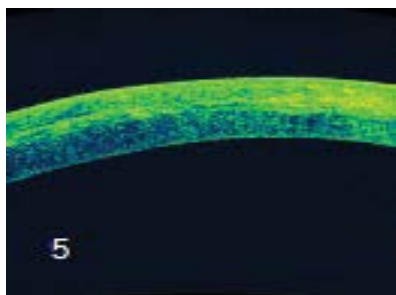


Figure 4: It demonstrates the results of transplant treatment by showing areas of prominent expansion of corneal thickness.

Discussion

Histopathologic features of keratoconus involve signs of stromal thinning, including iron deposition in the epithelial basement membrane and breaks in the Bowman's layer. Since 90% of the cornea is composed of stroma, the aim of this surgical procedure was to preserve the anatomical structure of the cornea, support stromal regeneration, and increase its thickness by implanting an FML. The fresh lenticule promotes stromal regeneration as it contains live stem cells that produce keratocytes, collagen fibers, and extracellular matrix [9].

Our surgical technique is distinguishable from prior lenticule implantation techniques due to the use of a fresh, newly dissected myopic lenticule and the determination of the implantation area based on a high K-value [4]. The fresh lenticule, obtained from a patient undergoing myopic correction, is thicker in the center and gradually thinner towards the periphery with a convex-concave positive meniscus lens. Therefore, it increases the corneal thickness

and balances the nasal and temporal sides of corneal thickness when implanted according to a high K-value.

After lenticule implantation, autologous serum application was initiated to treat the patient's corneal scar and dry eye syndrome. It contains epithelial and neuropathic growth factors, vitamins, fibronectin, and other components that have been considered essential for corneal and conjunctival integrity [7,8]. It was observed to contribute to the recovery process. Our patient's Schirmer's test result improved to 16 mm, which is considered to be within the normal range, as compared to the 10mm measured preoperatively. Therefore, we stopped the application of autologous serum 8 weeks postoperatively.

In our first study group (20 eyes), the recipients' eyes achieved significant recovery by the 6-month follow-up. However, the thinnest preoperative corneal thickness in the first study group was 381 μm [6]. Despite the current patient's corneal thickness being relatively thinner, she responded positively to the same surgical procedure without complications.

The targeted postoperative corneal thickness was set to 470–490 μm , a 95–100 μm increase from the preoperative central corneal thickness of 378 μm . At the 1-year follow-up, the target point was achieved with a central corneal thickness of 484 μm .

Conclusion

In conclusion, the efficacy and safety of FML implantation as a new surgical technique in a patient indicated for keratoplasty was demonstrated based on the study's 1-year follow-up results.

References

1. Daxer A, Fratzl P (1997) Collagen fibril orientation in the human corneal stroma and its implication in keratoconus. *Invest Ophthalmol Vis Sci* 38: 121-129.
2. Collier SA (2001) Is the corneal degradation in keratoconus caused by matrix-metalloproteinases? *Clin Exp Ophthalmol* 29:340-344.
3. Brown SE, Simmasalam R, Antonova N, Gadaria N, Asbell PA (2014) Progression in keratoconus and the effect of corneal cross-linking on progression. *Eye Contact Lens* 40: 331-338.
4. Pradhan KR, Reinstein DZ, Vida RS, Archer TJ, Dhungel S et al. (2019) Femtosecond Laser-Assisted Small Incision Sutureless Intrastromal Lamellar Keratoplasty (SILK) for Corneal Transplantation in Keratoconus. *J Refract Surg* 35: 663-671.
5. Musch DC, Meyer RF, Sugar A (1988) The effect of removing running sutures on astigmatism after penetrating keratoplasty. *Arch Ophthalmol* 106: 488-492.
6. Semiz F, Lokaj AS, Semiz O (2020) Corneal Lenticule Implantation in Keratoconus Disease with Relex Smile Surgery 3: 36-44
7. Matsumoto Y, Dogru Murat, Goto E, Ohashi Y, Kojima T, et al. (2004) Autologous serum application in the treatment of neurotrophic keratopathy. *Ophthalmology* 111: 1115-1120.
8. Guadilla AM, Balado P, Baeza A, Merino M (2013) Effectiveness of topical autologous serum treatment in neurotrophic keratopathy. *Arch Soc Esp Oftalmol* 88: 302-306.
9. Pinnamaneni N, Funderburgh JL (2012) Concise review: Stem cells in the corneal stroma. *Stem Cells* 30: 1059-1063.

Author Affiliation

Top

¹Department of Refractive Surgery, Prishtina Eye Hospital, Republic of Kosovo