



Research Article

A SCITECHNOL JOURNAL

Treatment of Chronic Tinnitus by Xenon Phototherapy on the Stellate Ganglion

Shimizu M*, Matsumi F, Suzuki D and Matsuzuka T

Abstract

Objectives/Hypothesis: To reveal the treatment utility of xenon phototherapy around the stellate ganglion for chronic tinnitus unresponsive to oral medications.

Study design: Outcome research.

Methods: Subjects were 24 patients (13 men, 11 women, mean age: 66 years) with chronic tinnitus unresponsive to oral medications and 8 patients (5 men, 3 women; mean age: 66 years) in the control group. Xenon phototherapy around the stellate ganglion (XPSG) was performed bilaterally for 10 minutes once monthly up to once weekly. At 3 months after the start of xenon phototherapy, treatment outcome was evaluated using the Tinnitus Handicap Inventory (THI) and a Numerical Rating Scale (NRS).

Results: No adverse effects of xenon phototherapy were observed. THI and NRS score were correlative. Wilcoxon's signed rank test revealed a significant improvement in THI ($p < 0.05$) and NRS score ($p < 0.01$) at 3 months. Patients in NRS scores classified as 'no handicap', 'mild' and 'severe' groups showed improvement ($p < 0.05$) at 3 months. THI scores improved in the severe group ($p < 0.05$). THI and NRS score did not statistically significantly differences in the control group

Conclusion: Although this study was preliminarily, XPSG improved patient's symptom of tinnitus measured by THI and NRS scores. XPSG was noninvasive and smart alternative therapy to SGB and promising treatment for chronic tinnitus unresponsive to oral medications.

Keywords

Tinnitus; Xenon phototherapy; Stellate ganglion block

Introduction

Tinnitus is defined as perceived sound originating in the head [1], and is a common complaint in clinical practice. The pathological physiology of tinnitus is largely unclear and there is no definitive treatment strategy as yet. In inner ear (cochlea) type, when inner hair cells have impaired blood flow, an auditory nerve becomes sensitive and is known to cause tinnitus. Stellate ganglion block (SGB) is widely used to alleviate pain and improve blood flow and is one of option for tinnitus. However, since it requires a needle puncture procedure, SGB is invasive and carries a risk of serious complications.

Xenon phototherapy around the stellate ganglion (XPSG) was reported as a safe and simple procedure, and has been performed to treat various clinical cases of pain in head and neck regions and orthopedic Clinics. In this study, XPSG was evaluated for the treatment of chronic tinnitus.

Materials and Methods

Subjects

The study was approved by the Institutional Review Board and Ethics Committee of the Fukushima Medical University. From April to October 2014, there were 30 patients with chronic tinnitus who had been treated at the otolaryngology outpatient clinic at the Fukushima Medical University Hospital and the Hoshi General Hospital. Magnetic resonance angiography was performed to exclude patients with organic lesions such as acoustic neuroma and inner ear malformation. In total, 24 eligible patients (13 men, 11 women; 66 ± 9.3 years old (mean \pm SD), range 45-82 years) who were unresponsive to oral medications more than one month were identified; ineffective medication included, vitamin B₁₂, Kampo (Chinese/Japanese traditional herbal medicines), drugs for improving blood circulation, such as nicotinamide, papaverine hydrochloride and adenosine triphosphate disodium hydrate (ATP) has the function to increase blood flow of the inner ear, and vitamin B12 has the effect of to improve an obstacle sensory function. Disease duration ranged 6-156 months; 45 ± 9.1 months (mean \pm SD). All patients consented to xenon phototherapy in this study. While the patients were receiving XPSG, drugs against tinnitus were discontinued, and anti-anxiety agents or sleep aids were gradually tapered with consultation. In addition, 8 patients (5 men, 3 women; mean \pm SD 66 ± 12 years old, range 37-78 years, 20 ± 7.0 months mean \pm SD, disease duration ranged 7-84 months) was performed as control group not to receive Xenon light irradiation (Table 1).

Methods of XPSG

The xenon phototherapy device Phos-01 (Nihon Iko Co., Tokyo, Japan) was used to illuminate the skin region above the stellate ganglion bilaterally with pulses duration once every 4 s in a 10-min session for XPSG (Figure 1a,b). The xenon light arrives at from the skin bottom approximately 7 cm, and the spectral range of xenon light has been 260-1100 nm and 18J once every emission, it has excellent water and blood permeability and penetrates not only the surface layer, but also deep layers of biological tissues because of the wavelengths with different tissue penetration properties [2] (Figure 1c). During the 3-month study period, phototherapy sessions were performed once monthly up to once weekly depending on the frequency of each patient's hospital visits.

The Tinnitus Handicap Inventory (THI) and a Numerical Rating Scale (NRS) were completed by patients to evaluate subjective tinnitus before and 3 months after the start of xenon phototherapy. THI is the questionnaire method consisting of 25 questions for assessment of subjective symptoms of tinnitus. The score reflects subjective pain caused by tinnitus in points up to 100 [3]. It is classified into four categories based on the total score: 0-16 as 'no handicap', 18-36 as 'mild', 38-56 as 'moderate', and 58-100 as 'severe'. NRS is the scale grading pain caused by tinnitus into levels from '0' to '10'. It is used for

*Corresponding author: Shimizu M, MD, PhD, Department of Otolaryngology, Fukushima Medical University School of Medicine, Hikarigaoka, Fukushima, 960-1295 Japan, Tel: 81-24-547-1111; Fax: 81-24-548-3011; E-mail: masako-s@fmu.ac.jp

Received: March 09, 2016 Accepted: June 07, 2016 Published: June 12, 2016

Table 1: Subjects, XPSG group and control group.

		XPSG (n24)	control (n8)
sex	male	13	5
	female	11	3
age	30-39y		1
	40-49y	1	
	50-59y	4	
	60-69y	10	3
	70-79y	7	4
	80-89y	2	
side	right	2	1
	left	7	1
	both	15	6

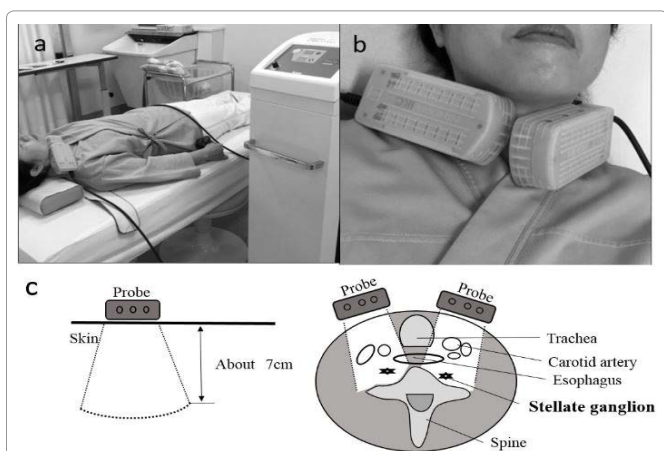


Figure 1: a) A scene of treatment and the apparatus of XPSG. Placement of XPSG probes around both stellate ganglion regions of the anterior neck in the supine position. b) Xenon spectrum based on penetration of light through skin. c) Wide range Irradiation and depth (Axial C6). Xenon light can arrive at SG.

the evaluation of stress and the sense other than a pain. It is classified into three categories as ‘mild’, ‘moderate’ and ‘severe’, however it is not unified [4,5]. At 3 months after the start of XPSG, changes in the THI and NRS scores were determined to assess treatment outcome in patients with different disease severity. In addition, the adverse impact on tinnitus was evaluated by classifying the patients into four groups based on their THI scores at 3 months.

Statistical Analysis

Wilcoxon’s signed rank test was used to determine the changes in THI and NRS scores, with the significance levels set at $p < 0.05$ and $p < 0.01$.

Results

No serious adverse events were reported except one patient who had light dizziness only the first time of the XPSG. During and after XPSG, there were no adverse events, such as Horner sign, burn, and hematoma.

Comparison of THI score

THI score before the start of XPSG ranged from 2 to 90, and the mean and median score were 39 and 31, respectively. THI score 3 months after the start of XPSG ranged from 4 to 70, mean and median score were 32 and 36, respectively (Figure 2a). Comparing before

and 3 months after the start of XPSG, THI score overall statistically significantly improved ($p < 0.05$, Figure 3a,3b). THI and NRS scores (mean \pm SEM) before and 3 months after XPSG are shown according to severity of tinnitus in Table 1. Among the different severity classes, there was highly significant improvement in the ‘severe’ group ($p < 0.05$, Table 2). More than 20 points of THI reduction was observed in 5 patients (20.8%). THI scores did not statistically significantly differences in the control group (Figure 3c).

Comparison of NRS score

NRS score before the start of XPSG ranged from 2 to 10, mean and median score were 5.9 and 6, respectively (Figure 2b). NRS score 3 months after the start of XPSG ranged from 0 to 8, mean and median score were 4.1 and 4, respectively. Comparing before and 3 months after the start of XPSG, NRS score statistically significantly improved ($p < 0.01$, Figure 4a,4b). NRS scores statistically significantly improved 3 months after therapy for ‘no handicap’, ‘mild’ and ‘severe’ groups of patients (Table 2). NRS scores did not statistically significantly differences in the control group (Figure 4c).

Discussion

Tinnitus is perception of unpleasant sound with no corresponding external sound sources [1] and is a common complaint in clinical practice. The prevalence of tinnitus is reported to be around 15% of general population [6] and that of severe tinnitus affecting everyday life is to be around 1-8%. However, the pathophysiology of tinnitus has not been clear and there is no definitive treatment strategy as yet. Although multidisciplinary approaches involving psychotherapy,

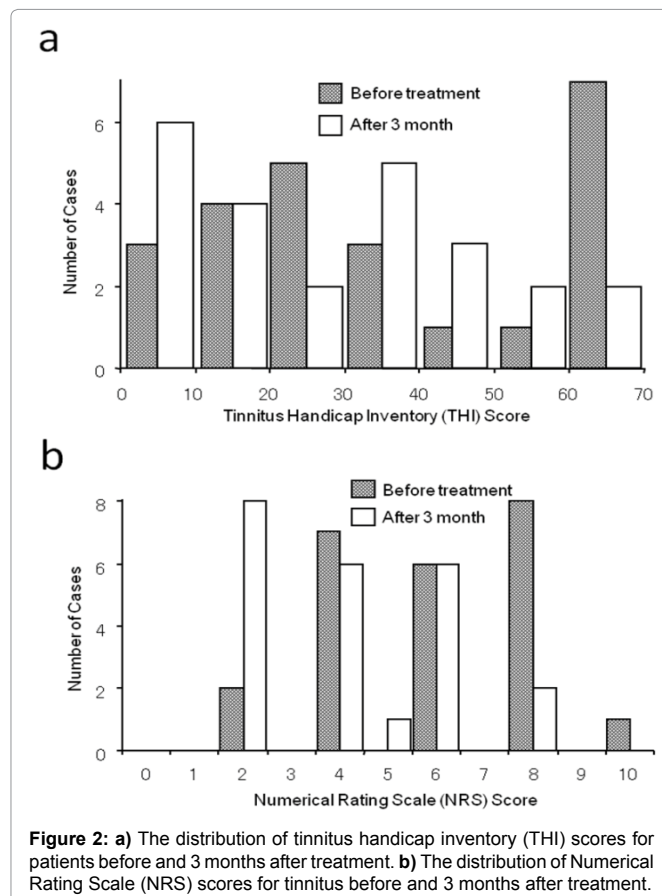


Figure 2: a) The distribution of tinnitus handicap inventory (THI) scores for patients before and 3 months after treatment. b) The distribution of Numerical Rating Scale (NRS) scores for tinnitus before and 3 months after treatment.

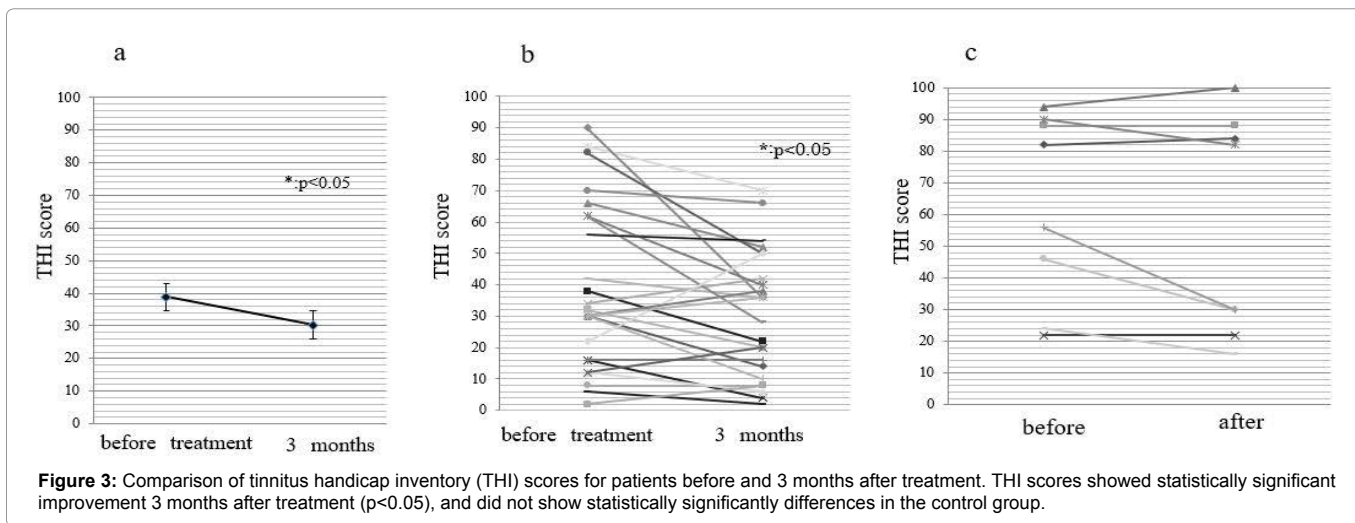


Figure 3: Comparison of tinnitus handicap inventory (THI) scores for patients before and 3 months after treatment. THI scores showed statistically significant improvement 3 months after treatment ($p < 0.05$), and did not show statistically significant differences in the control group.

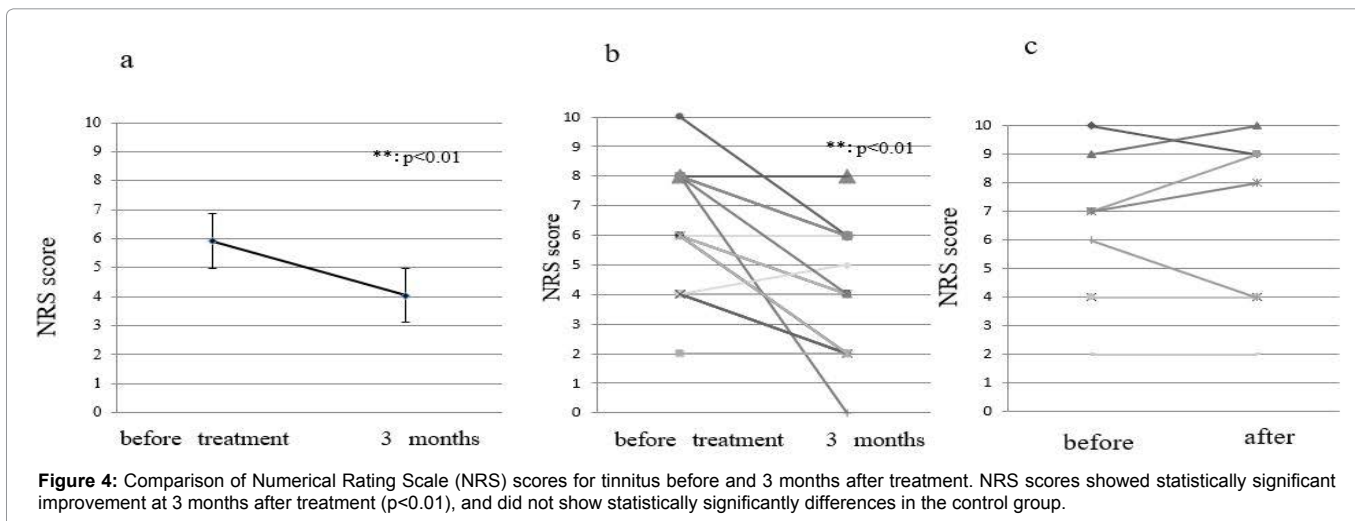


Figure 4: Comparison of Numerical Rating Scale (NRS) scores for tinnitus before and 3 months after treatment. NRS scores showed statistically significant improvement at 3 months after treatment ($p < 0.01$), and did not show statistically significant differences in the control group.

drug and acoustic therapy have conventionally been recommended for chronic tinnitus, they are yet to be fully established and the treatment remains a challenge.

The mechanism of tinnitus is broadly classified as peripheral type when the responsive anatomical site is the inner ear (cochlea) or auditory nerve, or as central type when the responsive anatomical site is in the central nervous system. Peripheral tinnitus is often associated with inner ear hearing loss mostly due to abnormal discharge of the cochlear nerve fibers due to blood flow disturbances in the cochlea [6]. In inner ear (cochlea) type, when inner hair cells have impaired blood flow, an auditory nerve becomes sensitive and is known to cause tinnitus [7]. According to Moller et al. [8] tinnitus subsides or resolves in approximately 40% of the patients treated with decompression of the cochlear nerve and blood vessels [8]. In addition to oral medications such as steroids, ones for improving blood circulation, and Kampo that are commonly prescribed for tinnitus, and also stellate ganglion block (SGB) is performed in pain clinics [9,10]. SGB is

widely used to alleviate pain and improve blood flow in patients with facial pain, shingles, facial nerve paralysis, sudden hearing loss, and many other pathological conditions. However, because the needle puncture site in the procedure is close to the vertebral artery

and recurrent laryngeal nerve, SGB carries a high risk of serious complications including recurrent laryngeal nerve paralysis, subdural and subarachnoid block, pyogenic spondylitis, and retropharyngeal or cervicomediastinal or mediastina hematoma [11,12].

In addition, relatively few physicians in otolaryngology practice are highly experienced in SGB. In many patients, inner ear hearing loss is accompanied by tinnitus due to primarily impaired blood flow in the cochlea. SGB has been used widely in clinical settings to improve impaired blood flow in the head and neck associated with various diseases.

The xenon phototherapy has been used for vasodilatation and wound healing [13]. The popularity of XPSG has been growing in recent years due to its safety, simplicity, and comparable efficacy with SGB. However, no definitive treatment for tinnitus has been established thus far.

In this study, we selected non-invasive and bio-permeable xenon light with steady and optimal light energy to irradiate the stellate ganglion located deep inside the neck region, anterior to the transverse process of the 7th cervical vertebra and posterior to the vertebral artery. The xenon gas is used in xenon phototherapy as a medium to generate so-called xenon light, a multi-wavelength white

Table 2: Changes in tinnitus handicap inventory (THI) and Numerical Rating Scale (NRS) before and 3 months after xenon phototherapy.

Severity of tinnitus (THI before treatment)	Number of Patients	THI score		NRS score		
		Before	3months	Before		3 months
'No handicap'	7	10 ± 2.0	9.1 ± 2.5	4.3 ± 0.8	* ↔	1.7 ± 0.3
'Mild'	7	30 ± 1.4	30 ± 5.6	5.4 ± 0.6	* ↔	3.6 ± 0.4
'Moderate'	3	45 ± 5.5	37 ± 9.3	6.0 ± 1.2		5.3 ± 1.3
'Severe'	7	74 ± 4.3	49 ± 5.8	8.0 ± 0.4	* ↔	6.3 ± 0.3
Total	24	39 ± 5.4	30 ± 4.1	5.9 ± 0.4	** ↔	4.0 ± 0.4

light with a broad wavelength ranging from the ultraviolet to infrared light, which illuminates light including wide wavelength distribution [14]. Although the spectral range of the light is 260–1100 nm, with a broad peak at around 700–900 nm, it has excellent water and blood permeability and penetrates the surface layer as well as deep layers of biological tissues [14]. Depth of the stellate ganglion is reported to be about 24 mm [15], and the xenon light reaches about 7 cm depth in the connective tissue. Therefore, XPSG can easily affect the stellate ganglion. Due to pulsed illumination and the special wide probe, the xenon phototherapy device was designed safely and simply to irradiate a wide area with high energy. In this study, there were no adverse events, such as Horner sign, burn, and hematoma. One patient had light dizziness only the first time. The change of the blood circulation may have been the cause. XPSG is safe considering high risks associated with needle puncture in SGB. According to the manufacturer's specifications, xenon phototherapy is contraindicated for safety reasons in patients with a pacemaker because of the proximity between the treatment probe and the pacemaker.

The mechanism of action and clinical efficacy of xenon phototherapy include vasodilation, promotion of tissue repair, and anti-inflammation. The therapy is performed to facilitate blood flow [15], pain relief [16,17], and wound repair [13,18]. For tinnitus, the mechanism through which xenon phototherapy improves blood flow disturbances in the inner ear appears to be as follows: XPSG interrupts nerve conduction within the ganglion and thus suppresses the activity of the sympathetic nerves by alleviating tension and dilating peripheral blood vessels, thereby improving blood flow in the head and neck region [19].

After XPSG, THI and NRS score overall statistically significantly improved in the present study. More than 20 points of THI reduction, that was considered to be clinically significant by Newman et al. [20], was observed in 5 patients (20.8%). patients in the 'severe' tinnitus group improved significantly in outcome with XPSG. Based on these clear improvements in THI and NRS scores, XPSG can be considered as a noninvasive and smart alternative therapy to SGB and promising treatment for chronic tinnitus unresponsive to oral medications. In this study, THI and NRS scores have not seen statistically significant differences in the control group. As this study is a preliminary, further large scale studies to validate our results are warranted.

Conclusion

- XPSG was performed to investigate its efficacy in the current preliminary study in 24 patients with chronic tinnitus unresponsive to oral medications, 8 patients in the control group.

- Statistically significant differences were observed in overall tinnitus THI and NRS scores by XPSG before and 3 months after treatment. Statistically significant differences were not observed THI and NRS scores in the control group.
- XPSG was noninvasive and smart alternative therapy to SGB and promising treatment for chronic tinnitus. However, any adverse reactions should be closely monitored.

References

- Tinnitus: Facts, Theories, and Treatments (1982) National Research Council (US) Committee on Hearing, Bioacoustics, and Biomechanics. Washington (DC): National Academies Press, USA.
- Tromberg BJ, Shah N, Lanning R, Cerussi A, Espinoza J, et al. (2000) Non-invasive in vivo characterization of breast tumors using photon migration spectroscopy. *Neoplasia* 2: 26-40.
- Newman CW, Jacobson GP, Spitzer JB (1996) Development of the Tinnitus Handicap Inventory. *Arch Otolaryngol Head Neck Surg* 122: 143-148.
- Serlin RC, Mendoza TR, Nakamura Y, Edwards KR, Cleeland CS (1995) When is cancer pain mild, moderate or severe? Grading pain severity by its interference with function. *Pain* 61: 277-284.
- Given B, Given CW, Sikorskii A, Jeon S, McCorkle R, et al. (2008) Establishing mild, moderate, and severe scores for cancer-related symptoms: How consistent and clinically meaningful are interference-based severity cutpoints? *J Pain Symptom Manage* 35: 126-35.
- Evered D, Lawrenson G (1981) MRC Institute of Hearing Research: Epidemiology of Tinnitus (Ciba Foundation Symposium, Pitman, London, UK).
- Zenner HP, Erust A (1993) Cochlear-motor, transduction and signal-transfer tinnitus: models for three types of cochlear tinnitus. *Eur Arch Otorhinolaryngol* 249: 447-454.
- Moller MB, Moller AR, Janetta PJ, Jho HD (1993) Vascular decompression surgery for severe tinnitus: selection criteria and results. *Laryngoscope* 103: 421-427.
- Carron H, Litwiller R (1975) Stellate ganglion block. *Anesth Analg* 54: 567-570.
- Erickson SJ, Hogan QH (1993) CT-guided injection of the stellate ganglion: description of technique and efficacy of sympathetic blockade. *Radiology* 188: 707-709.
- Okuda Y, Urabe K, Kitajima T (2003) Retropharyngeal or cervicomedialastinal hematomas following stellate ganglion block. *Eur Journal of Anaesthesiology* 20: 757-759.
- Higa K, Hirata K, Hirota K, Nitahara K, Shono S (2006) Retropharyngeal hematoma after stellate ganglion block: analysis of 27 patients reported in the literature. *Anesthesiology* 105: 1238-1245.
- Woodruff LD, Bounkeo JM, Brannon WM, Dawes KS, Barham CD, et al. (2004) The efficacy of laser therapy in wound repair: A meta analysis of the literature. *Photomed Laser Surg* 22: 241-247.
- Hideki Y, Naoya N, Toshimitsu D (2009) Effects of Transcutaneous Xenon Light Irradiation around the Stellate Ganglion on Autonomic Functions. *J Phys Ther Sci* 21: 1-6.
- Chaudhry H, Lynch M, Schomacker K, Birngruber R, Gregory K, et al (1993) Relaxation of vascular smooth muscle induced by low-power laser radiation. *Photochem Photobiol* 58: 661-669.
- Chow RT, Johnson MI, Lopes-Martins RA, Bjordal JM (2009) Efficacy of low-level laser therapy in the management of neck pain: A systematic review and meta-analysis of randomized placebo or active treatment controlled trials. *Lancet* 374: 1897-1908.
- Bjordal JM, Couppe C, Chow RT, Tuner J, Ljunggen EA (2003) A systematic review of low level laser therapy with location-specific doses for pain from chronic joint disorders. *Aust J Physiother* 49: 107-116.
- Anders JJ, Borke RC, Woolery SK, Van de Merwe WP (1993) Low power laser irradiation alters the rate of regeneration of the rat facial nerve. *Lasers Surgery Med* 13: 72-82.

19. Mii S, Kim C, Matsui H, Oharazawa H, Shiwa T, et al. (2007) Increases in central retinal artery blood flow in humans following carotid artery and stellate ganglion irradiation with 0.6 to 1.6 micron irradiation. *J Nippon Med Sch* 74: 23-29.

20. Newman CW, Sandridge SA, Jacobson GP (1998) Psychometric adequacy of the tinnitus handicap inventory (THI) for evaluating treatment outcome. *J Am Acad Audiol* 9: 153-160.

Author Affiliations

[Top](#)

Department of Otorhinolaryngology (MS, TM, DS, KO), Fukushima Medical University Hospital, Fukushima, Japan, Department of Otorhinolaryngology (SS,FM), Hoshi General Hospital, Fukushima, Japan

Submit your next manuscript and get advantages of SciTechnol submissions

- ❖ 50 Journals
- ❖ 21 Day rapid review process
- ❖ 1000 Editorial team
- ❖ 2 Million readers
- ❖ More than 5000 
- ❖ Publication immediately after acceptance
- ❖ Quality and quick editorial, review processing

Submit your next manuscript at • www.scitechnol.com/submission