



Back Pain Causes Connected with So-Called Idiopathic Scoliosis and Hiperlordosis of Lumbar Spine in Cases with Minimal Brain Dysfunction, Symptoms and Advises for Therapy

Karski Tomasz^{1*}, Karski Jacek², Karska Klaudia³

Department of Medical, Vincent Pol University, Lublin, Poland

Department of Orthopedic and Rehabilitation, Vincent Pol University, Lublin, Poland

Department of Radiology, Vincent Pol University, Lublin, Poland

*Corresponding author: Tomasz K, Department of Medical, Vincent Pol University, Lublin, Poland E-Mail: tmkarski@gmail.com/t.karski@neostrada.pl

Received date: 16 August, 2022, Manuscript No. JSNS-22-67115;

Editor assigned date: 18 August, 2022, PreQC No. JSNS-22-67115 (PQ);

Reviewed date: 03 September, 2022, QC No JSNS-22-67115;

Revised date: 08 September, 2022, Manuscript No. JSNS-22-67115 (R);

Published date: 15 September, 2022, DOI: 10.4172/2325-9841.1000125

Abstract

The back pain is a frequent problem of patients in orthopedics and neurology departments. In our opinion, the causes of the spine pain are connected with various anatomical disorders like bigger than normal or smaller than normal physiological curves, or because of scoliosis. In patients with back pain it can be scoliosis in the form "C" and "S" curves and it is 2nd / A / B / etiopathological (epg) type in new classification. There are also other causes of back pain, like spondylolysis, spondylolthesis, prolaps of nucleus pulpous, but in the article we focus on the two causes mentioned above - hiperlordosis of lumbar spine and scoliosis. In our research we found that etiology of scoliosis is connected with biomechanical factors - "permanent standing 'at ease' on the right leg" and walking / a particular gait, described thoroughly in the article. Recognizing the causes is essential as determines the kind of therapy and prophylaxis that should be used in the treatment of young and / or adult patients.

Keywords: Back pain causes; Hiperlordosis of lumbar spine; Scoliosis; Therapy; Prophylaxis

Back Pain in Patients with Scoliosis, Lumbar Hiperlordosis and Others Causes Material

In our orthopedic praxis (1995-2020) - we treat younger patients in age 2-25 with problems of scoliosis deformity-material 2500 cases and 437 adult patients in age 50-70 with problems of spine pain [A] The problem of back pain is connected with abnormalities of spine anatomy in changed axis - for example in scoliosis "C" and "S" in 2nd etiopathological group (epg) and type in Lublin classification [9-31]. We present the explanation of the development of scoliosis in next subchapter (FIG. 1-4).

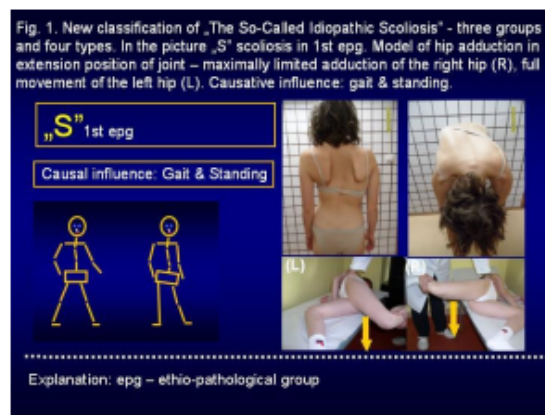


Figure 1: New classification of “The So-Called Idiopathic Scoliosis”- three groups and four types. In the picture “S” scoliosis in 1st epg. Model of hip adduction in extension position of joint - maximally limited adduction of the Right hip (R), full movement of the Left hip (L). Causative influence: gait and standing.

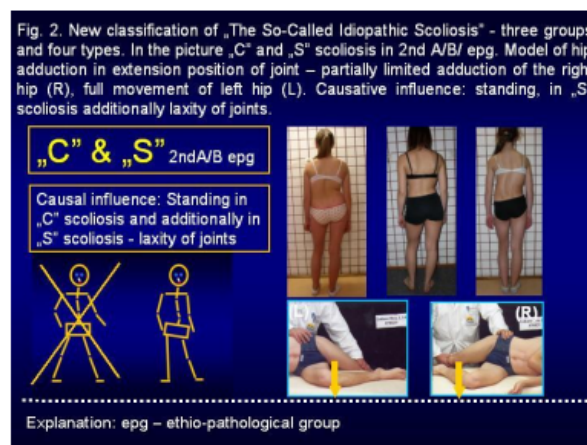


Figure 2: New classification of “The So-Called Idiopathic Scoliosis” - three groups and four types. In the picture “C” and “S” scoliosis in 2nd A/B/ epg. Model of hip adduction in extension position of joint - partially limited adduction of the Right hip (R), full movement of Left hip (L). Causative influence: standing, in “S” scoliosis additionally laxity of joints.

[B] Back pain can appear also if the spine is stiff and such symptoms are typical for “I” scoliosis in 3rd epg group and type in new Lublin classification [9-31]. Why stiffness occurs? The answer - the stages of this deformity are the following: first, - is lack of adduction and internal rotation movement of the right hip or both hips in affected patients, second, a compensatory movement, transmitted to the pelvis and to the spine, appears. It causes a “distortion movement” of inter-vertebral joints which results in stiffness. In our material, the stiffness of the spine is a very frequent cause of back pain (Figure. 1-3, 4,7).

[C] Second group of influences leading to “low back pain” is “hiperlordosis of lumbar spine” [22-28]. In last years of XX century

and in all years of XXI century we see in Orthopedics Department and in Out-Patients Clinics very frequent children, youth persons and also adult person with the symptoms of Minimal Brain Dysfunction (MBD). In these patients we observe a shortening (in orthopedic language - 'contracture') of m. triceps surae and Achilles tendon, flexors of the knees and flexors of the hips. In result of the contractures of the hips flexors appears "hiperlordosis of lumbar spine". In our material, hiperlordosis is very frequently the cause of the back pain. As far as the influence of the Central Nervous System is concerned, it is responsible for following symptoms of MBD [1-5,11] already in small children and babies (Figure. 5,6)

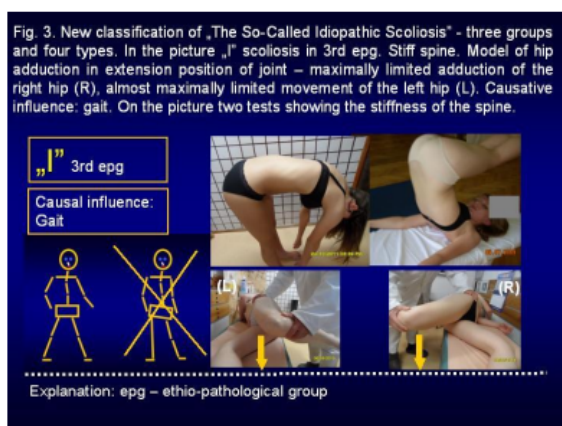
a. Laxity of joints - which causes a diminished stability of joints, increases the development of scoliosis.

b. Contracture of the extensors trunk's muscles - which, in next years, leads to stiff spine in two groups and three types of scoliosis (Figure. 7).

c. Anterior tilt of pelvis and hiperlordosis of lumbar spine (Figure. 5,6) as result of flexion contracture of hips flexors - which diminishes the stability between pelvis and spine and increases the degenerative processes in adults. All these abnormalities should be cured in the childhood. Here we repeat - hiperlordosis of lumbar spine - typical for many children with MBD - if not treated in childhood - makes very serious "back pain problems" in adults. These patients form the biggest group in our material.

d. Other causes of back pain are connected with the spondylolisis and spondylolisthesis, with congenital malformations of the spine or the thorax [22].

In all last years in Poland neurology doctors or neuro - surgeons diagnosed mostly back pain as result of "prolapsed nucleus pulpous" and proposed to all patients - surgery. Doctors never give patients the reasons of the "prolapsed nucleus pulpous". Our explanation of these symptoms - they occur because of lumbar left convex scoliosis or because of lumbar hiperlordosis. Both abnormalities need in first plan the therapy and not surgery as treatment of "end stage" of this pathology, it means - pain. In situation of distinguished and recognized "causes of the back pain" - patients need in first plan the therapy to cure the scoliosis or cure the hiperlordosis of lumbar spine as well as the pain.



3rd epg. Stiff spine. Model of hip adduction in extension position of joint - maximally limited adduction of the Right hip (R), almost maximally limited movement of the Left hip (L). Causative influence: gait. On the picture two tests showing the stiffness of the spine.




Figure 4: Two forms of test of adduction of the left and right hip. Patient on side. Stabilization of the pelvis. Checking of adduction of the right (R) and left (L) hip. Test with the knee in extension (R1, L1) and in flexion (R2, L2) This second test is more sensible. There are three various models of hip adduction and three groups & four types of scoliosis.

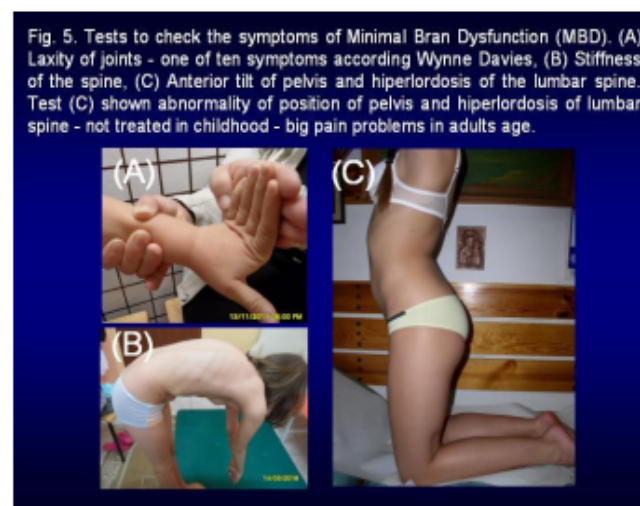

Figure 5: Tests to check the symptoms of Minimal Brain Dysfunction (MBD). (A) Laxity of joints - one of ten symptoms according Wynne Davies, (B) Stiffness of the spine, (C) Anterior tilt of pelvis and hiperlordosis of the lumbar spine. Test (C) shown abnormality of position of pelvis and hiperlordosis of lumbar spine - not treated in childhood - big pain problems in adults age.

Figure 3: New classification of "The So-Called Idiopathic Scoliosis" - three groups and four types. In the picture "I" scoliosis in

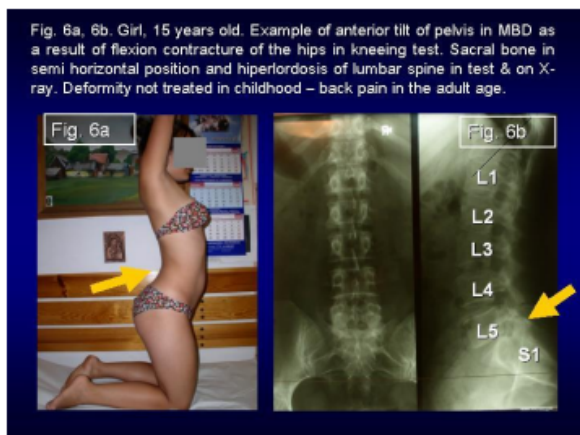


Figure 6 a, b: Girl, 15 years old. Example of anterior tilt of pelvis as a result of flexion contracture of the hips in kneeling test. Sacral bone in semi horizontal position and hiperlordosis of lumbar spine in test & on X-ray. Deformity not treated in childhood – back pain in the adult age.

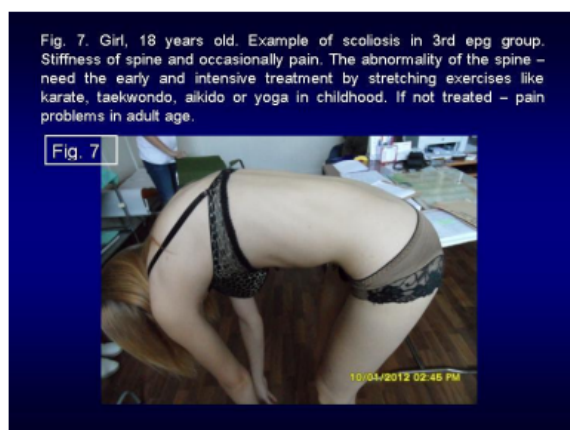

Figure 7: Girl, 18 years old. Example of scoliosis in 3rd epg group. Stiffness of spine and occasional pain. The abnormality of the spine – need the early and intensive treatment by stretching exercises like karate, taekwondo, aikido or yoga in childhood. If not treated - pain problems in adult age.

Etiology of the So-Called Idiopathic Scoliosis. [Adolescent Idiopathic Scoliosis (AIS)] - One of the Cause of “Back Pain” (FIG. 1-4) [1-46].

The etiology of “the idiopathic scoliosis” was unknown for over two thousand years [2-8,32-45], but has been discovered in Lublin, Poland in years 1984-2007 [9-21,23-31]. Because of this we call this deformity now not “Idiopathic Scoliosis”- unknown causes - but “So-Called Idiopathic Scoliosis”. Observation of many patients in years 1984-2007 has enabled the author (T. Karski) to found that etiology of “the so-called idiopathic scoliosis” is connected with biomechanical influences going from hips. It was stated that scoliosis is connected with the asymmetrical movement of hips and next with function - permanent “standing ‘at ease’ on the right leg” and “gait”. A question appears: why “standing ‘at ease’ on the right leg” causes scoliosis? We found that in all scoliosis children limitation of adduction of the right hip, or even abduction contracture of this joint 5 - 10 degree make

easy such standing [9-21,23-31]. Limited movement of the right hip is one of eight symptoms in “Syndrome of Contractures and Deformities” [SofCD] according to Prof. Hans Mau from Tübingen, Germany [34-36] and Lublin observations [8-29]. “The right leg” is not the cause of scoliosis but “cumulative time” of standing on this leg. The straight position in examination of hips movement is similar to the “standing position” or to the “stance phase in walking” of these joints. Alone “standing ‘at ease’ on the right leg is leading to scoliosis in two groups and three types. Standing on the right leg start to be in age of 2-3 years and is permanent in all years of life. In adults is the cause of “degenerative scoliosis” and “spine pain syndromes” (FIG. 8,9a,9b,10). “Standing ‘at ease’ on the right leg” we have occasion to observe not only in patients in Poland but also in many others countries during ours “scholarships studies” or during Congresses or Symposia - for example in Austria, in Germany, in Czech Republic, in Hungary, in Italy, in Finland and in other countries.

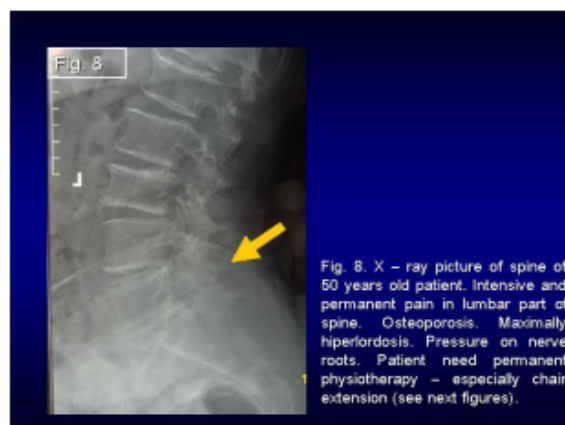


Figure 8: X - ray picture of spine of 50 years old patient. Intensive and permanent pain in lumbar part of spine. Osteoporosis. Maximally hiperlordosis. Pressure on nerve roots. Patient need permanent physiotherapy - especially chair extension (see next figures).

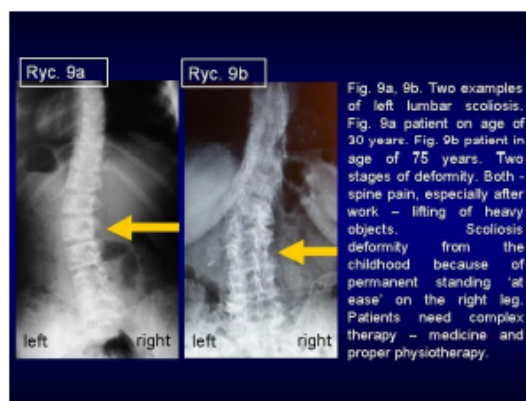


Figure 9a, b: Two examples of left lumbar scoliosis. a) patient on age of 30 years. b) patient in age of 75 years. Two stages of deformity. Both - spine pain, especially after work – lifting of heavy objects. Scoliosis deformity from the childhood because of permanent standing ‘at ease’ on the right leg. Patients need complex therapy - medicine and proper physiotherapy.

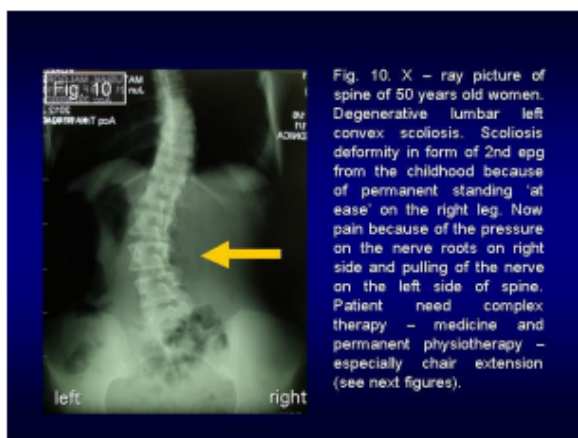


Figure 10: X - ray picture of spine of 70 years old women. Degenerative lumbar left convex scoliosis. Additionally - osteoporosis. Scoliosis deformity from the childhood because of permanent standing 'at ease' on the right leg. Now intensive pain because of the pressure on the nerve roots on right side and pulling of the nerve on the left side of spine. Patient need complex therapy - medicine and permanent physiotherapy - especially chair extension (see next figures).

Short Information About Historical Dates of Discoveries of Biomechanical Etiology of the SoCalled Idiopathic Scoliosis [9-13]

1995 - first lecture about biomechanical causes in etiology of the so-called idiopathic scoliosis, after 11 years of observations. The results of these observation were presented on the Orthopedic Congress in Szeged, Hungary.

1996 - first publication about biomechanical etiology of scoliosis in *Orthopädische Praxis* in Germany [9].

2001 and 2004 - describing in new classification - three etiopathological groups (epg) and four types of scoliosis.

2006 - the ultimate description of the "type of hips adduction movement in straight position of joint" and the "type

of scoliosis" (Figure. 4).

2007 - description of indirect influences coming from Central Nervous System (CNS) in children with Minimal Brain Dysfunction (MBD) in etiology and in progress of scoliosis. In this year (2007) was also given the answer why blind children do not have scoliosis. Answer: they walk without lifting of legs, and as a result there is no pathological influence acting on the pelvis and the spine.

New Classification. Three Groups and Four Types of So-Called Idiopathic Scoliosis (Fig. 1-4) [9-21, 23-31]

The type of spine deformity is connected with "model of hips movement" and etiological factors - "gait" and "standing 'at ease' on the right leg".

1. "S" scoliosis 3D - in 1st etiopathological group (epg). Character of pathology: double curve, stiff spine, rib hump on the right side. In this group and types characteristic is specific model of hip movements: maximally limited adduction movement of the right hip and full movement of the left hip. Development of scoliosis is connected with "gait" and permanent "standing 'at ease' on the right leg". In this type we mostly observe rapid progression. In the Internet, this type of scoliosis is the subject of various descriptions.

2. "C" scoliosis 1D or 2D - in 2nd/A epg. Character of pathology: one lumbar left convex curve, flexible spine. In this group and type, the model of hip movements is characteristic: minimally limited adduction movement of the right hip and full movement of the left hip. Development of scoliosis is connected with permanent standing „at ease' on the right leg. This type of scoliosis is without progression. In adults, this type of scoliosis a very frequent cause of back pain. Why - here I want to repeat - because the standing on the right leg is permanent and is lasts throughout life (Figure. 8,9a,9b,10). After years scoliosis - receive the status "degenerative scoliosis" with heavy back pain symptoms. "S" scoliosis 2D or 3D - in 2nd/B epg. Character of pathology: two curves - lumbar left convex and thoracic right convex, flexible spine. In this group and types characteristic is specific model of hip movements: minimally limited adduction movement of the right hip and full movement of the left hip. Development of scoliosis is connected with permanent standing 'at ease' on the right leg and additionally with laxity of the joints or/and previous harmful therapy. This type of scoliosis is with moderate progression. In older people the standing on the right leg is the cause of degenerative scoliosis and heavy back pain syndrome similar to the type "C" in 2nd epg. (FIG. 10).

3. "I" scoliosis 2D or 3D - in 3rd epg. Character of pathology: deformity has the form of a stiff spine. No curves or small ones. Clinical symptoms of this type of scoliosis are "stiffness of the spine in children" and "pain syndromes in adults". In this group and types characteristic is a specific model of hip movements: maximally limited adduction movement of the right hip and maximally or partially limited movement of the left hip. Development of scoliosis connected with "gait" (FIG. 7). Stiffness of the spine, like in the 1st type of scoliosis, is connected with "distortion movement" of intervertebral joints in every step during walking.

Therapy of Scoliosis (A) and Low Back Pain (B) (Figure. 11,12a,12b)

a. In the therapy of scoliosis on the first plan we put - flexion stretching exercises for hips - especially for right hip and for spine. In therapy it is important to cure the "contracture" - it means - shortenings of soft tissues - muscles, fascias, tendons, capsules of the hip and spine joints. The aim of such therapy is to obtain full movement of hips and spine. Only in situation of full and symmetrical movement of hips and spine development of spine will be proper and fully correct. For this aim the best are exercises like in karate, taekwondo, aikido, kung fu or yoga. In Poland the first who introduced such exercises in the treatment of scoliosis (1960-1970)

was Prof. Stefan Malawski from Warsaw / Otwock [31-33, personal discussions].

b. For patients with back pain we advise the proper activity in job and after work proper resting and sleeping - in every case - in embryo position on the side of the body. In serious cases we recommend the chair extension (FIG. 12a) to relieve the neuro-roots. In pain free period of illness, we recommend exercises in warm water - the best results when the exercises are in geothermal water. In serious cases, longer rest in bed and adequate analgesics. It is important to avoid standing on the right leg by all neurological patients. In many cases standing on the left or in special "therapeutically position" is very beneficial and relieves pain at once (FIG. 12b). Only some rare cases according our observations need surgery.



Figure 11: Stretching sport arts in therapy of scoliosis of children and young persons. The best karate, aikido, kung fu, yoga. Aim - receiving of the symmetry of movement of hips joints, position of pelvis and full movement of spine. Such exercises are the best prophylaxis against back pain in adults age.

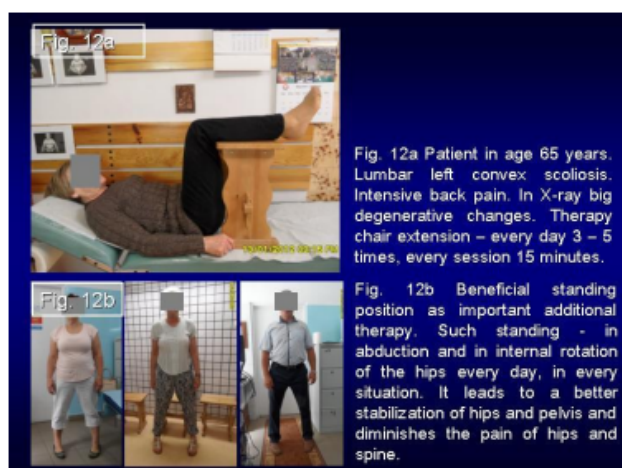


Figure 12a, b: Patient in age 65 years. Lumbar left convex scoliosis. Intensive back pain. In X-ray big degenerative changes. Therapy chair extension - every day 3-5 times, every session 15 minutes. Beneficial standing position as important additional therapy. Such standing - in abduction and in internal rotation of the hips every day, in every

situation. It leads to a better stabilization of hips and pelvis and diminishes the pain of hips and spine.

Causal Prophylaxis and Treatment of Scoliosis in Children and Back Pain in Adults in Points

1. Standing 'at ease' only on the left leg from first years of life.
2. Sitting in a "butterfly position" - term from karate and with relaxed / bend spine - never straight up. Our orthopedic obligation is to advise that such sitting position is very beneficial for hips development in babies and also in older children
3. Resting and sleeping in the embryo position - protects from scoliosis in children and from back pain in adults.
4. Children - active participation in sports at / in school and additionally in clubs - the best are karate, kung fu, taekwondo, aikido and yoga advised for adults.
5. Adults - physiotherapy and Kinesio-therapy to obtain full, symmetrical movement of both hips and movements of the spine - flexion, deviation, rotation.
6. In first period in therapy and prophylaxis of scoliosis is to restore the full adduction and internal rotation movement of the right hip. It is new aim for physiotherapy and very important in causal prophylaxis.
7. For adult patients very important are exercises in geothermal water, "chair extension", resting in embryo position in heavy pain periods of illness and standing in abduction and internal rotation.
8. Adults patients should - change the form of job - if is not proper for spine.
9. Every heavy object the patients shout lift in side of the body - never before / never in front of body.
10. Our recommendation about physiotherapy for adult people suffering because of spine pain are: massage, criotherapy, diadynamic, ionophoresis and other form of physical therapy.
11. In special difficult cases of low back pain - surgery - if long-lasting physiotherapy doesn't give result.

Discussion and Important Messages in Points

In our opinion the back pain syndromes occur in the following cases:

1. Hiperlordosis of lumbar spine.
2. "C" and "S" 2nd group scoliosis in the new classification.
3. Stiffness of the spine - its mean - scoliosis "I" in 3rd group in the new classification.
4. Spondylolisthesis.

Here I would like to explain that the cause of the pain is situated in two - three or four places / levels of the spine. If doctor advise or perform a surgery - the results are never good because the operation do not embrace the whole "pathological section of the pathological spine".

A relief and stabilization on one - two levels during surgery does not cure the "back pain". I repeat - doctors in Poland most often diagnose "prolapsed nucleus pulposus" and propose surgery - results are good only for short period of time, never for longer time. In our

praxis we have observed - that only physiotherapy is good methods in many of patients. We received good results in ca. 30%, excellent in ca. 20% and sufficient in ca. 50% of patients. Only very small group 1%-2% of patients need surgery.

Conclusions

There are three group and four types of the so-called idiopathic scoliosis - see chapter about classification.

The etiology of the so-called idiopathic scoliosis is strict biomechanical - "standing 'at ease' on the right leg" and "gait". Additionally, causes are - symptoms of MBD - laxity of joints, anterior tilt of pelvis and stiffness of spine from childhood period.

The back pain syndromes are mostly connected with the pathological changes in the anatomy of the spine and in its function.

The main causes of back pain, presented in order from very frequent too seldom:

Hiperlordosis of lumbar spine.

The "C" and "S" scoliosis in 2nd / A / B epg types.

Stiffness of the spine in "I" 3rd epg type of scoliosis.

Spondylolisis or spondylolisthesis.

Congenital anomalies of spine or thorax with influence to the spine

Spine anomalies and disorders in various "Congenital Syndromes" like Osteogenesis Imperfecta, Morquio

Syndrome, Marfan Syndrome, Ehlers - Danlos Syndrome, Asphyxiating thoracic dystrophy without respiratory

disease (in Italian: Distrofia thoracica asfissiante senza compromissione respiratoria -publication in Italy – under the direction of Prof. K. Kozłowski) and others [22].

In prophylaxis of back pain in adults it is important to introduce to all children the rules of causal prophylaxis against scoliosis (see chapter above).

6. In therapy of back pain - on the first plan is:

a. To avoid the standing 'at ease' on the right leg.

b. Rest and sleep in embryo position.

c. In heavy cases "chair extension" and in the "pain-free phase of the illness" - exercises in geothermal water.

Surgery in back pain syndromes only in rare cases resistant in/to conservative treatment.

Acknowledgement

I would like to express my many thanks to Miss Honorata Menet for correction of the article.

References

1. Christiansen B, Reimers J (1998). Personal discussion with both Professors during my lecture about etiology of so-called idiopathic scoliosis in Rikshospitalet in Copenhagen, Denmark in 1998. Confirmation of "standing 'at ease' on the right leg" in all children with scoliosis treated in this time in the Rikshospitalet.
2. Burwell G, Dangerfield PH, Lowe T, (2000) Etiology of Adolescent Idiopathic Scoliosis: Current Trends and Relevance to New Treatment Approaches. Hanley & Belfus, Inc, USA; 9:324.
3. Dangerfield PH, Dorgan JC, Scutt D (1995) Stature in Adolescent Idiopathic Scoliosis (AIS). 14 Meeting EPOS, Brussels, Papers and Abstracts 210.
4. Green NE, Griffin PP (1982) Hip dysplasia associated with abduction contracture of the contralateral hip. *J Bone Joint Surg Am.* 64:1273-1281.
5. Gruca A, Tylman D (1995) Pathomechanics of lateral curvatures of the spine. Warsaw: Severus Publishing House 167.
6. Heikkilä E (1984) Congenital dislocation of the hip in Finland. An epidemiologic analysis of 1035 cases. *Acta Orthop Scand.* 55:125-129.
7. Hensinger RN. [1979] Congenital dislocation of the hip. *Clin Symp.* 31:1-31
8. Howorth B. (1997) The etiology of the congenital dislocation of the hip. *Clin Orthop.* 29:164-179.
9. Karski T. (1996) Contractures and growth disorders in the hip and pelvic area in the etiology of the so-called "idiopathic scoliosis" - biomechanical considerations. *Orthop Pract.* 32:155-160.
10. Karski T. (2000) Etiology of the so-called "idiopathic scoliosis". Biomechanical explanation of spine deformity. Two 272 groups of development of scoliosis. New rehabilitation treatment. Possibility of prophylactics, *Studies in 273 Technology and Informatics, Research into Spinal Deformities 4.* Amsterdam, Berlin, Oxford, Tokyo, Washington DC: IOS Press. 91:37-46.