



Differences in the Development of Restenosis Over Time for Various Drug-Eluting Stents

Kosei Tanaga*, Yoshitake Nakamura, Kigen Jo, Toshihisa Inoue, Takayasu Ishikawa and Akira Miyazaki

Abstract

Introduction: Restenosis after stent implantation is one of the major limitations of percutaneous coronary intervention (PCI). Compared to bare metal stents (BMS), drug-eluting stents (DES) have a reduced incidence of restenosis. However, the temporal pattern of restenosis development in patients implanted with DES has not been clearly defined.

Aim: This study aims to compare the efficacy of sirolimus-eluting stents (SES), paclitaxel-eluting stents (PES), zotarolimus-eluting stents (ZES), and everolimus eluting stents (EES) via sequential angiographic follow-up and to reveal the development of restenosis over time.

Material and methods: Patients were randomized to receive SES, PES, ZES, or EES, and follow-up angiography was performed at 6, 12 and 24 months after percutaneous coronary intervention. We analyzed late loss (LL) at each time point and defined 2 time periods: "early" (within first year of follow-up) and "late" (after the first year).

Results: In all groups, mean minimal lumen diameter decreased slightly during the 2-year period after the procedure. Compared with the SES group, the PES and the ZES groups showed significantly greater late loss (LL) within 1 year. However, the SES group showed significantly greater LL compared with the other drug-eluting stents (DES) between 1 and 2 years.

Conclusions: Serial angiographic analysis revealed differences in the rate of restenosis development over time for various DES. Of the studied DES, EES showed the best results in both early and late LL.

Keywords

DES; PCI; Restenosis; Angiography

Introduction

Percutaneous coronary intervention (PCI) is a major treatment modality for patients with ischemic heart disease, and coronary stent implantation is widely performed. However, restenosis after stent implantation is one of the major limitations of PCI. Compared to bare metal stents (BMS), drug-eluting stents (DES) have a reduced incidence of restenosis [1]. The first DES, a sirolimus-eluting stent (SES), reduced the need for repeat revascularization with a similar

safety profile compared with BMS [2]. Although the SES has reduced restenosis after coronary stent implantation, adverse events such as late (i.e., beyond 1 year) symptomatic restenosis emerged as a new problem associated with the use of DES [3-5]. Restenosis after BMS implantation is considered to peak at 6 months, after which further restenotic events are infrequent [6]. However, the temporal pattern of restenosis development in patients implanted with DES has not been clearly defined. Persistent concerns regarding efficacy and long-term safety have led to further developments including novel anti-proliferative drugs with alternative stent platforms and a biocompatible drug carrier system. Therefore, zotarolimus-eluting stents (ZES), and everolimus-eluting stents (EES) were developed as second-generation DES, with hopes of improving efficacy and safety. PCI with EES has been shown to result in better outcomes than SES [7,8].

Aim

The aim of our study is to compare the efficacy of SES, paclitaxel-eluting stents (PES), ZES, and EES via sequential angiographic follow-up and to reveal the development of restenosis over time.

Material and Methods

Study patients

Patients who were referred to our center between April 1, 2010, and March 31, 2011, and underwent elective PCI with DES were selected. Patients older than 18 years with ischemic symptoms or evidence of myocardial ischemia in the presence of >75% *de novo* stenosis located in native coronary vessels were randomized to receive SES (Cypher Select, Cordis Corp Johnson & Johnson Miami, Florida), PES (Taxus Liberte, Boston Scientific, Natick Massachusetts), ZES (Endeavor, Medtronic Vascular, Santa Rosa, California), or EES (XIENCE V, Abbot Vascular, Santa Clara California). Enrollment continued until 30 patients were assigned to each group. Patients with target lesions located in the left main trunk, in-stent restenosis, or bypass graft were excluded. Patients who were planned to receive overlapping stents, complex 2-stent strategies for bifurcation lesions, or rotational atherectomy before stent implantation were also excluded. Enrolled patients who did not undergo 2-year angiographic follow-up due to major clinical events such as target-lesion revascularization (TLR) and target-lesion revascularization (TVR) were excluded from the analysis. All patients received optimal medical therapy, including anti-platelet, anti-ischemic, anti-hypertensive, glycemic control and low-density lipoprotein cholesterol-lowering therapy. All patients provided informed consent for the procedure and follow-up treatment, and the protocol was approved by an institutional review board.

Stent placement and anticoagulant therapy

Procedural success was defined as the use of the stent resulting in <25% stenosis, as measured by using quantitative coronary angiography [2,3]. All patients included in the final analysis were maintained on dual-antiplatelet therapy for the 24 month study period.

*Corresponding author: Kosei Tanaga, Department of Cardiology, Chiba Cardiovascular Center, 575 Tsurumai, Ichihara, Chiba 290-0512, Japan, Tel.: +81 436 88 3111; Fax: +81 436 88 3032; E-mail: t.kosei.5150@m8.dion.ne.jp

Received: October 13, 2015 Accepted: October 28, 2015 Published: November 03, 2015

Angiographic follow-up

Follow-up angiography was performed at 6, 12 and 24 months after PCI in all patients. If a patient developed signs of ischemia, follow-up angiography was performed immediately. We analyzed late loss (LL) at each time point and defined 2 time periods: “early” (within first year of follow-up) and “late” (after the first year) [5].

Quantitative angiographic analysis was performed by using the commercially available CAAS 5.4. Minimal lumen diameter (MLD) and reference vessel diameter were measured immediately after PCI, at routine follow-up examinations, and at the time of detection of restenosis.

Clinical follow-up

Clinical follow-up data were obtained by either a review of the hospital records or telephone interview of the patients or their referring physicians. The major clinical events studied were death, myocardial infarction (MI), thrombosis, TLR, and TVR. The parameter death included death due to any cause. MI was defined as an increase in serum creatine kinase level to more than twice the normal value, in association with new pathological Q waves.

TLR and TVR

TLR was defined as an intervention repeated to control luminal stenosis within the stent or in the 5 mm proximal or distal segments adjacent to the stent. TLR was performed if follow-up angiography showed >75% stenosis of the vessel diameter with objective evidence of myocardial ischemia. TVR was defined as a clinically driven PCI or bypass of the stented lesion or any segment of the epicardial coronary artery containing the stented lesion.

Statistical analysis

Data are summarized as mean \pm SD. Repeat variance ANOVA was used to evaluate differences among groups. P values < 0.05 were considered statistically significant. All statistical analyses were performed by using SAS software (JMP version 5.1).

Results

Clinical outcomes

The baseline clinical characteristics of the patients and the coronary lesions are shown in Table 1. All stents were successfully implanted in all the patients. Clinical outcomes at the 2-year follow-up are shown in Table 2. Five patients in the SES group, 4 patients in the PES group, 6 patients in the ZES group, and 4 patients in the EES group developed major clinical events within the 2-year follow-up period and were excluded from the analysis.

Quantitative coronary angiographic analysis

We assessed serial changes in the MLD and results are shown in Figure 1A (-SES), 1B (-PES), 1C (-ZES), and 1D (-EES). In all DES groups, mean MLD slightly decreased during the 2-year period after the procedure, and MLD did not improve, as has been reported with BMS [6]. We divided LL into 2 groups, those documented within the first year of follow-up (early) and those documented after the first year (late). Figure 2 shows LL over the entire 2 years. Compared with the SES group, the PES and the ZES groups showed significantly greater LL, however, there was no significant difference between the SES group and the EES groups. Figure 3 shows early LL; between after procedure and 1 year. Compared with the SES group, the PES

and the ZES groups also showed significantly greater LL. There was no significant difference between the SES group and the EES group. Figure 4 shows late LL; between 1 year and 2 years. The SES group showed significantly greater LL compared with the other DES groups.

Discussion

SES has been shown to be more effective than PES in most studies with angiographic follow-up to 1 year [9,10]. However, 5-year follow-up of SES and PES showed no significant differences in angiographic outcomes [11]. SES appears to lose the intimal advantage over PES in suppression of neointimal hyperplasia. The same is true for ZES. Compared with SES, treatment with ZES is associated with significantly greater late lumen loss and binary restenosis at 8-month angiographic follow-up [12]. Despite initially greater angiographic late lumen loss, events including all-cause mortality and the composite event rate of MACE were significantly less common among patients treated with ZES [12]. Our study showed that early LL is significantly less in patients implanted with SES than in patients implanted with PES or ZES. However, LL after 1 year was significantly greater in patients implanted with SES than in patients implanted with PES or ZES. The time course of LL that we showed explains the loss of advantage in patients implanted with SES.

Restenosis is the healing response of the arterial wall to mechanical injury [13]. This time course of arterial healing in the lesions implanted DES contrasts with the pattern of neointimal formation after BMS placement, which typically peaks at 6 to 12 months with regression. The SES implantation site shows a significant delay in arterial healing and poor endothelialization characterized by persistent

Table 1: Base- line characteristics of the patients and lesions.

	SES (N=30)	PES (N=30)	ZES (N=30)	EES (N=30)	P
Mean (\pm SD) age-yr	66.7 \pm 11.3	66.2 \pm 9.2	68.2 \pm 10.6	67.6 \pm 9.0	NS
Sex-M/F	23/7	25/5	24/6	25/5	NS
Diabetes mellitus-no	9	12	7	12	NS
Hypertension	17	19	18	13	NS
Hyperlipidemia	14	13	17	16	NS
Lesions Artery affected –no					
Left anterior descending corona	16	14	13	12	NS
Circumflex coronary	4	9	6	9	NS
Right coronary	10	7	11	9	NS
ACC/AHA lesion classification					
A	7	7	8	6	NS
B1	8	11	11	14	NS
B2	9	7	8	6	NS
C	6	5	3	4	NS
Mean stent length per lesion (mm)	22.3 \pm 3.8	21.3 \pm 5.6	20.1 \pm 4.9	20.85 \pm 5.5	NS
Mean stent diameter (mm)	2.89 \pm 0.38	2.94 \pm 0.35	3.01 \pm 0.34	2.9 \pm 0.31	NS

Table 2: Clinical events studied during 2-year follow-up.

	SES (N=30)	PES (N=30)	ZES (N=30)	EES (N=30)	P
Death	2	0	1	2	NS
Myocardial infarction	0	0	1	1	NS
Thrombosis	0	0	1	1	NS
TLR	2	3	4	1	NS
TVR	3	4	4	2	NS
Final Analysis	25	26	24	26	NS

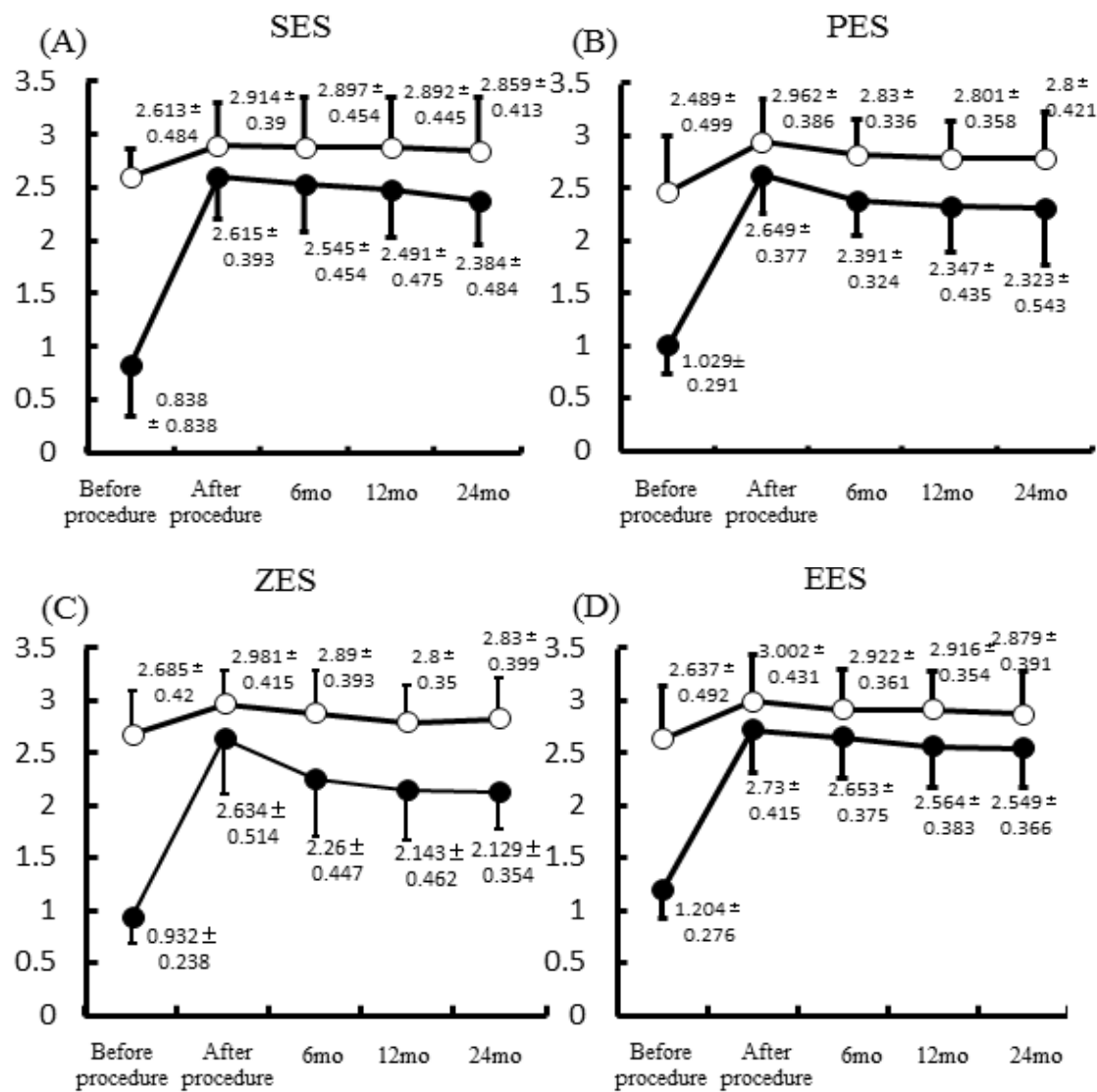


Figure 1: Serial changes in the MLD (Minimal lumen diameter).

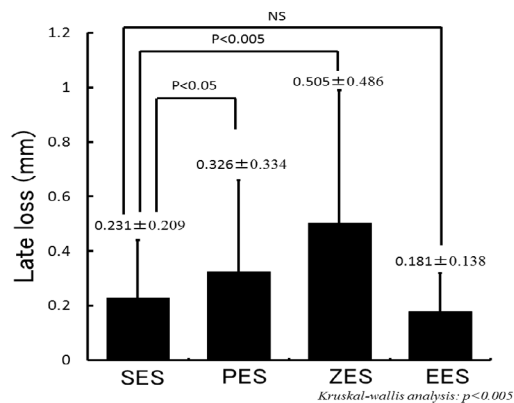


Figure 2: LL (late loss) over entire 2 years.

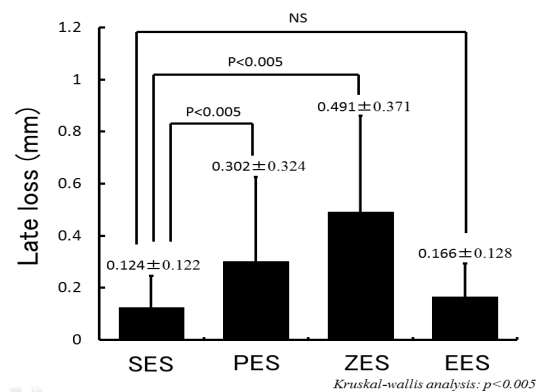
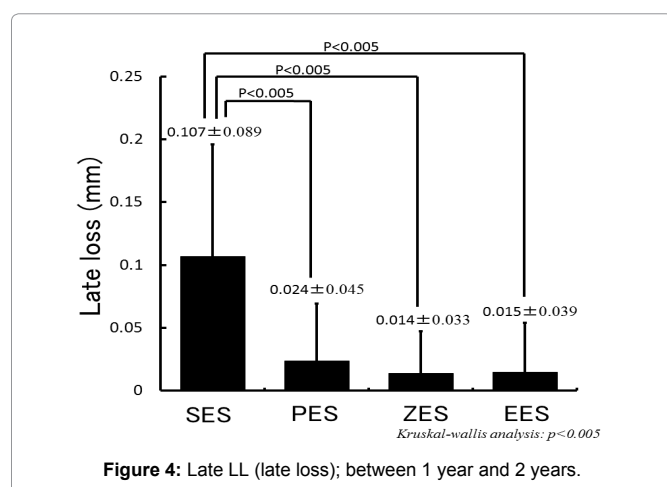


Figure 3: Early LL (late loss); between after procedure and 1 year.



fibrin deposition and inflammation, as compared to the sites of BMS implantation [14-16]. Furthermore, in patients with SES, there was greater inflammation involving eosinophils, lymphocytes, and giant cells compared with PES [16,17]. Inflammatory cell infiltration is identified as a milestone in the temporal sequence of restenosis and greater intimal inflammation was found to be an independent predictor of restenosis [16-18]. SES is coated with a durable polymeric coating, which may induce an inflammatory response, and this response may cause persistent inflammation, which can lead to late progression of neointimal formation. Durable polymers are also used in ZES (phosphorylcholine) and EES (vinylidene fluoride and hexafluoropropylene), but these polymers are more biocompatible and designed to induce less inflammatory reactions in vivo [8,12]. More biocompatible polymers may reduce the inflammation and decrease late LL. However, mean MLD slightly decreased up to 2 years after the procedure, and improvement of MLD, which has been observed in patients implanted with BMS, was not observed. Even DES with biocompatible polymers may not fully suppress inflammatory responses. EES and ZES are made of cobalt chromium, as opposed to stainless steel (PES and SES), which allows comparative radial strength to be achieved with considerably thinner stent struts. This can also reduce vascular injury, inflammatory reactions and the risk of restenosis. Although late LL after 1 year in patients implanted with ZES was less than patients implanted with SES, early LL was greater in patients implanted with ZES. These may be related to the relatively faster drug release in ZES compared to SES and EES [12].

Conclusions

Serial angiographic analysis revealed differences in the rate of restenosis development over time for various DES. DES is comprised of many components (metallic platform, alloy, drug and polymer), the progression of LL can be complex and affected by different factors. Of the studied DES, EES showed the best results in both early and late LL.

Study limitations

This study has several limitations. First, this study analyzed patients from a single center. Second, although a well-validated system of quantitative coronary angiography was used, the analysis was not performed in a core laboratory.

References

- Moses JW, Leon MB, Popma JJ, Fitzgerald PJ, Holmes DR, et al. (2003) Sirolimus-eluting stents versus standard stents in the patients with stenosis in a native coronary artery. *N Eng J Med* 349: 1315-1323.

- Caixeta A, Leon MB, Lansky AJ, Nikolsky E, Aoki J, et al. (2009) 5-year clinical outcomes after sirolimus-eluting stent implantation. *J Am Coll Cardiol* 54: 894-902.
- Tanaga K, Miura K, Kageyama T, Nakamura Y, Inoue T, et al. (2011) Restenosis after implantation of sirolimus-eluting stent begins suddenly, shows short term progression, and stops suddenly. *J Cardiol* 58: 26-31.
- Kimura T, Morimoto T, Nakagawa Y, Kawai K, Miyazaki S, et al. (2012) Very late stent thrombosis and late target lesion revascularization after sirolimus-eluting stent implantation: five-year outcome of the j-Cypher registry. *Circulation* 125: 584-591.
- Cosgrave J, Corbett SJ, Melzi G, Babic R, Biondi-Zoccai GG et al. (2007) Late restenosis following sirolimus-eluting stent implantation. *Am J Cardiol* 100: 41-44.
- Kimura T, Yokoi H, Nakagawa Y, Tamura T, Kaburagi S, et al. (1996) Three year follow up after implantation of metallic coronary artery stents. *N Eng J Med* 334: 561-566.
- Dai K, Ishihara M, Inoue I, Kawagoe T, Shimatani Y, et al. (2013) Coronary angioscopic findings 9 months after everolimus-eluting stent implantation compared with sirolimus-eluting stents. *J Cardiol* 61: 22-30.
- Kimura T, Morimoto T, Natsuaki M, Shiomi H, Igarashi K, et al. (2012) Comparison of Everolimus-Eluting and Sirolimus-Eluting Coronary Stents: 1-Year outcomes from Randomized Evaluation of Sirolimus-Eluting Versus Everolimus-Eluting Stent Trial (RESET). *Circulation* 126: 1225-1236.
- Morice MC, Colombo A, Meier B, Serruys P, Tamburino C, et al. (2006) Sirolimus- vs paclitaxel-eluting stents in de novo coronary artery lesions: the REALITY trial. *JAMA* 295: 895-904.
- Räber L, Wohlwend L, Wigger M, Togni M, Wandel S, et al. (2011) Five-year clinical and angiographic outcomes of a randomized comparison of sirolimus-eluting and paclitaxel-eluting stents. *Circulation* 123: 2819-2828.
- Suh JW, Park JS, Cho HJ, Kim MS, Kang HJ, et al. (2007) Sirolimus-eluting stent showed better one-year outcomes than paclitaxel-eluting stent in a real life setting of coronary intervention in Koreans. *Int J Cardiol* 117: 31-36.
- Kandzari DE, Mauri L, Popma JJ, Turco MA, Gurbel PA, et al. (2011) Late-term clinical outcomes with zotarolimus- and sirolimus-eluting stents. 5-year follow-up of the ENDEAVOR III (A Randomized Controlled Trial of the Medtronic Endeavor Drug [ABT-578] Eluting Coronary Stent System Versus the Cypher Sirolimus-Eluting Coronary Stent System in De Novo Native Coronary Artery Lesions). *J Am Coll Cardiol Interv* 4:543-550.
- Costa MA, Simon DI (2005) Molecular basis of restenosis and drug-eluting stents. *Circulation* 111: 2257-2273.
- Joner M, Finn AV, Farb A, Mont EK, Kolodgie FD et al. (2006) Pathology of drug-eluting stents in humans: delayed healing and late thrombotic risk. *J Am Coll Cardiol* 48: 193-202.
- Murakami D, Takano M, Yamamoto M, Inami S, Ohba T, et al. (2009) Novel neointimal formation over sirolimus-eluting stents identified by coronary angioscopy and optical coherence tomography. *J Cardiol* 53: 311-313.
- Finn AV, Nakazawa G, Joner M, Kolodgie FD, Mont EK, et al. (2007) Vascular Response to Drug eluting Stents: Importance of delayed healing. *Arterioscler Thromb Vasc Biol* 27: 1500-1510.
- Nakazawa G, Finn AV, Vorpahl M, Ladich ER, Kolodgie FD, et al. (2011) Coronary response and differential mechanisms of late stent thrombosis attributed to first generation sirolimus- and paclitaxel-eluting stents. *J Am Coll Cardiol* 57: 390-398.
- Finn AV, Kolodgie FD, Harnek J, Guerrero LJ, Acampado E, et al. (2005) Differential response of delayed healing and persistent inflammation at sites of overlapping sirolimus or paclitaxel-eluting stent. *Circulation* 112: 270-278.

Author Affiliations

Department of Cardiology, Chiba Cardiovascular Center, 575 Tsurumai, Ichihara, Chiba 290-0512, Japan

Top