



Case Report

Distinct Radioanatomic Features and Treatments for Spinal Epidural Arteriovenous Fistulae

Miyachi S¹, Mtsuo N¹, Kawaguchi R¹, Takayasu M¹, Izumi T², Matsubara N³, Ohnishi H³ and Hiramatsu R³

Abstract

Spinal epidural arteriovenous fistula (SEDAVF) is a novel clinical entity that is distinct from spinal dural arteriovenous fistula, although both diseases manifest as venous congestive myelopathy. We reviewed nine cases of SEDAVF to elucidate its pathogenesis and radioanatomic features and to optimize treatment strategy. All cases exhibited similar angioarchitecture, with a single shunt at the epidural venous plexus that drains into the intradural perimedullary vein and connects to the ventral spinal vein. Interestingly, all lesions were located on the ventral side of the lower lumbar and sacral region, and shunts were located ventrally in association with the epidural pouch suspected to be isolated as extradural venous lake. This may be the result of the specificity of the feeding artery and a congenital shift in the distribution of the venous drainage system at the terminal film and conus. We explored two options for the treatment for SEDAVF: endovascular transarterial embolization and surgical shunt interruption. Among our patients, three were treated using the endovascular approach and six were treated with surgery. While both treatments were effective at improving symptoms, the delay between disease onset and diagnosis precluded a complete cure. Early diagnosis and adequate treatment based on precise knowledge of the angioarchitecture and pathogenesis of SEDAVF is essential for improved outcomes.

Keywords

Spinal epidural arteriovenous malformation; Myelopathy; Angioarchitecture; Treatment; Embolization

Abbreviations

BBD: Bowel-Bladder Dysfunction; E: Endovascular Transarterial Embolization; S: Surgical Interruption Of The Shunt Evaluation Of Neurological Dysfunction; (Motor Dysfunction And BBD Was Based On The Aminoff-Logue Disability Scale); +++: Severe; ++: Moderate; +: Mild

Introduction

Spinal epidural arteriovenous fistula (SEDAVF) is a novel category of spinal arteriovenous shunt disease. Its clinical symptoms are similar to those of spinal dural AVF (SDAVF) resulting from congestive myelopathy, resulting in the frequent misdiagnosis of these diseases. Recent reports have revealed differences between these two disorders

[1-5]. Typical and classical SDAVF is characterized by a single shunt on the dura at the penetration site of the emissary vein (EV) that drains into the spinal vein (SV). In contrast, SEDAVF is characterized by a single shunt at the epidural venous plexus that drains into the intradural perimedullary vein and connects to the spinal vein at the upper level. Here, we review several cases of SEDAVF to clarify its pathogenesis and radioanatomic features and discuss treatment strategies.

Materials and Methods

We treated 9 patients diagnosed with SEDAVF between 2007 to 2016 at Nagoya University, Osaka Medical College and Aichi Medical University hospitals. Cases of perimedullary AVF and paravertebral AVF were excluded. Patients with SDAVF were excluded based on meticulous radioanatomical study. The shunt point was defined by preoperative selective spinal angiography. In cases treated surgically, the diagnosis was confirmed in the surgical field.

Patients were treated with surgery or using an endovascular approach. Surgeries were performed in a hybrid operation room using angiography equipment. First, spinal angiography for the impaired artery was performed to confirm the target. Patients underwent laminectomy and microsurgical intradural interruption of the shunting vein by clip and/or coagulation while being monitored for somatosensory-evoked and motor-evoked potentials as well as using the ICG dyeing method. Complete obliteration of the shunt was confirmed via intraoperative selective angiography. Endovascular treatment was performed in the angiography room. After conventional spinal angiogram, a microcatheter was inserted into a feeder and advanced as close as possible to the shunt. A dilute n-butyl 2-cyanoacrylate (NBCA) mixture containing lipiodol was injected to penetrate the shunt point.

Results

Patients included six males and three females ranging in age from 49 to 84 years (mean age, 67.8 years). All patients presented with progressive myelopathy due to spinal congestion, including various degrees of paraparesis, monoparesis of the lower limb, sensory disturbance, and bowel/bladder dysfunction (Table 1). The degree of severity of these symptoms was evaluated based on the Aminoff-Logue Disability Scale [6]. The metameric level of the manifesting neurological symptoms largely corresponded to the extent of pathological change in cord swelling and hyperintensity determined by MRI T2-weighted imaging. The shunt point was located in the lumbar region in seven patients (L1: 1; L2: 1; L3: 3; and L4: 4) and in the sacral region in two patients. Four of the lumbar lesions were located on the left side. Eight of nine lesions were associated with the extradural pouch on the ventral side. Shunt flow penetrated the dura primarily at the ventral nerve root and drained into an abnormally expanded radiculomedullary/ perimedullary vein, then flowed upward on a ventral course and connected with the spinal venous system at the conus level. Six patients underwent direct surgical obliteration, and three received endovascular treatment. All shunts except one who underwent incomplete occlusion with failed embolization were successfully occluded. The symptoms improved to various degrees in seven patients; one patient experienced persistent deficits even after successful surgical obliteration.

*Corresponding author: Dr. Shigeru Miyachi, M.D., Ph.D., Neuroendovascular Therapy Center, Aichi Medical University, 1-1, Yazakokarimata, Nagakute, 480-1195 Aichi, Japan, Tel: +81-561-62-3311; Fax +81-561-63-2879; E-mail: neu137@osaka-med.ac.jp

Received: May 27, 2017 Accepted: June 07, 2017 Published: June 15, 2017

Table 1: Patient summary.

Case No.	age	gender	laterality	shunt level	Neurological Dysfunction			treatment	posope. clinical state
					motor	sensory	BBD		
1	84	M	L	L2	+++	++	++	E	improvement
2	65	M	R	L3	++	++	++	E	improvement
3	65	M	R	L4	++	++	+++	E	improvement
4	49	F	L	L1	+++	+++	+++	S	improvement
5	73	M	R	L3	+	+++	+++	S	improvement
6	69	M	L	L4	++	++	++	S	improvement
7	70	M	L	L3	+++	+++	+++	S	no change
8	68	F	R	sac	+++	++	+++	S	improvement
9	67	F	L	sac	++	++	+++	S	improvement

Representative Cases

Case 1

An 84-year-old male suffered from a progressive gait disturbance that was diagnosed as lumbar canal stenosis. He could not stand unaided and presented paraparesis and dysesthesia of the lower limbs and severe bowel-bladder dysfunction. A spinal angiogram revealed an abnormal shunt at the level of left second lumbar artery. The radicular artery formed a pouch on the ventral side, and the shunt flow was directed through the abnormally developed perimedullary vein that was refluxed to the spinal veins at level T12. We navigated the microcatheter to the shunt point and injected a 33% NBCA mixture. Embolic material penetrated into the pouch and the intradural venous system. Postembolization angiogram indicated complete occlusion of the shunt. Marked improvement of the neurological symptoms was observed postoperatively, and the patient regained the ability to walk with a cane (Figure 1).

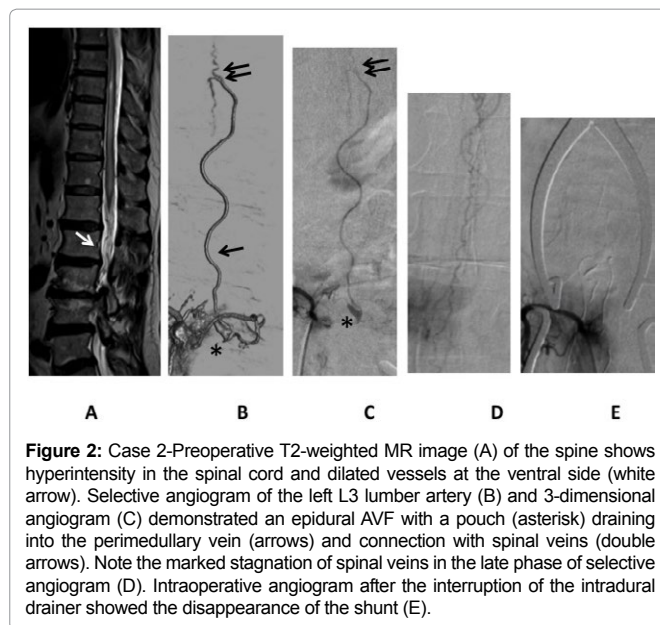
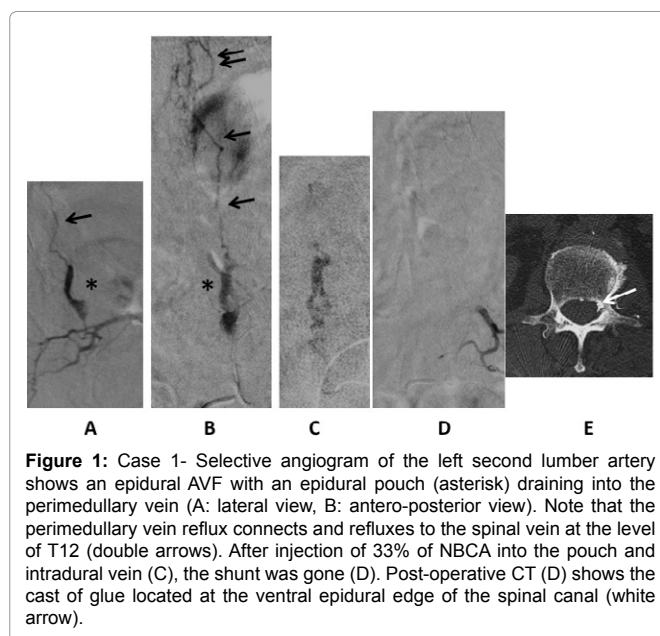
Case 5

A 73-year-old male presented with a mild gait disturbance accompanied by strong hypalgesia of both legs with urinary incontinence. Angiogram demonstrated a single shunt fed by the branch of the radicular artery at the right third lumbar artery that connected to the perimedullary vein via a small extradural pouch on the ventral side. Upward perimedullary veins were connected and refluxed to the ventral spinal veins. After surgical interruption of the intradural entry of the drain, the patient's sensory disturbance was much improved (Figure 2).

Discussion

SEDAVF is a rare clinical entity among spinal arteriovenous shunt diseases, accounting for approximately 1.6% of all spinal arteriovenous malformations (AVMs) [7]. The clinical characteristics of SEAVF are highly similar to those of patients with SDAVF in terms of age at diagnosis, clinical manifestation, and MRI findings. Thus, diagnosis of SEAVF is very difficult and occasionally takes a long time to obtain the precise diagnosis.

The formation and progression of DAVF have been subject to much speculation. We support the hypothesis that over time, the external drainage routes at the initial shunt point occlude the emissary vein and venous sinus [8]. The resultant hemodynamic change leads to increasingly aggressive reflux into the cortical veins. As in cases of SDAVF, when the emissary vein is spontaneously occluded, the AV shunt begins to reflux into spinal veins, resulting in marked venous congestion. It is reasonable to conclude that SEDAVF progresses along a similar path. Rangel-Castilla et al. identified three types of SEDAVF:



Type A, a SEAVF characterized by intradural refluxed drainage; and Types B1 and B2, which are SEAVFs characterized by a mass effect on

the thecal sac and/or nerve roots, and SEAVFs in which no mass effect is observed [9]. According to this classification, SEDAVF may progress in stages to Type B2, then Type B1, and finally Type A. Clinical manifestations of SEAVF with neurological symptoms are typically Type A; all the patients in our series were classified as Type A.

SEDAVFs typically drain on the ventral side through a single radiculomedullary/perimedullary vein then causes reflux into the spinal veins. This pattern differs from that of SDAVF, which mainly refluxes to the posterior spinal veins through a direct connection. One of the causes of this distinction is the location of the feeder. Kiyosue et al. noted that the main feeder of SEDAVF is the dorsal somatic branch, which is located on the ventral side [5]. Furthermore, the large ventral emissary vein is mainly located at L2, where venous networks at the terminal film well typically develop on the ventral side and are rarely present dorsally [10].

Another characteristic that may be unique to SEDAVF is pouch formation at the extradural venous plexus. In these cases, the pouch might originally have served as a centrifugal drainage pathway but gradually occluded to form an isolated lake, as in cases of aggressive intracranial DAVF. The angioanatomic structure of the pouch and its maturation process correspond to the ventral type of DAVF at the cavernous sinus and anterior condylar confluence, based on the craniospinal epidural venous classification system [11,12]. The external venous plexus exists in the space between the dorsal vertebra and ventral dura matter but rarely extends laterally and dorsally, and its position may correlate with the ventral location of SEDAVF. However, the connection between the pouch and the intradural perimedullary veins is not always via the radicular vein but the rather per the dura, according to surgical data obtained for our series of patients. The pathological significance of these lacunar spaces and the mechanism of their formation and connection to the intradural venous system are complicated and remain controversial [13].

Previous studies of SEDAVF have included both congenital and acquired lesions [5,7,10]. It has been determined conclusively that paravertebral invasive AVF is located extradurally and drains to the external venous system, including the paravertebral venous plexus or azygos veins. However, these osseous or osseolytic high flow fistulae are often located in the cervico-thoracic area or exhibit a multi-metameric distribution, as in cases of neurofibromatosis type I or Cobb's syndrome. These are completely congenital and genetic vascular disorders and as such should be differentiated from the cases of acquired developing SEDAVF that are the focus of this article.

SEDAVFs occasionally require rapid treatment when they are highly progressive and result in profound neurological deterioration. The goal of such treatment is to reliably occlude the shunt point or to drain the intradural space. For the treatment of SEDAVF, there are two useful options: a surgical and an endovascular approach. In our series, one case was treated with glue embolization, which failed to occlude the shunt completely. Fortunately, the decrease of shunt flow yielded a sufficient improvement in neurosurgical symptoms, although recurrence is highly likely. Previous reports have described the usefulness of endovascular embolization using liquid embolic materials [3,5,14]. Another report has recommended minimum invasive surgical treatment [15]. From a technical point of view, pinpoint and radical occlusion at the entry to the intradural drain is easier to achieve via surgical interruption than endovascular

embolization because the glue used for embolization sometimes stops in the proximal feeder and fails to reach the shunt point. We therefore first attempt endovascular treatment as a less invasive therapy, and follow up with radical surgery in cases of failure.

Conclusion

SEDAVF exhibits peculiar radioanatomic features that differ from SDAVF, despite the similar clinical manifestations of the disorders. Most patients with SEDAVF in our series suffered from long-term progressive neurological symptoms due to misdiagnosis or the failure of the final diagnosis. SEDAVF is a radiologically treatable disease, although the rate of complete recovery is not high. Early diagnosis and adequate treatment based on a precise understanding of the angioarchitecture and pathogenesis of SEDAVF is essential for improving patient outcomes.

Conflict of Interest

There is no conflict of interest for this paper in all authors.

References

1. Silva N, Januel AC, Tall P, Cognard C (2007) Spinal epidural arteriovenous fistulas associated with progressive myelopathy. *J Neurosurg Spine* 6: 552-558.
2. Krings T, Mull M, Bostroem A, Otto J, Hans FJ, et al. (2006) Spinal epidural arteriovenous fistula with perimedullary drainage. Case report and pathomechanical considerations. *J Neurosurg Spine* 5: 353-358.
3. Nasr DM, Brinjikji W, Clarke MJ, Lanzino G (2017) Clinical presentation and treatment outcomes of spinal epidural arteriovenous fistulas. *J Neurosurg Spine* 26: 613-620.
4. Burkhardt JK, Safaee MM, Clark AJ, Lawton MT (2017) Sacral epidural arteriovenous fistulas: imitators of spinal dural arteriovenous fistulas with different pathologic anatomy: report of three cases and review of the literature. *Acta Neurochir* 159: 1087-1092.
5. Kiyosue H, Tanoue S, Okahara M, Hori Y, Kashiwagi J, et al. (2013) Spinal ventral epidural arteriovenous fistulas of the lumbar spine: angioarchitecture and endovascular treatment. *Neuroradiology* 55: 327-336.
6. Aminoff MJ, Logue V (1974) The prognosis of patients with spinal vascular malformations. *Brain* 97: 211-218.
7. Willinsky R, terBrugge K, Montanera W, Wallace MC, Gentili F (1993) Spinal epidural arteriovenous fistulas: arterial and venous approaches to embolization. *Am J Neuroradiol* 14: 812-817.
8. Miyachi S, Izumi T, Matsubara N, Naito T, Haraguchi K, et al. (2011) Mechanism of the formation of dural arteriovenous fistula: the role of the emissary vein. *Interv Neuroradiol* 17: 195-202.
9. Rangel-Castilla L, Holman PJ, Krishna C, Trask TW, Klucznik RP, et al. (2011) Spinal extradural arteriovenous fistulas: a clinical and radiological description of different types and their novel treatment with Onyx. *J Neurosurg Spine* 15: 541-549.
10. Lasjaunias P, Berenstein A, Terbrugge K (2005) Spinal cord veins; Surgical Neuroangiography. Springer Verlag, Berlin.
11. Geibprasert S, Pereira V, Krings T, Jiarakongmun P, Toulgoat F, et al. (2008) Dural arteriovenous shunts: a new classification of craniospinal epidural venous anatomical bases and clinical correlations. *Stroke* 39: 2783-2794.
12. Satomi J, Satoh K, Matsubara S, Nakajima N, Nagahiro S (2005) Angiographic changes in venous drainage of cavernous sinus dural arteriovenous fistulae after palliative transarterial embolization or observational management: a proposed stage classification. *Neurosurgery* 56: 494-502.
13. Thron A, Krings T, Otto J, Mull M, Schroeder JM (2015) The Transdural Course of Radicular Spinal Cord Veins--A Microangiographical and Microscopical Study. *Clin Neuroradiol* 25: 361-369.

14. Brinjikji W, Yin R, Nasr DM, Lanzino G. (2016) Spinal epidural arteriovenous fistulas. *J Neurointerv Surg* 2015: 012181.
15. Najjar A, Zairi F, Sunna T, Weil A, Estrade L, et al. (2016) Minimally invasive approach for the treatment of lumbar epidural arteriovenous fistulas with intradural venous reflux. *Neurochirurgie* 62: 258-262.

Author Affiliation

[Top](#)

¹Department of Neurosurgery and Neuroendovascular Therapy, Aichi Medical University, Yazakokarimata, Nagakute, Aichi, Japan

²Department of Neurosurgery, Nagoya University Graduate School of Medicine, Aichi, Japan

³Department of Neurosurgery and Endovascular Neurosurgery, Osaka Medical College, Osaka, Japan

Submit your next manuscript and get advantages of SciTechnol submissions

- ❖ 80 Journals
- ❖ 21 Day rapid review process
- ❖ 3000 Editorial team
- ❖ 5 Million readers
- ❖ More than 5000 
- ❖ Quality and quick review processing through Editorial Manager System

Submit your next manuscript at • www.scitechnol.com/submission