

Endometriosis as a cause for acute appendicitis in pregnancy

Kenneth Lam

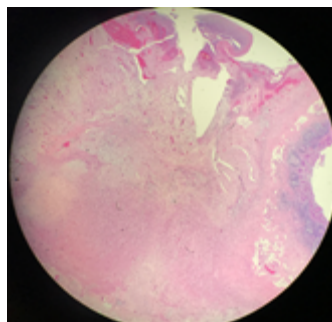
Monash Medical Centre, Australia



Abstract

A 30-year-old female at 26-weeks gestational age presented to hospital with right iliac fossa abdominal pain. Her Inflammatory markers were slightly raised and on ultrasound investigation the appendix could not be visualised. A magnetic resonance imaging (MRI) scan of the abdomen and pelvis showed a distended tubular blind structure with a suspected appendicolith. A laparoscopic appendicectomy was performed and histologic examination of the specimen confirmed appendicitis with serosaldecidual maturation consistent with endometriosis. During pregnancy, endometrial lesions undergo decidualisation under the influence of hormones like progesterone. Decidualisation involves endometrial glandular hyperplasia. This histologic phenomenon can invade underlying structures like bowel. Additionally, lesions become more vascular and oedematous, resulting in inflammation and underlying tissue dysfunction. Early identification of acute appendicitis in pregnant women is crucial to avoid progression to complicated appendicitis. Acute appendicitis in pregnancy secondary to endometriosis is rare. The prevalence of appendiceal endometriosis is 2.8% in people with known endometriosis and 0.4% in the general population.

Figure 1: Histology Slide (haematoxylin and eosin stain): The appendix mucosa exhibits focal areas of ulceration with localised inflammatory exudation into the lumen. The serosal surface is covered by a fibrin cellular neutrophilic exudate associated with extensive decidual maturation.



Biography

Kenneth Lam completed his Bachelor of Medicine and Bachelor of Surgery (MBBS) in 2016 from Bond University, QLD, Australia. He then completed as Master of Surgery in 2020 from the University of Sydney, NSW, Australia. He is currently a General Surgery registrar at Monash Medical Centre, Victoria, Australia. He has published more than 10 papers in reputed journals.



9th International Conference on Clinical Case Reports | May 07, 2021

Citation: Kenneth Lam, Endometriosis as a cause for acute appendicitis in pregnancy, Clinical Case Reports 2021, 9th International Conference on Clinical Case Reports| May 7th 2021, 07