



## Endonasal Tongue in Groove Septoplasty

Heba Mahmoud<sup>1</sup>, Medhat Tiba<sup>1</sup>, Anas Askora<sup>1</sup>, Mohammad Salah Mahmoud<sup>1</sup>

### Abstract

Caudal or anterior nasal septum deviations, despite not being the most common type of septal deviation, cause much complaint as well as cosmetic deformity to the nasal tip. Deflections of the caudal end of the nasal septum are often not addressed at the time of septoplasty by simple submucosal resection of midportion of bony and /or cartilaginous septum for fear of disrupting the caudal strut making its ability to treat the functional and aesthetic complications of many septal deviations limited. No single method of correction has been shown to be effective in all cases. Most caudal septal reconstruction maneuvers are more easily accessible by way of an external approach. One of the most popular techniques is the "tongue-in-groove" which has been reported to improve projection and rotation.

**The aim of this study:** To test the effectiveness of using the tongue in groove technique endonasally to correct nasal septum caudal deviations.

**MATERIALS AND METHODS:** the study included 137 patients with nasal obstruction for not less than one year due to caudal septal deviation with or without inferior nasal turbinates hypertrophy including revision cases. Patients with medical and/or surgical sinonasal pathologies were excluded. The patients were then submitted to surgery using endonasal "tongue-in-groove" correction technique.

**Results:** Our results show that there was no cosmetic change in relation to nasal tip support after the proposed surgical correction.

**CONCLUSION:** The results from this study indicate subjectively, through patient satisfaction and pre and post operative photographing that using endonasal "tongue-in-groove" technique for correction of caudal septal deviation seems to be efficient.

### Introduction

In general, the aetiology of a deviated septum is congenital, but can also be due to trauma or iatrogenic causes. As it results in functional or cosmetic morbidity a bent or deviated nasal septum becomes clinically important.

Maybe the most common procedure for treating chronic nasal obstruction is septoplasty, with or without turbinate reduction. submucosal resection of midseptum bone or cartilaginous deviations is a technically undemanding and quite effective procedure. Due to the fear of losing the caudal strut, deflections of the caudal end of the nasal septum are often not approached at primary septoplasty. By

avoiding caudal strut, the ability of the surgeons to treat the functional and aesthetic complications of several septal deviations is limited. 1

Although not the most common form, caudal or anterior nasal septum variations cause much complaint to the nasal tip, both obstructive and cosmetic. Guyuron et al . reported that only 5 percent of these patients had caudal deviations in a series of 1224 septal operations, Sedwick et al . found deviations in this zone in 8 percent of 2,043 cases assessed.

2,3

The technique of tongue-in groove (TIG), first described by Rethi in 1934, has been commonly used in the treatment of various nasal deformities.4 This technique involves repositioning the medial crurae onto the caudal septum cephalically, and can be used in both endonasal and open rhinoplasty. Established originally for the treatment of an elongated nose, Progress with the technique has now been reported for treating alar-columellar disharmony, as well as improving tip rotation and projection 5

Also minor anterior deviations cause impressive nasal obstruction since it is situated precisely at the narrowest part of the nasal cavity; the nasal valve. Studies performed by Grymer et al. have used pre- and post-operative acoustic rhinometry tests to prove that the effect of nasal obstruction caused by small anterior nasal septum deviations is much greater than that caused by substantial posterior septal deviations. 6 In their study of long-term patient satisfaction after septoplasty, patients with caudal dislocation gained more from surgical correction than cases with posterior deviation according to Dinis et al..7

In addition to the functional problems, anterior deviations in the septum also cause evident cosmetic defects. These alter the relationship between the columella and the nostrils, causing significant defects in the position of the nasal tip and symmetry3.

So numerous techniques were used to correct caudal nasal septum deviations. Since Metzenbaum 8 presented his caudal septoplasty technique in 1929, known as "swinging door", many other authors have developed different ways to address these caudal deviations. A popular method was named the "tongue-in-groove maneuver" by Kridel9 and colleagues in 1999; this offers a midline fixation technique and helps to reduce the need for caudal septal trimming.

The existence of many different tested methods demonstrates the great trouble in correcting anterior septal deviations. If this were a straightforward correction, only one single agreed universal technique would have worked. The techniques historically mentioned for correcting caudal nasal septum deviations only remove more posterior parts of the septum, trying to spare the anterior deviated portion, performing more traditional procedures such as mobilisation, suturing or weakening of this segment. Therefore, although it does not cause cosmetic harm to the nasal tip, the correction of the septum deviation is only partial and this can lead to bad results in terms of nasal obstruction correction, in addition to the relapse of symptoms in the postoperative period 3,8,10–15

Those techniques that involve removal of the deformed anterior part of the cartilage, despite excellent in terms of nasal obstruction and nasal tip deformities, are dependent on more extreme and sophisticated

\*Corresponding author: Mahmoud H, 1Department of Otorhinolaryngology, Faculty of medicine, Ain Shams University, E-mail: hooba78@hotmail.com

procedures, typically after open rhinoplasty 16–21.

**OBJECTIVE**

To test the effectiveness of using the tongue in groove technique endonasally to correct nasal septum caudal deviations.

**MATERIALS AND METHODS**

This is an uncontrolled and non-randomized clinical-prospective study, which started in June of 2017 to June 2020 in two university hospitals done by the study group surgeons. 137 patients older than 18 years old, of both genders suffered of nasal obstruction of more than one-year duration due to mild to moderate septal cartilage deviation in I & II Cottle's areas (anterior or caudal deviations) whether cephalocaudal or anteroposterior, with or without inferior nasal turbinates hypertrophy, without improvement with clinical treatment, not associated with nasal cosmetic complaints.

Although patients with medical and/or surgical sinonasal pathologies were excluded, revision cases (23 cases of the total number) were included as well. All the patients were subjected to history taking with answering a standardized questionnaire before the surgical treatment and 60 days after it. The questionnaire used was the Nasal Obstruction Symptom Evaluation (NOSE) scale - validated by the American Academy of Otolaryngology and Head and neck Surgery, which is specific for nasal septum deviations. This is a scale with five questions about nasal symptoms to which patients assign scores varying between 0 and 4, according to symptom intensity. At the end, the total score given by the patient is multiplied by 5, and one has scores which vary between 0 - patients without symptoms, and 100 - patients with the most intense possible symptoms<sup>22</sup>. Otolaryngological examination, including nasal endoscopy, CT scan para-nasal sinuses (if indicated to exclude a pathology rather than septal deviation), routine preoperative investigations. Standardized photographic documentation in six different positions was carried out before and sixty days after surgery. All patients were consented for the possible tip stiffness.

**SURGICAL TECHNIQUE:**

Under general hypotensive anesthesia the columella and the nasal septum were infiltrated by 2% xylocaine adrenaline 1:100000, nasal decongestant packing with xylometazoline hydrochloride 0.1% for ten minutes.

Hemitransfixion incision followed by submucoperichondrial dissection using Cottle's elevator, beginning at the caudal end of the septum all the way superiorly and inferiorly. Bilateral superior and inferior mucoperichondrial tunnels are dissected and sharp dissection is done to release the attached perichondrium at the junction of superior and inferior tunnels. Bilateral exposure of the bony nasal floor with the whole maxillary crest back to the sphenoid rostrum is mandatory for proper disclosure of all septal deviations and spurs and to allow any redundant mucosa to sit back over the posterior septum.

The septal cartilage should be sharply dissected up to release the attachment of the upper lateral cartilages from the dorsal septum. Rolled caudal end of the septal cartilage should be released, stretched beside the columella and trimmed flush with the anterior border of the columellar skin (Figure 1). At the site of the hemitransfixion incision the skin margin is grasped and everted by Allison's forceps with the finger guarding the opposite side, blunt pointed scissors are used to create a groove all through the height of the columella (nasal tip to columellar base) between the medial crurae of the lower lateral

cartilages in a retrograde fashion (figure 2). The free caudal end of the septal cartilage is tucked in the fashioned groove free of tension and/or deviations and fixed by 3/0 absorbable suture. The needle is first entered through the groove at the base of the columella and emerges through the skin and the needle is pushed again in the same point of exit, a knot is formed and the short limb of the suture is trimmed out. The suture is then applied to the caudal end of the septal cartilage two millimeters proximal to the edge in a zigzag fashion till the dome of the nasal tip where the suture is thrust again in the groove exits the skin at the highest point of the dome lower lateral cartilages and the needle is pushed again at the same point of exit and the long lib is now trimmed after being tied and fixed inside the groove (figure 3)

The hemitransfixion incision is sutured using inverted simple absorbable 3/0 suture. Non absorbable 4/0 stay suture is used to narrow the base of the columella and/or medial crurae if found to be wide after the TIG technique.

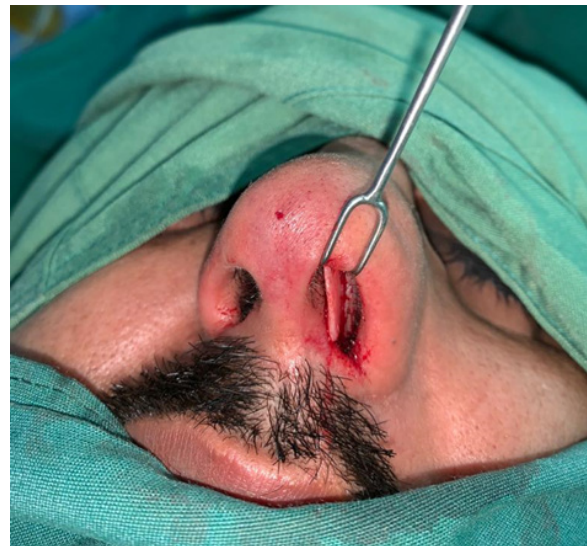

Figure 1: Rolled caudal end of the septal cartilage should be released, stretched beside the columella and trimmed flush with the anterior border of the columellar skin

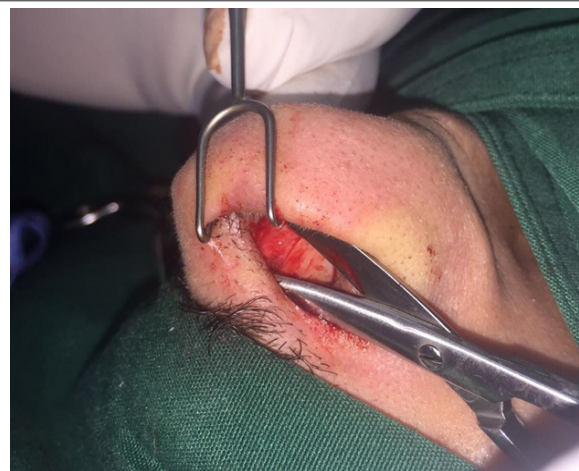
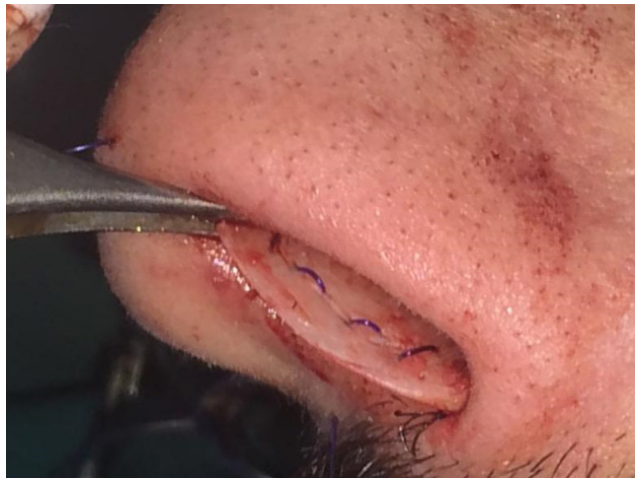
Figure 1: At the site of the hemitransfixion incision the skin margin is grasped and everted by Allison's forceps with the finger guarding the opposite side, blunt pointed scissors are used to create a groove all through the height of the columella



**Figure 3:** The suture is then applied to the caudal end of the septal cartilage two millimeters proximal to the edge in a zigzag fashion till the dome of the nasal tip

**RESULTS:**

137 patients prospectively submitted to surgery under the mentioned technique and followed up. Of these, 55 (40%) were females and 82 (60%) were males.

Considering the results achieved based on the answers given to the NOSE questionnaire, before and 60 days after surgery, the following results were reported.

**Table 1:** pre-operative and post-operative mean and standard deviation of the NOSE questionnaire.

|                           | <i>Pre-operative</i> | <i>Post-operative</i> |
|---------------------------|----------------------|-----------------------|
| <i>Mean</i>               | 35.5                 | 9.5                   |
| <i>Standard deviation</i> | 15.80                | 2.99                  |

On following up the patients after 60 days, four patients were found to have posterior septal perforation (all of less than 0.5 cm, not causing any complaints, so none of them was addressed). 14 patients complained of tip stiffness. 9 patients had an infection of the non-absorbable suture, of which we removed the suture for 4 of them as they did not respond to the topical nor the systemic antibiotics.

**DISCUSSION**

Since the origin of septal surgery, the repair of the caudal end of the septum has been a challenge for the rhinological surgeon. The traditional submucous resection as described by Freer<sup>23</sup> and Killian<sup>24</sup> emphasised the importance of removing the deviated septum portion; but to allow an adequate caudal and dorsal cartilage strip to prevent external nasal deformities. The caudal end of the septum is often the reason of the obstruction, Unless removed or straightened, the objective of the surgery will be deposed. The caudal septum and lower lateral cartilage (LLCs) create an important part of the external nasal valve <sup>25</sup>. Thus, any deviation at this level will increase airflow resistance and a feeling of a blocked nose, also will cause cosmetic concerns due to the apparent bulge of the caudal septal end into the nostril as well. These deformations may arise from earlier trauma, or may be developmental.<sup>26</sup> We operated on 23 revision cases, all did not have the caudal dislocation addressed during the primary septoplasty.

The deviations from the caudal septum can be graded as mild ,

moderate and severe. There has been no single correction procedure known to be successful in all conditions. Most approaches to the caudal nasal septum can be categorised as either cartilage reshaping or septal reconstruction manoeuvres. Although all techniques could be approached through an endonasal or external approach, the majority of caudal septal reconstruction manoeuvres are easier to access through an external approach<sup>1</sup>

The caudal septal deviation can manifest as a form of cephalocaudal or anteroposterior deviation. Cephalocaudal deflections can be repaired using vertical sleeve resection or swinging door technique<sup>27</sup>. When the caudal septum is separated from the anterior nasal spine, a proper relationship between the anterior nasal spine and the posterior end of the caudal septum can be restored. In cases of deviation in the anteroposterior direction, the caudal septum represents a C-shaped convexity, or acute angulation, less frequently. The underlying condition of caudal anteroposterior deviation is generally the excess septal cartilage length encased between the maxillary crest and the nasal roof. A small portion of the posterior end of the caudal septum can be resected to straighten the cartilage, which can place the caudal septum in a straight midline position<sup>28</sup>.

The normal caudal septum has many essential, functional, anatomical relationships. It extends anteriorly from the nasal spine, as the continuation of the main septum. The attachment point establishes the septum posterior angle. As it ascends towards the nasal dorsum, an anterior cartilage projection creates the septum 's intermediate angle. inability to recognise the intermediate angle's aesthetic value, and its excision, results in straight columella – an unwanted iatrogenic problem. The caudal septum and lower lateral cartilages (LLCs) not only form an important component of the external valve but are also responsible for the majority of the nasal tip support<sup>25</sup>. We did not perform any routine excisions of the caudal septum, we only did scoring to straighten the caudal septum to preserve the tip support and the intermediate angle. And if excisions was required especially in anteroposterior caudal deviation, we only did a controlled excision removing the excess cartilage with preserving the intermediate angle, hence preserving the tip support and the shape of the columella.

Many methods have been used to control the caudal septum. Ellis<sup>29</sup> used a suture procedure as an addition to correct deviation of the caudal septum. Kridel et al<sup>30</sup> used the technique of tongue-in-groove to correct the excess columellar show and caudal septal deviation. Metzinger et al<sup>31</sup> used the ethmoid bone sandwich grafting for caudal septal deviation correction via an external rhinoplasty approach. For the correction of dorsal and caudal septal deviations, Andre´ and Vuyk<sup>32</sup> identified septal battens and septal replacement. Gubisch<sup>33</sup> proposed removal of the entire septum, and subsequent extracorporeal septum reconstruction and reinsertion. This wide range of approaches shows how difficult it is to manage caudal septal deviations

Since the introduction of the swinging door technique in 1929 by Metzner<sup>8</sup>, this technique and its variations have been the most commonly used used to correct nasal septum caudal deviations. In this type of correction, The caudal portion of the nasal septum with the deviation is not excised and the cartilage is mobilised by several incisions or weakened by incisions on the opposite side of the deviation, followed by sutures for stabilisation.

The criticisms against this form of technique state that by not having removed the deviated part of the cartilage, especially those in the region of the nasal valve, one would not correct the deviation adequately and the patient would continue to have nasal obstruction.



Since the cartilage that has not been removed may have a memory, it continues to remain deviated or twisted after partial corrections according to Studies from Murakami et al.<sup>34</sup> which revealed the biomechanical properties of the septal cartilages and showed that partial incisions do not provide predictable corrections. Conservative corrections of caudal deviations would then be indicated only in those mild deviations. Our results show that there was no cosmetic change in relation to nasal tip or recurrence of the caudal septal deviation in all our cases of mild to moderate caudal septal deviation. Caudal septal deviation also can be corrected without any excision in the septum which may lead to droopy nose deformity<sup>35,36</sup>

The other methods that can be used to correct caudal deviations are the ones that eliminate part of the deviated cartilage, even if it supports the nasal tip, and inserts part of the autologous cartilage in its place to preserve the nasal structure. This type of technique was initially described by Peer<sup>16</sup> in 1937.

The opponents of these techniques that remove the deviated cartilage claim that improvements in the structure of the nasal tip will not be preserved even after reconstruction. Another weakness found in these corrections with complete removal of the anterior septum would be that this technique is possible only via an open rhinoplasty, as defined by some authors<sup>20,21,37</sup>.

Stabilization of the repositioned caudal septum can also be performed using an tongue in-groove technique. Kridel<sup>30</sup> has described the septum being stabilised in a groove between the medial crurae. Suture is used in that pocket to stabilize the septum. He states that all patients in his series had good functional results at follow-up.

All patients noted improved airway function postoperatively. There was a significant improvement in mean Nasal Obstruction Symptoms Evaluation score postoperatively (35.5 +/- 15.80 VS 9.5 +/- 2.99). Thus, the results from the NOSE questionnaire carried out before surgery show a large incidence of obstruction complaints from those patients with deviations in their caudal septum<sup>6,7</sup>. The results as to the subjective improvement after surgery with the caudal septoplasty technique by the same questionnaire were also found in our study, similarly to what was found in other papers which measured pre and post-operative patient satisfaction after correction of nasal septum deviations<sup>22,38</sup>.

One disadvantage of TIG is the occasional rigid nasal tip complaint due to removal of the flexible membranous septum, as nasal base support is enhanced by bringing a three-layer cartilage structure together, we mentioned the tip rigidity during the consent process.

The concept of TIG is not innovative and with more widespread application of TIG in closed rhinoplasty surgery we only utilized it in cases of endonasal septoplasty through a hemitransfixion incision,

we also used both absorbable and non-absorbable sutures, we did not cut any excess mucosa, we only spread it back over the posterior septum then fixed it by a quilting suture to coapt the septal mucosa away from the skin of the columella avoiding weeping at the vestibule. The technique hereby described does not require specific surgeon knowledge about nasal aesthetics, it does not add any other incision or scar except for the same ones used for regular septoplasty and it does not increase the risk or likelihood of complications. There was no cosmetic complications and no patient complained of any changes regarding nasal tip during the ninety days follow up, of course longer period of follow up is being done

#### CONCLUSION:

The results of our study subjectively indicate, through patient satisfaction, that applying tongue in groove technique endonasally for the correction of caudal septum deviation appears to be effective

#### References

1. Haack J, Papel ID. Caudal Septal Deviation. *Otolaryngol Clin North Am*. 2009;42(3):427-436.
2. Guyuron B, Uzzo CD, Scull H. A practical classification of septonasal deviation and an effective guide to septal surgery. *Plast Reconstr Surg*. 1999;104(7):2202-2209.
3. Sedwick JD, Lopez AB, Gajewski BJ, Simons RL. Caudal septoplasty for treatment of septal deviation: Aesthetic and functional correction of the Nasal Base. *Arch Facial Plast Surg*. 2005;7(3):158-162. doi:10.1001/archfaci.7.3.158
4. Rethi A. Operation to shorten an excessively long nose. *Rev Chir Plast*. 1934;2(85).
5. Williams EF. Alar-columellar disharmony using the tongue-in-groove maneuver in primary endonasal rhinoplasty. *Arch Facial Plast Surg*. 2012;14(4):283-288.
6. Grymer LF, Hilberg O, Elbrond O, Pedersen OF. Acoustic Rhinometry. *Laryngoscope*. 1989;99(11):1180-1187.
7. Dinis PB, Haider H. Septoplasty: Long-term evaluation of results. *Am J Otolaryngol - Head Neck Med Surg*. 2002;23(2):85-90.
8. Metzbaum M. Replacement Of The Lower End Of The Dislocated Septal Cartilage Versus Submucous Resection Of The Dislocated End Of The Septal Cartilage. *Arch Otolaryngol - Head Neck Surg*. 1929; 9(3):282-296.
9. Kridel RW, Scott BA, Foda HM. The tongue-in-groove technique in septorhinoplasty. A 10-year experience. *Arch facial Plast Surg Off Publ Am Acad Facial Plast Reconstr Surgery, Inc Int Fed Facial Plast Surg Soc*. 1999;1(4).
10. Calderón-Cuéllar LT, Trujillo-Hernández B, Vásquez C, Padilla-Acero J, Cisneros-Preciado H. Modified mattress suture technique to correct anterior septal deviation. *Plast Reconstr Surg*. 2004; 114(6):1436-1441.
11. Kenyon GS, Kalan A, Jones NS. Columelloplasty: A new suture technique to correct caudal septal cartilage dislocation. *Clin Otolaryngol Allied Sci*. 2002;27(3):188-191.
12. Lawson W, Westreich R. Correction of caudal deflections of the nasal septum with a modified Goldman septoplasty technique: how we do it. *Ear Nose Throat J*. 2007;86(10):617-620.


13. Goldman IB. New Technique in Surgery of the Deviated Nasal Septum. *AMA Arch Otolaryngol.* 1956;64(3):183-189.
14. Kamer FM, Churukian MM. High septal hemitransfixion for the correction of caudal septal deformities. *Laryngoscope.* 1984;94(3):391-394.
15. Pastorek NJ, Becker DG. Treating the caudal septal deflection. *Arch facial Plast Surg Off Publ Am Acad Facial Plast Reconstr Surgery, Inc Int Fed Facial Plast Surg Soc.* 2000;2(3):217-220.
16. Peer La. An Operation To Repair Lateral Displacement Of The Lower Border Of The Septal Cartilage. *Arch Otolaryngol - Head Neck Surg.* 1937;25(4):475-477.
17. Most SP. Anterior septal reconstruction: Outcomes after a modified extracorporeal septoplasty technique. *Arch Facial Plast Surg.* 2006;8(3):202-207.
18. Bloom DC, Cupp CL. The Percutaneous Columellar Strut. *Am J Rhinol.* 2003;17(6):357-361.
19. Núñez-Fernández D, Vokurka J. Surgical treatment of anterior septal deviations. *Acta medica (Hradec Kral.* 1998;41(3):141-144.
20. Toriumi DM. Subtotal reconstruction of the nasal septum: A preliminary report. *Laryngoscope.* 1994;104(7):906-913.
21. Gubisch W. Extracorporeal septoplasty for the markedly deviated septum. *Arch Facial Plast Surg.* 2005;7(4):218-226.
22. Stewart MG, Witsell DL, Smith TL, Weaver EM, Yueh B, Hannley MT. Development and validation of the Nasal Obstruction Symptom Evaluation (NOSE) Scale. *Otolaryngol - Head Neck Surg.* 2004;130(2):157-163.
23. Freer OT. The correction of deflections of the nasal septum with a minimum of traumatism. *J Am Med Assoc.* 1902;XXXVIII(10):636-642.
24. Killian G. Die submuköse Fensterresektion der Nasenscheidewand. *Arch Laryngol.* 1904;16(3):203.
25. Cole P. The four components of the Nasal valve. *Am J Rhinol.* 2003;17(2):107-110.
26. Sedaghat AR, Busaba NY, Cunningham MJ, Kieff DA. Clinical assessment is an accurate predictor of which patients will need septoplasty. *Laryngoscope.* 2013;123(1):48-52.
27. GOLDMAN IB. Straightening the deviated nose. *N Y State J Med.* 1957;57(5):887-891.
28. Rohrich RJ, Gunter JP, Deuber MA, Adams WP. The Deviated Nose: Optimizing Results Using a Simplified Classification and Algorithmic Approach. *Plast Reconstr Surg.* 2002;110(6):1509-1523.
29. Ellis MS. Suture technique for caudal septal deviations. *Laryngoscope.* 1980;90(9):1510-1512.
30. Kridel RW, Scott BA, Foda HM. The tongue-in-groove technique in septorhinoplasty. A 10-year experience. *Arch facial Plast Surg Off Publ Am Acad Facial Plast Reconstr Surgery, Inc Int Fed Facial Plast Surg Soc.* 1999;1(4).
31. Metzinger SE, Boyce RG, Rigby PL, Joseph JJ, Anderson JR. Ethmoid bone sandwich grafting for caudal septal defects. *Arch Otolaryngol Head Neck Surg.* 1994;120(10):1121-1125.
32. André RF, Vuyk HD. Reconstruction of dorsal and/or caudal nasal septum deformities with septal battens or by septal replacement: an overview and comparison of techniques. *Laryngoscope.* 2006;116(9):1668-1673.
33. Gubisch W. The extracorporeal septum plasty: A technique to correct difficult nasal deformities. *Plast Reconstr Surg.* 1995;95(4):672-682.
34. Murakami WT, Wong LW, Davidson TM. Applications of the biomechanical behavior of cartilage to nasal septoplastic surgery. *Laryngoscope.* 1982;92(3):300-309.
35. Katira K, Guyuron B. Contemporary techniques for effective nasal lengthening. *Facial Plast Surg Clin North Am.* 2015;23(1):81-91.
36. Kadakia S, Ovchinsky A. Comparison of Permanent Versus Absorbable Suture in the Tongue-in-Groove Technique in Endonasal Rhinoplasty. *Am J Cosmet Surg.* 2016;33(2):91-95.
37. Toriumi DM, Becker DG. *Rhinoplasty Dissection Manual.* Lippincott Williams & Wilkins; 1999.
38. Stewart MG, Smith TL, Weaver EM, et al. Outcomes after nasal septoplasty: Results from the Nasal Obstruction Septoplasty Effectiveness (NOSE) study. *Otolaryngol - Head Neck Surg.* 2004;130(3):283-290.

## Author Affiliations

Top

<sup>1</sup>Department of Otorhinolaryngology, Faculty of medicine, Ain Shams University

### Submit your next manuscript and get advantages of SciTechnol submissions

- ❖ 80 Journals
- ❖ 21 Day rapid review process
- ❖ 3000 Editorial team
- ❖ 5 Million readers
- ❖ More than 5000 
- ❖ Quality and quick review processing through Editorial Manager System

Submit your next manuscript at • [www.scitechnol.com/submission](http://www.scitechnol.com/submission)