



# External Frontoethmoidectomy in the University of Port Harcourt Teaching Hospital, Rivers State, Nigeria

Osuji AE\* and Nwogbo A

Department of Ear, Nose And Throat, University Of Port Harcourt Teaching Hospital, Rivers State, Nigeria

\*Corresponding author: Osuji Adaobi, Department of Ear, Nose And Throat, University Of Port Harcourt Teaching Hospital, Rivers State, Nigeria, E-mail: osujiliz@yahoo.com

Received Date: March 15, 2019; Accepted Date: July 9, 2019; Published Date: July 17, 2019

## Abstract

**Introduction:** External Frontoethmoidectomy is an open surgical procedure employed to remove disease from the frontal and ethmoidal sinuses. Pathologies in the para nasal sinuses can be managed endoscopically, however, the limited availability of skilled man power in endoscopic sinus surgeries, and the dearth of its instruments in this region, remains a challenge in most tertiary health care centres in Nigeria, thus promoting the use of external approach to manage sinus diseases.

**Method:** This was a retrospective study of 10 patients who had Frontoethmoidectomy over a 6 year period, from January 2012 to December 2017. Their medical records were retrieved from operating theatre, and Ear, Nose and Throat ward. Information retrieved included their age, gender, presenting complain, indication for surgery and length of hospital stay. Results were presented in tables and figures.

**Results:** Among the 10 patients, there were 7 males and 3 females, 6 (60%) were aged 10-19 years. The indications for surgery was Fronto-ethmoidal mucocele in 3 patients and frontal mucocele in 2 patients, frontal sinusitis with intracerebral abscess in 1 patient, pan sinusitis with sinu-cutaneous fistula in 1 patient, potts puffy tumor in 1 patient, fronto-ethmoidal abscess, and fronto-ethmoidal osteoma in 1 patient each. Nasal obstruction was the commonest complain 7(70%), followed by frontal headache 4(40%). The average hospital stay among the patients was 6 days.

**Conclusion:** External fronto-ethmoidectomy has remained the mainstay of treatment for frontal and ethmoidal sinus pathologies in this region, despite the advent of endoscopic sinus surgery. Early presentation for specialist otorhinolaryngological management can reduce morbidity and mortality.

**Keywords:** Fronto-ethmoidectomy; mucocele; Para nasal sinuses; Teaching hospital

## Introduction

External Frontoethmoidectomy is an open surgical procedure employed to remove disease from the frontal and ethmoidal sinuses [1]. It is also referred to as the Lynch-Howarth operation. Pathologies in the Para nasal sinuses can also be managed endoscopically [2]. However, inadequate availability of endoscopic surgical facilities in this region, have limited its application in the management of these nasal pathologies.

Mucocele is a benign mass, cystic in nature which affects the sinuses. It results from blockage of sinus ostium, leading to accumulation of mucus in the affected sinus. Frontal and ethmoid sinuses are commonly affected, and symptoms vary, depending on the extent of the diseases [3]. Other benign pathologies that can arise from these sinuses include pyoceles, potts puffy tumor, Fronto ethmoido-cutaneous fistula and polyposis. These sinus pathologies can involve the orbit or intracranial compartment, leading to orbital or neurological complications [4].

Surgeries of the nose have markedly progressed beyond conventional open surgeries, since the advent of functional endoscopic sinus surgery (FESS) [1]. However, these open surgeries like external Frontoethmoidectomy have remained the mainstay of management of most advanced pathologies of the frontal and ethmoidal sinuses, especially in cases of large tumor size, with grossly distorted anatomy [5,6]. This is because they give good exposure, are easy to carry out, and have minimal complications. On the other hand, modern surgeries like endoscopic sinus surgery, and endo-nasal laser surgeries have the main advantage of doing surgery under magnified vision, with reduced bleeding, and the ability to look around corners, thereby improving surgical precision with reduced morbidity.

Historically, the first landmark publication of endoscopic sinus surgery was done by Kennedy in 1989. He described endoscopic marsupialization of mucocele, leaving the mucosal lining behind [6]. However, advance in computerized imaging, cameras and instrumentation, and seasoned experience, has improved the popularity of endoscopic sinus surgeries globally. This has been welcomed in sub-Saharan Africa with great enthusiasm, but the practice of the conventional external approach still predominates in most centres. This is because of the limited availability of skilled man power in endoscopic sinus surgeries, and the dearth of its instruments in this region. This has remained a challenge in most tertiary health care centres in Nigeria, thus promoting the use of external approach to manage sinus diseases [7].

The aim of this study was to take an inventory of the cases of Frontoethmoidectomy done in the university of port Harcourt teaching hospital, rivers state, and to highlight the presenting symptoms, indications for surgery, and their general outcome.

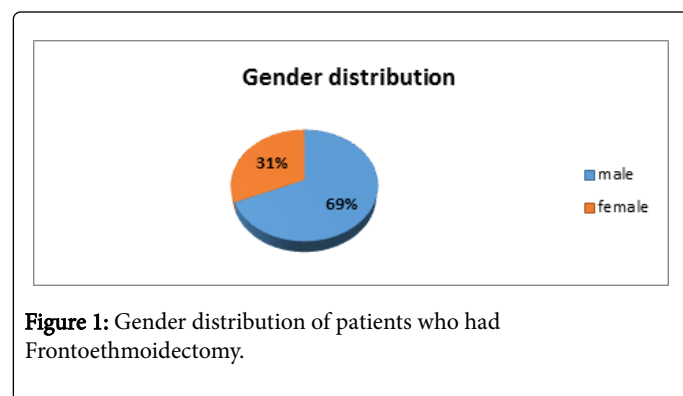
## Method

This was a retrospective study of 10 patients who had Frontoethmoidectomy over a 6 year period, from January 2012 to December 2017. Their medical records were retrieved from the ENT operating theatre, and Ear, Nose and Throat ward. Information retrieved included their age, gender, presenting complain, indication for surgery and length of hospital stay. Results were presented in simple tables and figures. Ethical approval is approved for this study. Informed consent is taken from the respective patients.

Every patient in this study, had frontoethmoidectomy using either the lynch incision or the modified lynch incision. No osteoplastic flap was done in all the cases. And they all had intranasal frontoethmoidal stenting done using an improvised length of nasogastric feeding tube, enough to abut 1cm outside the anterior aperture of the nose on the side of the lesion. This was anchored on the columella in each patient.

## Results

Among the 10 patients, there were 7 males and 3 females (Figure 1). The age of the patients ranged from 8 years to 42 years. The age distribution of the patients as shown in Table 1, indicates that the highest number of patients, 6(60%) were aged 10-19 years. Table 2 below, shows that nasal obstruction was the commonest presenting complain 7(70%), followed by frontal headache 4(40%). However, 3 patients had proptosis at presentation, while 1 patient had a discharging sinus. The indications for surgery was Fronto-ethmoidal mucocoele in 3 patients and frontal mucocoele in 3 patients, frontal sinusitis with intracerebral abscess in 1 patient, pan sinusitis with sinu-cutaneous fistula in 1 patient, potts puffy tumor in 1 patient, fronto-ethmoidal abscess, and fronto-ethmoidal osteoma in 1 patient each, as shown in Table 3. It shows the length of hospital stay among the patients. The average hospital stay among the patients was 6 days, however the hospital stay ranged from 5 days to 10 days Table 4.



## Discussion

External fronto ethmoidectomy is the main stay of surgical treatment of frontal and ethmoidal sinus pathologies in our centre. This is due to absence of equipment and trained manpower for endoscopic surgery in our centre. As a result, all the pathologies involving the frontal sinus and the ethmoid sinus is addressed through an open surgery. However in some centres in Nigeria, as much as external Frontoethmoidectomy is carried out for fronto-ethmoidal pathologies, endoscopic sinus surgery is also carried out on some of their patients [7].

Our finding reveals a male: female ratio of 2.2:1 in frontal sinus pathology and fronto-ethmoidectomy. This is similar to the study by by Gavioli et al. [2] and Caylakli et al. [8] who noted a male preponderance of frontal sinus mucocoele. Contrary to these, the case of fronto-ethmoidal mucocoele noted in the study by Odebode et al was in a female [9]. However, Cavalho et al. [4] opined that there is no sex prevalence for fronto-ethmoidal mucocoele.

The age range of our patients ranged from 8 years to 42 years, with the highest number of cases noted in the pediatric population. Similarly, Nicholas et al. [10] in France reported 10 cases of Para nasal

sinus mucocoele was in children, despite their report stating that Para nasal sinus mucocoele is rare in the pediatric population . They also noted that 6 patients in their study had cystic fibrosis, which predisposed them to mucocoele of Para nasal sinuses. Our study did not investigate the causes of mucocoele in our patients. The treatment of all their patients were by endoscopic surgery, however due to unavailability of endoscopic surgery in our centre, all our patients had open surgery. Despite our approach, the outcome was acceptable.

Age category	Number of patients	Percentage (%)
<10 years	1	10
10-19 years	6	60
20-29 years	0	0
30-39 years	2	20
40-49 years	1	10
Total	10	100

**Table 1:** Age distribution of patients.

Nasal obstruction was the commonest symptom seen in our patients, similar to the case reported by Odebode et al [9] and the study by Iqbal et al [11]. They attributed it to nasal polyps in some of their patients, which was reported as the presumptive cause of the mucocoele formation in the affected frontal and ethmoidal sinuses. They found nasal symptoms in two of the 5 cases reported in their case series. Nasal obstruction has been noted to be a common presenting complain in Para nasal sinus pathologies, and it was shown in this study, similar to several other studies [1-9,11,12]. Our study reported proptosis as one of the presenting features, and this is similar to the findings by Odebode et al in 2005 [9], a case of bilateral fronto-ethmoidal mucocoele, with bilateral proptosis.

Complaints	Number	Percentage (%)
Nasal obstruction	7	70
Frontal headache	4	40
Generalised Headache	2	20
Frontal swelling	3	30
Proptosis	3	30
Discharging sinus	1	10

**Table 2:** Presenting complaints.

They also noted that some patients with fronto ethmoidal mucocoele show some degree of dynamic or a dynamic proptosis, supraorbital swelling [9]. Similarly, frontal swelling was noted in some patients in our study. However, these are features of advanced disease, where the mucocoele had expanded beyond the confines of the sinus into the orbit, causing proptosis. One patient had osteomyelitis of the frontal bone, which resulted in potts puffy tumor, with frontal swelling while another patient had a discharging sinus, which probably resulted from previous instrumentation, which was later established as a fronto-ethmoido cutaneous fistula.

This study noted that the commonest indication for Frontoethmoidectomy was mucocele of the Fronto-ethmoidal sinuses. Mucocele are commonest in the frontal sinus. When it forms within the sinus, it can grow large enough to obstruct the ostium of affected frontal sinus, or increase markedly to involve the adjacent ethmoid sinus, or the contralateral frontal sinus [13].

The length of hospital stay postoperatively ranged from 5 days to 10 days. This is close to the postoperative stay in the study Lasisi et al, in Ibadan, Nigeria which ranged from 5 days to 17 days [1]. However, their study reported various open surgeries like Caldwell luc operation, lateral rhinotomy, and external fronto ethmoidectomy. The other surgeries may be responsible for the extended stay in their study.

In this study our patients were discharged after 5-6 days of hospital stay. However, in Nigeria, length of hospital stay is influenced by factors other than patients' recovery. Most patients pay out of pocket to foot their hospital bill, and non-availability of funds to clear their hospital bill, can inadvertently extends a patients hospital stay. This was the case for 2 of our patients whose hospital stay was 8 days respectively. The patient whose stay lasted up to 10 days, was the case of frontoethmoido-cutaneous fistula, who had delayed wound healing after surgery, probably following excision of the fistula. However, considering presence of intranasal Frontoethmoidal stent insitu, she was kept on admission till wound healing was satisfactory enough for her to be discharged home.

Indications	Number patients	of	Percentage (%)
Fronto-ethmoidal mucocele	3		30
frontal mucocele	2		20
Potts puffy tumour	1		10
frontal sinusitis with intracerebral abscess	1		10
pansinusitis with sinu-cutaneous fistula	1		10
Fronto-ethmoidalabscess	1		10
fronto-ethmoidal osteoma	1		10
Total	10		100

**Table 3:** indications for fronto-ethmoidectomy.

Imogu in 2015 [7] stated that the success of this procedure is limited by the problem of maintaining fronto nasal duct patency. However, Cavalho et al. [4] stated that involvement of the nasolacrimal duct is uncommon, but nasolacrimal mucocele can be an atypical location of a Para nasal sinus mucocele. There was no complication compromising the patency of the fronto-nasal duct in our patients. However all the patients had scars which was acceptable to them. One patient with fronto-ethmoido-cutaneous fistula came with an unsightly previous scar around the fistula, which was excised and refashioned during her surgery. Lasisi et al. [1] also noted surgical scar as one of the outcomes of external Frontoethmoidectomy in their study. Similarly, their patients were comfortable with the scars. Generally, we noted very good outcome with all our patients, and no mortality was noted.

Courson et al. [6] in their meta-analysis comparing endoscopic and external Frontoethmoidectomy, showed that Complication rates are

similar, but more recurrence was observed with external approach. More cases can be treated endoscopically, however, in cases involving large tumours of the Frontoethmoidal sinuses, external approach is preferable, also in situations where endoscopic approach fails to achieve the desired result [5]. In essence, frequent use of open approach only reflects lack of equipment and expertise in carrying out endoscopic treatment [14].

Length of hospital stay (days)	No of patients	Percentage (%)
5 days	4	50
6 days	3	20
8 days	2	20
10 days	1	10
Total	10	100

**Table 4:** Length of hospital stay.

## Conclusion

Despite the advent of endoscopic sinus surgery, external fronto-ethmoidectomy has remained the mainstay of treatment for frontal and ethmoidal sinus pathologies in this region. Early presentation for specialist otorhinolaryngological management can reduce morbidity and mortality.

## Conflict of Interest

The authors have declared that there is no conflict of interest.

## References

1. Lasisi AO, Adeosun AA (2007) Traditional open surgery for advanced benign nasal tumours in an era of endoscopy: review of 38 cases. *Afr J Health Sci* 14: 44-48.
2. Gavioli C, Grasso DL, Carinci F, Amoroso C, Pastore A (2002) Mucoceles of the frontal sinus: Clinical and therapeutic considerations. *Minerva Stomatol* 51: 385-390.
3. Abuzeid WM, Mace JC, Costa ML, Rudmik L, Soler ZM, et al. (2016) Outcome of chronic frontal sinusitis treated with ethmoidectomy: a prospective study. *Int Forum Allergy Rhinol* 6: 597-604.
4. Carvalho BV, Lopes IC, Correa JB, Ramos LFM, Motta EGPC, et al. (2013) Typical and atypical presentations of paranasal sinus mucocele at computed tomography *Radiol Bras* 46: 372-375.
5. Shah JT (1999) Conventional nasal and sinus surgery. *Bombay hospital journal: Issue special*.
6. Courson AM, Stankiewicz JA, Lal D (2014) Contemporary management of frontal sinus mucoceles: A meta-analysis. *Laryngoscope* 124: 378-386.
7. Imogu A (2015) External frontoethmoidectomy in management of sinus disease; techniquesfor maintaining fronto-nasal duct patency. *Otolaryngol (sunnyvale)* 5: 39-44.
8. Caylakli F, Yavuz H, Cagici AC, Ozluoglo LN (2006) Endoscopic sinus surgery for maxillary sinus mucoceles. *Head Face med* 2: 29.

9. Odebode TO, Ologe FE, Segun-Busari S, Nzeh DA (2005) Recurrent bilateral fronto-ethmoidal mucocoele with intracranial extension: A case report. *West Afr J Med* 24: 268-271.
10. Nicholas R, Facon F, Sudre-Levillain I, Forman C, Roman S, et al. (2006) Paediatric paranasal sinus mucocoeles: etiologic factors, management and outcome. *Int J Pediatr Otorhinolaryngol* 70: 905-908.
11. Iqbal M, Khan FS, Latif A (2015) Outcome of external frontoethmoidectomy with sphenoidotomy in invasive fungal rhinosinusitis. *Pak J Med Health Sci* 9: 586-588.
12. Ologe FE, Odebode TO, Owoeye JF, Eletta PA (2003) Ophthalmic manifestations of fronto-ethmoidal mucocoeles: a report of five cases. *Afr J Med Med Sci* 32: 209-214.
13. Tassel PV, Lee Y, Jing B, De Pena C (1989) Mucocoeles of the paranasal sinuses: MR imaging with CT correlation. *Am J Neuroradiol* 153: 407-412.
14. Mohammadi G, Sayyah Meli MR, Naderpour M (2008) Endoscopic surgical treatment of paranasal sinus mucocoele. *Med J Malaysia* 63: 39-40.