



Hernia-Roof Access : A Novel Technique to Enter Preperitoneal Space in Groin Hernia Repair

Zhong Jia*, Chao He and Yue Zhou

Abstract

Background: There are many ways to perform groin hernia repair. But the protection and closure of the inner orifice seem to be seldom emphasized as of implant mesh application. In fact, injured or unclosed orifice or unfixed mesh might be one of potential risk of hernia recurrence.

Aim: To explore hernia-roof's accessibility and outcomes of patients with groin hernia.

Methods: Using hernia-roof technique to perform groin hernia repair in 189 cases between 2010 and 2012. All patients were performed successfully in open surgery. Also, they received at least 3-year follow-up after surgery in doctor's office.

Results: Only one died of heart attack 2 years later after surgery. Up to date, only one suffered hernia recurrence about one and half a year after surgery due to his serious chronic coughing. No other serious complications was observed.

Conclusion: Hernia_roof technique can provide a high-degree supportable groin area via the protection of inner orifice and 3-D structure reconstruction.

Keywords

Groin hernia repair; Hernia-roof; Preperitoneal approach

Introduction

The preperitoneal approach for inguinal hernia repair is prioritized treatment for majority of inguinal hernia patients at least in most eastern countries; while Lichtenstein technique seems more acceptable in western countries [1]. But how to furtherly strengthen their performance is indeed an enthralled topic. Beside artificial mesh, what we can do in the future? As a matter of fact, the natural integrity of transversalis fascia is of crucial importance for the promising high-degree support at maximum possibility, hence, the closure of inner orifice is still the most critical step. Hernia-roof approach, herein aims to be introduced as a tentative start, which has been confirmed as a safe and effective method in our past 5-year perspective cohort clinical trials [2-4].

4.0 Surgical Procedures

*Corresponding author: Dr. Jia Zhong, Department of Hepatobiliary Surgery, Hangzhou First People's Hospital, Nanjing Medical University, Hangzhou 310006, China, Tel: +86-13958114181; Fax: +86-0571-87914773; E-mail: jiazhong20058@hotmail.com

Received: November 25, 2017 Accepted: February 06, 2018 Published: February 13, 2018

(Figure 1). The technique, including anesthesia and the open of incision, as usual, is performed with preparation of two piece of soft, light flat meshes (lower mesh 10 cm × 15 cm, upper mesh 5 cm × 15 cm, respectively in size, made in China).

A. After usual operative steps to expose "hernia" (composed of outside cover of hernia sac and true hernia sac), we open the outside cover of hernia-roof on a proper position to expose the true sac, and then we stitch the true sac-roof with a suture (as a leading line) so as to avoid the true sac reducing. After that, we "take off" outside cover of the true sac along the gap between them until the inner orifice is visually exposed. Usually, the thickened edge of the inner orifice can be obviously felt by finger examination. At this moment, if the true sac is pushed to navigate the inner orifice, the free preperitoneal space will be obtained easily. And then we stitch the true sac on the reverse part of the lower mesh with a suture, by which it can prevent potential movement of the true sac when the lower mesh is placed well.

B. After rolling the lower mesh into a slim shape, we grip the edge end of the lower mesh with a proper equipment such as oval clamp or forceps, and then insert one side of the lower mesh into the preperitoneal space and flatten it, the another side of the mesh is treated by similar procedure. If the inner orifice is bigger enough to navigate an index finger, the lower mesh can also be directly placed with finger.

C. Finally, we close the inner orifice by a continued suture, meanwhile we also stitch the stump of the drain leash of the lower mesh on the thickened edge of the inner orifice after the excessive leash is tripped off. When all is finished, the operative looks "nature" and is strengthened in maximum possibility because the true sac, the lower mesh and the inner orifice are all fixed together as an irremovable unit. As usual, we finish the later operation, including placement of the upper mesh.

Results

All 189 patients were successfully performed hernia repair by hernia-roof technique. Only one of them died of heart stroke after 2-year follow-up. Only one male patient at the age of 66 suffered recurrence about one and half a year later mainly due to his serious chronic coughing. At first, he complained bulging feeling in groin area but no special findings were found in ultrasonography until recurrence. He didn't received reoperation because he worried his uncontrollable coughing leading surgery to be failure once again. No chronic pain was found in these patients. All patients received at least 3-year follow-up in doctor's office. Quality of life was evaluated by multiple ways, including finger examination to judge the resistance of groin wall, ultrasonography examination to detect the possible recurrence or mesh moving, using special instrument to measure the strength of groin wall when the instrument relieves a strength to the groin wall, etc. Neither discomfort of bulging feeling nor foreign body sensation at satisfying rate were considered. The total satisfaction rate was up to 97%.

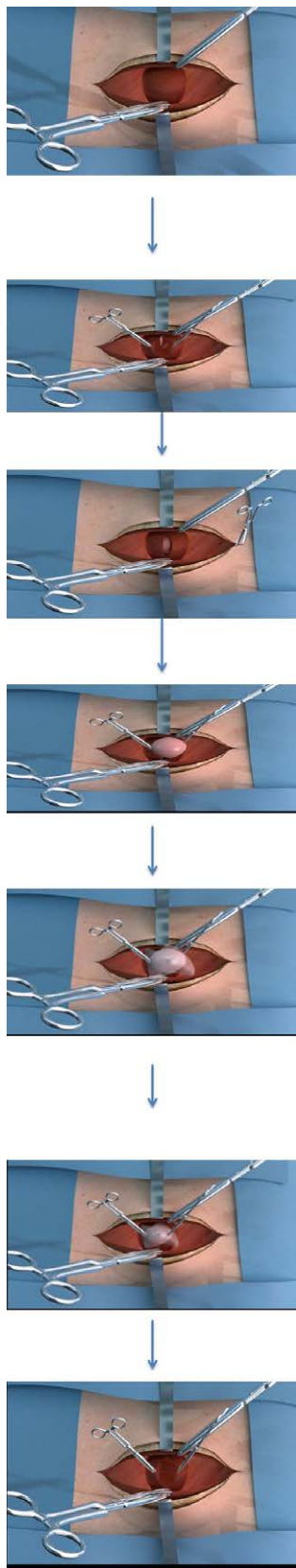


Figure 1: Flow program of hernia-roof approach for inguinal hernia repair.

Discussion

The incidence of inguinal hernia in China is approximately 0.3%-0.5%. It is still a challenge despite current therapies which seem safe and effective, because hernia recurrence and other complications such as chronic pain, sensation of bulging, etc. severely influence the quality of life after surgery. To be well known, preperitoneal approach to groin hernia repair with using of flat mesh or plug has been recognized as one of the most priority for hernia patients [5]. However, the protection of transversalis fascia, including the inner orifice and involved nerves, is a little far from getting enough attention due to unintended damage to them. In 2010, Mainik et al. [6] pointed out the important role of the preperitoneal loop (the inner orifice) for inguinal herniorrhaphy is just to close and to strengthen the defects including the inner orifice existing in the deep layer of transversalis fascia. Unfortunately, the inner orifice in fact is frequently damaged by undesired separation, which also leads to diathermy burn to involved nerves. Frankly, the awareness of keeping transversalis fascia, especially its deep layer including the resilient orifice undamaged, is a very important notion of raising groin supportable ability.

To the best of our knowledge, transversalis fascia includes the superficial layer (i.e. the outside cover of true sac just belongs to it) and the deep layer (i.e. the inner orifice belongs to it). Based on this anatomic basis, we create the hernia-roof approach. During surgery, the lower mesh is fixed on the true sac and the inner orifice as well, which can provide a stronger repairing effect than using the lower mesh alone. Up to date, nearly 1,150 patients received this technique, which had obtained the approval from the ethic committee of our institution and informed consent from patients before surgery. As a result, in the past 5-years clinical practice, we have obtained patients' satisfaction and achieve the goal of therapy. In review of 1-5 years follow-up after surgery, only one patient died because of heart attack about 2 years after surgery, which confirmed hernia-roof approach safe and effective. Of note, the gap between the true sac and its outside cover should be clear and ease to be separated. Otherwise, we prefer to choose previous methods. In fact, when we pinch and twitch the hernia by two fingers, usually, we can have a sense of layered structure of hernia wall, if so, we choose hernia-roof approach.

Here, we just hope more hernia specialists have opportunity to perform the hernia-roof approach so as to confirm its accessibility and its feasibility, by which we can strengthen hernia repair methods rather than replace any other approaches for hernia patients. In TAP or TEPP technique, majority of surgeons generally unclose the inner orifice because they believe the mesh is big enough to cover any potential defect including the inner orifice. Although it is an important part to allow adequate overlap of mesh to enhance the degree of groin wall, in my viewpoint., additional closure of the inner orifice is essential. In many grassroots' clinical, big mesh also means big healthcare cost for low- or middle-income patients. We should push the development of hernia repairing industry relying on precisional technique rather than mesh alone. In the past, we performed groin hernia repair by neck-shoulder technique. Actually, the technique often results in unintended injury to the inner orifice or nature structure of transversalis fascial. If the inner orifice is very large, the previous technique will expose its disadvantage. For example, we often have to spend more time to reconstruct the damaged transversalis fascia.

Sometimes the inner orifice is very small to directly replace the big flat mesh. In this condition, we roll up the flat mesh into a thin slip

to insert through the small orifice and then using a special instrument to flat it. As the mesh is very soft and it embraces the self-remember feature to allow its shape recovered. Honestly, the proper material is also a promise for successful surgery via hernia-roof technique. Overall, these simulate photos of operation may be helpful to better understand our novel technique.

Conclusions

Hernia-roof approach provides a stronger groin area via closure of inner orifice.

References

1. Magnusson J, Nygren J, Gustafsson UO, Thorell A (2016) UltraPro Hernia System, Prolene Hernia System and Lichtenstein for primary inguinal hernia repair: 3-year outcomes of a prospective randomized controlled trial. *Hernia* 20: 641-648.
2. Wu K, Jia Z, Jin HC (2016) Anatomical basis and clinical application of preperitoneal tension-free hernia repair via HST approach. (Chinese) *Chin J Hernia Abdominal Wall Surg* 10: 369-371.
3. Jia Z, Wu K, Kong SY (2016) Optimized techniques may avoid groin bulging after huge hernioplasty. *J Med Imp Surg* 1: 109.
4. Wu K, Jia Z, Zhu YH (2016) 3-D Herniorrhaphy may be Accessible via Hernia Sac Top Pathway. *Surgery Curr Res* 6: 272.
5. Basile F, Biondi A, Donati M (2013) Surgical approach to abdominal wall defects: history and new trends. *Int J Surg* 1: S20-S23.
6. Mainik F, Quast G, Flade-Kuthe R, Kuthe A, SchroedIF (2010) The preperitoneal loop in inguinal hernia repair following the article totally extra peritoneal technique. *Hernia* 14: 361-367.

Author Affiliation

[Top](#)

Department of Hepatobiliary Surgery, Hangzhou First People's Hospital, Nanjing Medical University, Hangzhou 310006, China

Submit your next manuscript and get advantages of SciTechnol submissions

- ❖ 80 Journals
- ❖ 21 Day rapid review process
- ❖ 3000 Editorial team
- ❖ 5 Million readers
- ❖ More than 5000 
- ❖ Quality and quick review processing through Editorial Manager System

Submit your next manuscript at • www.scitechnol.com/submission