



Increased Liver Density from Chronic Amiodarone Therapy

Swathy Puthalapattu*

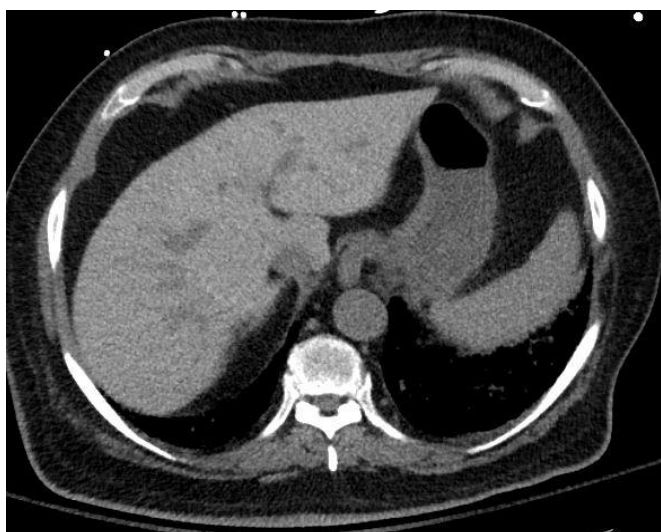


Figure 1: Increased Liver Density from Chronic Amiodarone atient Chronic Amiodarone.

Clinical Image

It is a study in a male patient who was with an age of 75 year old with past medical history significant for coronary artery disease, atrial flutter, chronic systolic heart failure with EF of 25% s/p AICD, chronic kidney disease presented to hospital with complaints of fevers, chills and shortness of breath. Patient has been on chronic Amiodarone (Figure 1).

Citation: Puthalapattu S (2020) Increased Liver Density from Chronic Amiodarone Therapy. *J Clin Image Case Rep*.

*Corresponding author: Swathy Puthalapattu, 3601 S, 6th Avenue, Tucson, Arizona, 85723, USA, Tel: 7852243194; E-mail: swathy.puthalapattu@va.gov

Received: September 13, 2019 Accepted: November 29, 2019 Published: January 06, 2020

Author Affiliations

[Top](#)

Department of Veterans Affairs, Atlanta Veterans Affairs Medical Center, Emory University, USA