



Case Report

A SCITECHNOL JOURNAL

Interstitial Implantation of the Placenta presenting with Retained Placenta after Vaginal Delivery at Term

Chin Hui Xian^{1*}, Tan Eng Loy¹, Tan Lay Kok¹ and Ho Tew Hong¹

Abstract

We report an unusual case of an interstitially-implanted pregnancy presenting with retained placenta after normal vaginal delivery of a live fetus at term. A 32 year-old primigravida, with no previous uterine surgery or instrumentation underwent induction of labour at term for suspected intrauterine growth retardation. The placenta was retained after normal vaginal delivery. Manual removal of the placenta under anaesthesia was attempted but unsuccessful. Exploratory laparotomy and hysterotomy were performed for removal of the placenta, which was found to be implanted in the right cornual region of the uterus. This part of the uterus was sacculated, thinned out and poorly-contracted after the removal of the placenta, resulting in postpartum hemorrhage necessitating uterotonics, compression sutures and placement of a B-lynch suture. This case highlights the need to consider abnormal implantation sites when the placenta is retained in a low risk patient.

Keywords

Retained placenta; Interstitial implantation of placenta; Vaginal delivery; Postpartum hemorrhage

Introduction

Retained placenta (RP) can occur as a complication in 2 to 3% of vaginal deliveries in developed countries [1,2]. The commonest risk factors are preterm birth and previous RP. In most cases, the placenta may be adherent but can easily be removed manually. We report a case of RP after normal vaginal delivery at term, resulting from an interstitially-implanted placenta. This diagnosis was made only at the time of laparotomy and hysterotomy, which was necessary for removal of the placenta.

Case Report

Mdm S is a 32 year-old primigravida who conceived spontaneously and was booked for antenatal care in early pregnancy. No previous uterine surgery or instrumentation, nor tubal pathology was reported. She was antenatally well. First trimester screening at 13 weeks was low risk for trisomies 21, 18 and 13. A screening scan at 20 weeks gestation showed no fetal anomalies. The placenta was noted to be sited posteriorly and high. Serial growth scans performed between

28 and 38 weeks of gestation suggested the possibility of intrauterine growth retardation, although amniotic fluid volume and Doppler studies were normal. Fetal movements were reported to be adequate and fetal cardiogram was also normal. However, the patient was anxious about fetal well-being and after extensive counseling, opted for induction of labour.

Induction of labour was carried out at 38 weeks 4 days gestation with prostaglandins. She had an uneventful progress in labour – she received an epidural for pain relief and no oxytocin was required for augmentation. A baby boy, birth weight 2920g, with Apgar scores of 8 and 9 at 1 and 5 minutes respectively, was delivered via spontaneous vaginal delivery after 8 hours in labour. However, the placenta was retained and attempts at controlled cord traction to deliver the placenta were unsuccessful even after an attempt of intraumbilical vein injection with oxytocin. A decision was hence made for manual removal of the placenta (MRP) in the operating theatre under anaesthesia.

Intraoperatively, the placenta was found to be located high in the uterine cavity and tightly adherent to the uterus with no definite plane palpable between placenta and uterine wall. A uterine constriction ring was felt just below the placenta. Multiple attempts at MRP were unsuccessful. In view of active bleeding, a decision was made for laparotomy, hysterotomy and removal of placenta, keeping in view hysterectomy. Upon laparotomy, the right cornual region of the uterus was bulging with the placenta within, suggesting interstitial or cornual implantation of the placenta (Figure 1). The placenta was finally removed manually through an incision over the lower uterine segment.

After the removal of the placenta, the right cornual region where the placenta was sited, was thinned out and flaccid (Figure 2). Interrupted sutures were placed to externally compress and tamponade this area. A B-lynch suture was also inserted for uterine tamponade. However, uterine atony was persistent especially over the right cornual region, necessitating two doses of intramuscular carboprost 250 mcg each given 15 minutes apart. At the same time, an oxytocin infusion was set up and the patient received fresh frozen plasma and blood transfusion. Uterine tone improved subsequently and the uterus was successfully conserved. The total estimated blood loss was 2000 ml. The patient's post-operative recovery was uneventful and the patient was discharged well. Placental histology revealed no evidence of placenta accreta, with a placental weight of 531g.

Discussion

The incidence of RP may range from 0.01 to 6.3% of vaginal deliveries [1]. RP is commonly defined as lack of expulsion of the placenta within 30 minutes of delivery of the baby. The common risk factors for RP include previous RP, preterm birth, previous uterine curettage, preeclampsia and induced or augmented labor. In this case, RP resulted from an abnormally sited placenta. The pregnancy had likely implanted in the interstitium of the fallopian tube, with the placenta developing and growing there, and the fetus growing eventually within the uterus.

Interstitial or cornual pregnancies are ectopic gestations associated with a maternal mortality rate 7 to 15 times higher than

*Corresponding author: Chin Hui Xian, Medical Officer, Department of Obstetrics and Gynaecology, Singapore General Hospital, Outram Road, 169608, Singapore, E-mail: fchinhx@gmail.com

Received: December 22, 2015 Accepted: March 16, 2016 Published: March 21, 2016

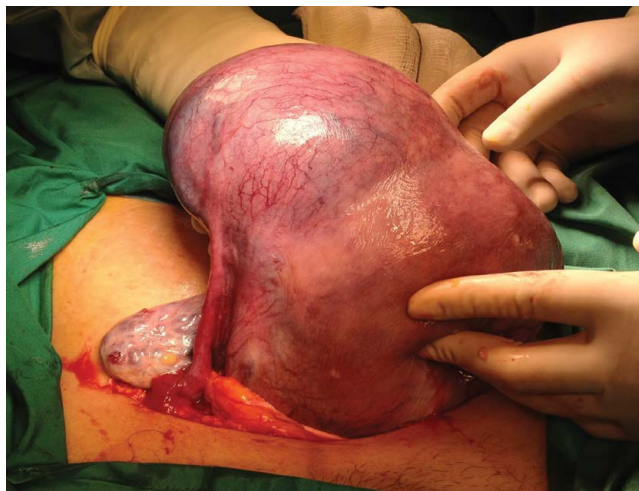

Figure 1: Right cornual mass containing the adherent placenta.

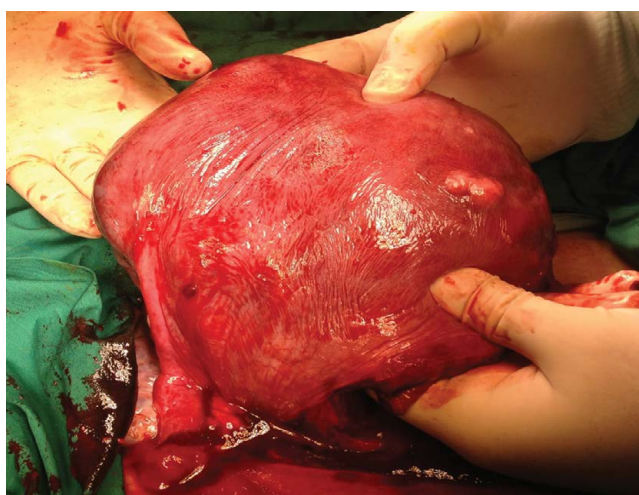


Figure 2: Poorly contracted right cornual region after removal of placenta via hysteroscopy incision over the lower uterine segment.

other ectopic gestations [2,3]. While there has been rare case reports of term or near-term interstitial pregnancies and most of these were presented with uterine rupture [4-8]. Interestingly, there was no evidence of uterine rupture in this case, and the pregnancy was carried to term and delivered vaginally. This gives rise to the postulation that although the placenta was implanted interstitially, the fetus developed within the uterine cavity.

Fetal growth restriction is seen in up to 30% of interstitial pregnancies which resulted in live births [9]. In this case, serial growth scans suggested decreased growth velocity towards the end of pregnancy. This is postulated to be due to the abnormal implantation of the placenta, which might have resulted in a degree of uteroplacental insufficiency.

At delivery, the stretched out retroplacental myometrium would not have been able to contract efficiently for the detachment of the placenta in the third stage of labour [10,11]. Further, a constriction ring formed beneath the placenta by the normally contracted surrounding myometrium posed added difficulty to MRP under anaesthesia. Swift

recourse to laparotomy is essential in the management of these cases, as major obstetric hemorrhage may ensue from uterine atony and manipulation of an adherent placenta during MRP.

This case highlights the need to consider interstitial implantation of the placenta as a possible cause of RP in a low risk patient, as this is difficult to diagnose antenatally [12], especially if the fetus is within the uterine cavity. RP may be the first presentation in such cases.

References

1. Cheung WM, Hawkes A, Ibish S, Weeks AD (2011) The retained placenta: historical and geographical rate variations. *J Obstet Gynaecol* 31: 37-42.
2. Lau S, Tulandi T (1999) Conservative medical and surgical management of interstitial ectopic pregnancy. *Fertil Steril* 72: 207-215.
3. Walker JJ (2007) Ectopic pregnancy. *Clin Obstet Gynecol* 50: 89-99.
4. Ng PH, NorAzlin MI, Nasri NI (2007) Term interstitial pregnancy with uterine conservation. *Int J Gynecol Obstet* 99: 251.
5. Scarella A, Marquez R, Schilling H, Palomino A (2012) Antenatal diagnosis of a third trimester interstitial pregnancy: a case report. *J Obstet Gynaecol Res* 38: 570-573.
6. Idama TO, Tuck CS, Ivory C, Ellerington MC, Travis S (1999) Survival of cornual (interstitial) pregnancy. *Eur J Obstet Gynecol Reprod Biol* 84: 103-105.
7. Ugwumadu AHN, Hamid R, Ross LD (1997) Live infant salvaged from a ruptured cornual (interstitial) pregnancy at 33-weeks gestation. *Int J Gynecol Obstet* 58: 247-249.
8. Brewer H, Gefroh S, Munkarah A, Hawkins R, Redman ME (2005) Asymptomatic uterine rupture of a cornual pregnancy in the third trimester: a case report. *J Reprod Med* 50: 715-718.
9. Tanaka Y, Mimura K, Kanagawa T, Nakayama M, Matsuzaki S, et al. (2014) Interstitial pregnancy resulting in a viable infant coexistent with massive perivillous fibrin deposition: a case report and literature review. *Am J Perinatol Rep* 4: 29-32.
10. Weeks AD (2008) The retained placenta. *Best Pract Res Clin Obstet Gynaecol* 22: 1103-1117.
11. Ranney B (1956) Relative atony of myometrium underlying the placental site secondary to high cornual implantation; a major cause of retained placentas. *Am J Obstet Gynecol* 71: 1049-1061.
12. Faraj R, Steel M (2007) Management of cornual (interstitial) pregnancy. *The Obstetrician & Gynaecologist* 9: 249-255.

Author Affiliations

Top

¹Department of Obstetrics and Gynaecology, Singapore General Hospital, Outram Road, 169608, Singapore

Submit your next manuscript and get advantages of SciTechnol submissions

- ❖ 50 Journals
- ❖ 21 Day rapid review process
- ❖ 1000 Editorial team
- ❖ 2 Million readers
- ❖ Publication immediately after acceptance
- ❖ Quality and quick editorial, review processing

Submit your next manuscript at • www.scitechnol.com/submission