



Case Reports

A SCITECHNOL JOURNAL

Long-Term Response After Early Discontinuation Due to Immunotherapy Toxicity in Metastatic Renal Cancer: A Clinical Case and Literature Review

Alessandro Rametta *, Valentina Guadalupi, Elena Verzoni, Giuseppe Procopio

Abstract

Immunotherapy has a cardinal role in renal cancer, both in adjuvant setting and metastatic disease (first or subsequent lines). Severe Immune-Related Adverse Events (irAEs) occur in 10%-27% of patients treated with immunotherapy, but the discontinuation of the treatment due to toxicity doesn't necessarily correlate with poor outcome. We present the case of a woman affected by metastatic clear cell renal cell carcinoma who presented a long-term response to second line treatment with Nivolumab after early interruption due to immuno-toxicity (hepatotoxicity, skin rash, hypothyroidism).

Keywords: Immunotherapy; Renal cell carcinoma; Immune-related adverse events (irAEs); Nivolumab; Treatment response

Background

Immune-checkpoint inhibitors have a central role in the treatment of renal cancer [1-2]. In Europe pembrolizumab (an antibody targeting the Programmed Death receptor-1 – PD-1) is approved by the European Medical Association (EMA) in the adjuvant setting in intermediate-high and high risks of relapse and in M1 NED tumors, according to the Keynote-564 trial [3]. Several first line trials have highlighted the importance of immunotherapy in this setting for clear cell renal cell carcinoma, both alone and in combination with anti-angiogenetic Tyrosine Kinase Inhibitors (TKIs). Nivolumab + ipilimumab (Checkmate-214) is approved by EMA for intermediate and high risk, according to International Metastatic RCC Database Consortium (IMDC) risk model classification; pembrolizumab + axitinib (Keynote-426 trial) (Checkmate-9ER trial) and pembrolizumab + lenvatinib (CLEAR trial) are approved by EMA for all the risk classes, according to IMDC. In a randomized phase III trial, CheckMate 025, nivolumab compared with everolimus in pre-treated patients conferred a 5.4-month improvement of median OS, with a more favorable safety profile [1,4-7]. For the clinical benefit demonstrated with this trial, in April 2016 the EMA approved nivolumab for mRCC patients who had received a prior line of treatment with anti-angiogenic agents. A great number of

trials studying immunotherapy in ccRCC are ongoing in this moment, in all the settings.

Regarding the tolerability to immunotherapy, Immune-Checkpoint Inhibitors (ICIs) induce a peculiar spectrum of toxicities, different from those determined by conventional chemotherapy, caused by an enhanced activity of the immune system and by systemic inflammation: the so-called “Immune-Related Adverse Events” (irAEs) [8]. They can involve different tissues with a wide variety of manifestations, generally mild, even if moderate-severe ones can occur. IrAEs could be dermatological (rash, pruritus), gastrointestinal (colitis with diarrhea, hepatitis, pancreatitis), pulmonary (pneumonitis), endocrine (thyroiditis, diabetes mellitus, hypophysitis), renal (nephritis), and systemic (fever and fatigue) [9]. In mRCC, G3-G4 irAEs develop in 1.7%–19% of patients treated with anti-PD-1 and 1.3% – 10.4% of patients treated with anti-PD-1 + anti CTLA-4. G5 (fatal) irAEs have been reported in almost 0.36% of patients treated with anti PD-1/PD-L1, 1.08% in those treated with anti-CTLA-4, and 1.23% of patients treated with the combination of both [10].

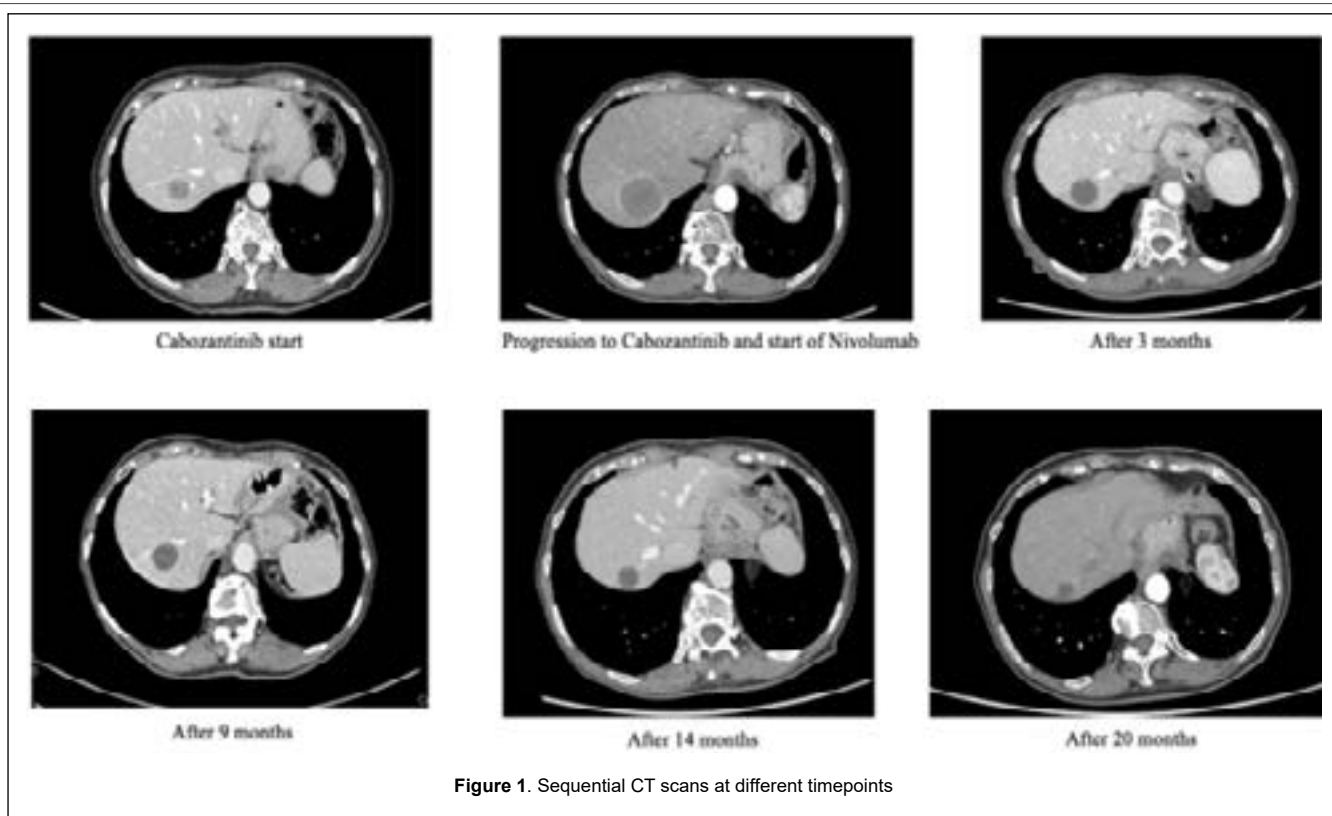
downwards (Figure 1).

Clinical Use

The patient is a 76-year-old Caucasian non-smoker female with hypothyroidism, insulin-dependent diabetes mellitus, vitiligo, and hypertension as comorbidities, all well-controlled with specific therapy. In March 2020, a thorax-abdomen CT scan, performed during follow-up for previous pT1 N0 rectal cancer, revealed a left renal lesion (3.6 cm x 2.9 cm), para-aortic lymphadenopathy, and a liver lesion (1.7 cm). The biopsy of the renal mass suggested a diagnosis of renal cell carcinoma, Clear Cell Variant (ccRCC), and the biopsy of the liver lesion confirmed the diagnosis. No relevant laboratory findings emerged, so the tumor was classified as intermediate risk metastatic renal cancer, according to the International Metastatic RCC Database Consortium (IMDC) score. Therefore, we decided to start first-line treatment with Cabozantinib (according to the results of the CABOSUN study [11]). After 8 months from the start, the CT scan showed progression in both hepatic and renal lesions and the appearance of new retroperitoneal lymphadenopathies. Thus, in February 2021, we started second-line treatment with Nivolumab, according to guidelines. After one cycle, a G2 skin macular rash in the décolleté region and arms appeared, and the laboratory showed G1 asymptomatic hypothyroidism, exacerbation of diabetes mellitus (glycemia 250 mg/dL), worsening of vitiligo, and G3 hepatotoxicity (GOT/GPT 281/527 G3 DR, ALP 210 G1 DR). According to ESMO guidelines, after confirming no relevant risk factors or causes for liver enzyme elevation in the patient's medical history, we carried out HBV and HCV testing and performed a liver US, with negative results. Therefore, high corticosteroid treatment was started (1 mg/kg), and Nivolumab was discontinued. The monitoring of liver enzymes showed normalization in almost a month, and the patient continued with clinical and radiological follow-up. Now, after 3 years without treatment, the patient is still in partial response, highlighting that the disease is still responding to the only cycle of immunotherapy. In the sequence of CT scans performed at different timepoints (Figure 1).

*Corresponding author: Alessandro Rametta, Medical Oncology - Genitourinary Unit, Fondazione IRCCS Istituto Nazionale dei Tumori di Milano, Via Venezian 1, 20133 Milan, Italy, E-mail : alessandro.rametta@istitutotumori.mi.it

Received: January 31, 2023; Manuscript No: COCR-24-126428 Editor Assigned: February 04, 2023; PreQC Id: COCR-24-126428 (PQ) Reviewed: February 08, 2023; QC No: COCR-24-126428 (Q) Revised: February 14, 2023, 2023; Manuscript No: COCR-24-126428 (R) Published: February 19, 2023; DOI: 10.4173/cocr.7(1).333



Literature review on the association between irAEs onset and response to IO

Rational

The rational of the possible correlation between the occurrence of irAEs and response to IO is not clear [12]. The unbalancing of the immune system induced by ICI could be developed by cross-reactivity between tumor neoantigens and normal tissue antigen; concerning CTLA-4 antibodies, ipilimumab possibly induce a non-specific increase in endogenous T-cell response mediated by dendritic cells or paracrine cytokine stimulation furthermore, considering anti-PD-1/PD-L1 inhibitors, they can modulate B cells' activity with the production of auto-antibodies potential causes of irAEs [13,14]. Even if various hypotheses have been formulated, the reason why there is a potential association between irAEs during PD-1/PD-L1 and/or CTLA-4 treatment and response has to be fully understood yet. Another important question still not completely solved is understanding which biomarkers are involved in occurrence of irAEs (and thus potentially to patient's outcome during immunotherapy). Some studies described that in clinical practice, pre-existing organ failure is supposed to be associated to higher risk to develop irAEs as well as pre-existing Auto Immune Disease (AID) [15-19]. Talking about molecular biomarkers, Tahrini et al. described that the baseline circulating Interleukin (IL)-17 was related to G3-G4 colitis [20]. Other studies focused on the gut microbiome: significant differences in microbial diversity and composition have been noted between responding and non-responding melanoma patients treated with anti-PD-1 therapy, suggesting that different species may be enriched in responding versus non-responding patients [21,22].

Multipatolgy and RCC studies

Among the last 20 years, more than 50 studies about the correlation between irAEs and outcome (in terms of ORR, PFS and OS) were conducted [23]. Most of the studies regarded melanoma and lung cancers, while only a few were about renal cell carcinomas. Even if earlier

studies in melanoma patients suggested no association between irAE onset and anti-cytotoxic T-lymphocyte-associated protein 4 (CTLA-4) antibody efficacy subsequent bigger and multi-pathology studies demonstrated a relationship irAEs / response to IO [24-25].

A secondary analysis of CA209-003 trial, studying the 5-year outcomes in patients with renal cell cancers, lung cancers and melanomas, resulted in an overall survival significantly longer among patients with treatment-related AEs of any grade (median, 19.8 months; 95% CI, 13.8 months-26.9 months or grade 3 or more (median, 20.3 months; 95% CI, 12.5 months-44.9 months) = compared with those without treatment-related AEs (median, 5.8 months; 95% CI, 4.6 months-7.8 months) ($P < .001$ for both comparisons based on hazard ratios) [26]. Another retrospective analysis of 157 patients with different histologies demonstrated a PFS benefit, regardless the use of systemic corticosteroid [27].

A prospective study on 73 NSCLC patients treated with immunotherapy displayed that autoimmune skin toxic effects were more frequent in patients with complete remission or partial remission (68.2% [95% CI, 47.3%-83.6%]) than those with progressive or stable disease (19.6% [95% CI, 11.0% - 32.5%]) [28]. Rogado et al, studied patients treated with single-agent nivolumab or pembrolizumab for advanced cancer; among 106 patients, irAEs were observed in 40 patients; 33 of the 40 patients with irAEs had objective response (82.5%) in contrast with 11 of the 66 cases without irAEs (16.6%) (OR 23.5, $p < 0.000001$). PFS in patients with irAEs was 10 months and 3 months in those without irAEs (HR 2.2, $p < 0.016$). OS was 32 months and 22 months in patients with irAEs and in those without irAEs, respectively, without statistically significant differences [29]. Other studies with melanoma or lung cancers highlighted more or less the same results [30-35].

Regarding RCC, a few studies were conducting; according to Verzoni et al, patients treated with Nivolumab in subsequent setting who developed irAEs (early or late onset) versus those ones who didn't develop irAEs had a more significant survival benefit (median OS not reached versus 16.8 months, $p = 0.002$) [36]. The occurrence of irAEs displayed a strong association with OS in univariable (HR 0.48, $p = 0.003$) and multivariable (HR 0.57, $p = 0.02$) analysis. A retrospective

study tested Body Mass Index (BMI), irAEs and gene expressions as potential biomarkers associated with resistance and outcomes in RCC [37]. In 90 patients treated with either pembrolizumab, nivolumab or atezolizumab, 26.7% developed irAE median PFS was 20.5 months vs 10.1 months in irAE+ versus irAE- patients (HR 0.42, 95% CI 0.17 – 0.99, $p=0.04$); however, no difference in median OS was noted (28.73 versus 30.67 months in irAE+ versus irAE – patients, respectively (HR 0.80, 95% CI 0.20 – 3.19, $p=0.75$). Elias et al. studied 90 metastatic RCC patients treated with various ICIs [36]; median OS was 35.9 months versus 26.5 months in irAE + versus irAE- patients (HR 0.376 – 95% CI 0.179 – 0.792; $p=0.010$) [38].

Implication of onset time of irAEs

The implications of timing of irAE onset and ICI efficacy have been much less studied. Previously referenced studies in NSCLC and gastrointestinal cancer patients have not demonstrated a relationship between earlier irAE onset and increased ICI response. A study in melanoma patients also did not demonstrate this relationship [39]. On the other hand, another previous study conducted by Rogado et al on G3-4 irAEs seem to be related to efficacy of IO even when treatment is early interrupted due to toxicities [29].

Recently, Stellato et al, demonstrated the efficacy of IO even after early interruption due to irAEs [40]. In this study, the author retrospectively collected data from 204 mRCC patients treated with ICIs in 6 Italian referral centers adhering to the Meet-Uro group, comparing those who had early severe (G3-G4) irAEs (study group, $n=18$) with those who had not (control group, $n=186$). Among the study group, 12/18 (66.6%) were free from progression at 6 months since IO interruption, TTF was 1.6 months (95% CI 1.6 – 2.1), mPFS was 7.4 months (95% CI 3.16–11.6) and mOS was 15.5 months (5.1–25.8). In the control group 111/184 (60.3%) patients were free from progression at 6 months, TTF was 4.6 months (95% CI 3.5–5.6), mPFS was 4.6 months (95% CI 3.5–5.6) and mOS was 19.6 months (95% CI 15.1–24.0).

Discussion

The presented case underscores the complex association between immune-related Adverse Events (irAEs) and treatment outcomes in metastatic clear Cell Renal Cell Carcinoma (ccRCC). Immunotherapy has revolutionized the treatment landscape of renal cancer, offering new avenues for patients with advanced disease. However, the efficacy of these treatments must be carefully balanced with their potential for inducing irAEs, which can range from mild to life-threatening. In this

case, the patient demonstrated a remarkable response to second-line treatment with Nivolumab despite experiencing early discontinuation due to immune-related toxicities, including hepatotoxicity, skin rash, hypothyroidism, and exacerbation of pre-existing conditions (diabetes mellitus and vitiligo). The association between irAEs and treatment response remains an area of active investigation. While irAEs can pose significant challenges in clinical practice, emerging evidence suggests that their occurrence may correlate with improved outcomes in certain cancer types, including renal cell carcinoma. Studies have demonstrated prolonged overall survival and progression-free survival in patients experiencing treatment-related adverse events, underscoring the potential predictive value of irAEs as surrogate markers of response to immunotherapy.

However, the mechanisms underlying this association are not fully elucidated, and further research is warranted to better understand the complex immunological dynamics at play. Additionally, the implications of the timing and severity of irAEs on treatment efficacy require further investigation to optimize patient outcomes while minimizing treatment-related toxicity.

Conclusion

In conclusion, this case underscores the importance of individualized patient management in particular during immunotherapy treatment and the potential role of irAEs as surrogate markers of response to immunotherapy in metastatic renal cell carcinoma. By better understanding and harnessing the immunological dynamics at play, we can continue to advance personalized treatment approaches and improve outcomes for patients with advanced renal cancer.

Abbreviations

(irAEs) Immune-Related Adverse Events, (EMA) European Medical Association, (PD-1) Programmed Death Receptor-1, (PD-L1) Programmed Death Ligand-1, (CTLA-4) Cytotoxic T-Lymphocyte Antigen 4, (TKI) Tyrosine Kinase Inhibitor, (NED) No Evidence of Disease, (ccRCC) Clear Cells Renal Cell Carcinoma, IMDC: International Metastatic RCC Database Consortium, (GOT) Glutamate Oxaloacetate Transaminase, (GPT) Glutamate Pyruvate Transaminase, (ALP) Alkaline Phosphatase, (DR) Drug Related, (AID) Autoimmune Disease; (ORR) Objective Response Rate, (PFS) Progression Free Survival, (OS) Overall Survival; (HR) Hazard Ratio, and (BMI) Body Mass Index.

References

1. Motzer Robert J, Bernard Escudier, David F. McDermott, Saby George, Hans J. Hammers, et al. (2015) Nivolumab versus everolimus in advanced renal-cell carcinoma. *N Engl J Med* 373:1803-1813.
2. Motzer RJ, Tannir NM, McDermott DF, Aren Frontera O, Melichar B, et al. (2018). Nivolumab plus ipilimumab versus sunitinib in advanced renal-cell carcinoma. *N Engl J Med* 378: 1277-1290.
3. Choueiri TK, Tomczak P, Park SH, Venugopal B, Ferguson T, et al. (2021). Adjuvant pembrolizumab after nephrectomy in renal-cell carcinoma. *N Engl J Med* 385: 683-694.
4. Rini BI, Plimack ER, Stus V, Gafanov R, Hawkins R, et al. (2019). Pembrolizumab plus axitinib versus sunitinib for advanced renal-cell carcinoma. *N Engl J Med* 380: 1116-1127.
5. Choueiri TK, Powles T, Burotto M, Escudier B, Bourlon MT, et al. (2021). Nivolumab plus cabozantinib versus sunitinib for advanced renal-cell carcinoma. *N Engl J Med* 384: 829-841.
6. Motzer R, Alekseev B, Rha SY, Porta C, Eto M, et al. (2021). Lenvatinib plus pembrolizumab or everolimus for advanced renal cell carcinoma. *N Engl J Med* 384: 1289-1300.
7. Escudier B, Sharma P, McDermott DF, George S, Hammers HJ, et al (2017). CheckMate 025 randomized phase 3 study: outcomes by key baseline factors and prior therapy for nivolumab versus everolimus in advanced renal cell carcinoma. *Eur urol* 72: 962-971.
8. Abidin SM, Zaher DM, Arafa ESA, & Omar, HA. (2018). Tackling cancer resistance by immunotherapy: updated clinical impact and safety of PD-1/PD-L1 inhibitors. *Cancers* 10: 32.
9. Brahmer JR, Lacchetti C, Schneider BJ, Atkins MB, Brassil KJ, et al. (2018). Management of immune-related adverse events in patients treated with immune checkpoint inhibitor therapy: American Society of Clinical Oncology Clinical Practice Guideline. *J Clin Oncol: off j Am Soc Clin Oncol* 36: 1714.
10. Wang DY, Salem JE, Cohen JV, Chandra S, Menzer C, et al. (2018). Fatal toxic effects associated with immune checkpoint inhibitors: a systematic review and meta-analysis. *JAMA oncology* 4: 1721-1728.
11. Choueiri TK, Halabi S, Sanford BL, Hahn O, Michaelson MD, et al. (2017). Cabozantinib versus sunitinib as initial targeted therapy for patients with metastatic renal cell carcinoma of poor or intermediate risk: the alliance A031203 CABOSUN trial. *J Clin Oncol* 35: 591.
12. Michot JMC, Bigenwald S, Champiat M Collins, F Carbonnel, S. Postel-Vinay, A. Berdelou et al. (2016) Immune-related adverse events with immune checkpoint blockade: a comprehensive review. *Eur J Cancer* 54: 139-148.
13. JCY. (2007). Ipilimumab (anti-CTLA4 antibody) causes regression of metastatic renal cell cancer associated with enteritis and hypophysitis. *J. Immunother* 30: 825-830.
14. Suzuki S, Ishikawa N, Konoeda F, Seki N, Fukushima S, et al. (2017). Nivolumab-related myasthenia gravis with myositis and myocarditis in Japan. *Neurology* 89: 1127-1134.
15. Abdel-Wahab N, Shah M, Lopez-Olivo MA, & Suarez-Almazor ME. (2018). Use of immune checkpoint inhibitors in the treatment of patients with cancer and preexisting autoimmune disease: a systematic review. *Ann Intern Med* 168: 121-130.
16. Johnson DB, Sullivan RJ, Ott PA, Carlino MS, Khushalani NI, et al. (2016). Ipilimumab therapy in patients with advanced melanoma and preexisting autoimmune disorders. *JAMA Oncol* 2: 234-240.
17. Menzies AM, Johnson DB, Ramanujam S, Atkinson VG, Wong ANM, et al. (2017). Anti-PD-1 therapy in patients with advanced melanoma and preexisting autoimmune disorders or major toxicity with ipilimumab. *Ann Oncol* 28: 368-376.
18. Gutzmer R, Koop A, Meier F, Hassel JC, Terheyden P, et al. (2017). Programmed cell death protein-1 (PD-1) inhibitor therapy in patients with advanced melanoma and preexisting autoimmunity or ipilimumab-triggered autoimmunity. *Eur J Cancer* 75: 24-32.
19. Tison A, Quere G, Misery L, Funck-Brentano E, Danlos FX, et al. (2019). Safety and efficacy of immune checkpoint inhibitors in patients with cancer and preexisting autoimmune disease: a nationwide, multicenter cohort study. *Arthritis Rheumatol* 71: 2100-2111.
20. Tarhini AA, Zahoor H, Lin Y, Malhotra U, Sander C, et al. (2015). Baseline circulating IL-17 predicts toxicity while TGF- β 1 and IL-10 are prognostic of relapse in ipilimumab neoadjuvant therapy of melanoma. *J Immunother Cancer* 3: 1-6.
21. Gopalakrishnan V, Spencer CN, Nezi L, Reuben A, Andrews MC, et al. (2018). Gut microbiome modulates response to anti-PD-1 immunotherapy in melanoma patients. *Science* 359: 97-103.
22. Matson V, Fessler J, Bao R, Chongsuwat T, Zha Y, et al. (2018). The commensal microbiome is associated with anti-PD-1 efficacy in metastatic melanoma patients. *Science* 359: 104-108.
23. Hussaini S, Chehade R, Boldt RG, Raphael J, Blanchette P, et al. (2021). Association between immune-related side effects and efficacy and benefit of immune checkpoint inhibitors—a systematic review and meta-analysis. *Cancer Treat Rev* 92: 102134.
24. Ascierto PA, Simeone E, Sileni VC, Pigozzo J, Maio M, et al. (2014). Clinical experience with ipilimumab 3 mg/kg: real-world efficacy and safety data from an expanded access programme cohort. *J Transl Med* 12: 1-7.
25. Downey SG, Klapper JA, Smith FO, Yang JC, Sherry RM, et al. (2007). Prognostic factors related to clinical response in patients with metastatic melanoma treated by CTL-associated antigen-4 blockade. *Clin Cancer Res* 13: 6681-6688.
26. Topalian SL, Hodi FS, Brahmer JR, Gettinger SN, Smith DC, et al. (2019). Five-year survival and correlates among patients with advanced melanoma, renal cell carcinoma, or non-small cell lung cancer treated with nivolumab. *JAMA oncol* 5: 1411-1420.
27. Shafiqat H, Gourdin T, & Sion A. (2018). Immune-related adverse events are linked with improved progression-free survival in patients receiving anti-PD-1/PD-L1 therapy. In *Seminars in Oncology* 45:156-163.
28. Berner F, Bomze D, Diem S, Ali OH, Fässler M, et al. (2019). Association of checkpoint inhibitor-induced toxic effects with shared cancer and tissue antigens in non-small cell lung cancer. *JAMA Oncol* 5: 1043-1047.
29. Rogado J, Sanchez-Torres JM, Romero-Laorden N, Ballesteros AI, Pacheco-Barcia V, et al. (2019). Immune-related adverse events predict the therapeutic efficacy of anti-PD-1 antibodies in cancer patients. *Eur J Cancer* 109: 21-27.
30. Eggermont AM, Kicinski M, Blank CU, Mandala M, Long GV, et al. (2020). Association between immune-related adverse events and recurrence-free survival among patients with stage III melanoma randomized to receive pembrolizumab or placebo: a secondary analysis of a randomized clinical trial. *JAMA Oncol* 6: 519-527.
31. Osorio JC, Ni A, Chaff JE, Pollina R, Kasler MK, et al. (2017). Antibody-mediated thyroid dysfunction during T-cell checkpoint blockade in patients with non-small-cell lung cancer. *Ann Oncol* 28: 583-589.
32. Abu-Sbeih H, Ali FS, Qiao W, Lu Y, Patel S, et al. (2019). Immune checkpoint inhibitor-induced colitis as a predictor of survival in metastatic melanoma. *Cancer Immunol Immunother* 68: 553-561.
33. Campredon P, Mouly C, Lusque A, Bigay-Game L, Bousquet E, et al. (2019). Incidence of thyroid dysfunctions during treatment with nivolumab for non-small cell lung cancer: Retrospective study of 105 patients. *Presse Med* 48:199-207.
34. Fukihara J, Sakamoto K, Koyama J, Ito T, Iwano S, et al. (2019). Prognostic impact and risk factors of immune-related pneumonitis in patients with non-small-cell lung cancer who received programmed death 1 inhibitors. *Clin Lung Cancer* 20: 442-450.
35. Indini A, Di Guardo L, Cimminiello C, Prisciandaro M, Randon G, et al. (2019). Immune-related adverse events correlate with improved survival in patients undergoing anti-PD1 immunotherapy for metastatic melanoma. *J Cancer Res Clin Oncol* 145: 511-521.
36. Verzoni E, Carteni G, Cortesi E, Giannarelli D, De Giglio A, et al. Nivolumab Renal Cell Cancer Early Access Program group. (2019). Real-world efficacy and safety of nivolumab in previously-treated metastatic renal cell carcinoma, and association between immune-related adverse events and survival: the Italian expanded access program. *J Immunother Cancer* 7: 1-9.
37. Labadie BW, Liu P, Bao R, Crist M, Fernandes R, et al. (2019). BMI, irAE, and gene expression signatures associate with resistance to immune-checkpoint inhibition and outcomes in renal cell carcinoma. *J Transl Med* 17: 1-12.

38. Das S, & Johnson DB. (2019). Immune-related adverse events and anti-tumor efficacy of immune checkpoint inhibitors. *J Immunother Cancer* 7: 1-11.
39. Dearden H, Au L, Wang DY, Zimmer L, Eroglu Z, et al. (2021). Hyperacute toxicity with combination ipilimumab and anti-PD1 immunotherapy. *Eur J Cancer* 153: 168-178.
40. Stellato M, Procopio G, De Giorgi U, Maruzzo M, Bimbatti D, et al. (2021). Clinical outcome of renal cancer patients who early interrupted immunotherapy due to serious immune-related adverse events. Meet-Uro 13 trial on behalf of the MeetUro investigators. *J Transl Med* 19: 1-6.

Author Affiliations^{Top}

¹Medical Oncology - Genitourinary Unit, Fondazione IRCCS Istituto Nazionale dei Tumori di Milano, Via Venezian 1, 20133 Milan, Italy.