



**Case Report**

A SCITECHNOL JOURNAL

## Malignant Spermatic Cord Tumor as a Rare Scrotal Lesion: Case Report and Literature Review

Draeger DL<sup>1\*</sup>, Erbersdobler A<sup>2</sup>, Protzel C<sup>1</sup> and Hakenberg O<sup>1</sup>

### Abstract

Malignant tumors of the spermatic cord are urologic rarities. Due to their rarity the therapeutic management is often inconsistent and characterized by individual clinical decisions. The treatment of choice is inguinal orchiectomy with extensive resection of the surrounding soft tissue. These neoplasms occur mostly in elderly patients. We report two patients who presented with scrotal masses and review what is currently known about this entity.

### Keywords

Paratesticular tumors; Spermatic cord tumors; Surgery; Radiotherapy; Chemotherapy

### Background

Malignant tumors of the spermatic cord are rare. They are mostly of mesenchymal origin treatment of choice is high inguinal orchiectomy with extensive resection of the surrounding soft tissue. They occur in elderly men (mean age at diagnosis around 65 years) and most commonly in Caucasians (86.7%). The localized tumors have a potential for (early) lymphatic metastasis (>29%). The histological findings are heterogeneous: liposarcoma (46.4%), leiomyosarcoma (20%), histiocytoma (13%) and rhabdomyosarcoma (9%). The rhabdomyosarcoma variant is more common in younger patients (mean age around 26 years).

### Case Reports

We report two patients (65 and 82 years old) who presented with an asymptomatic, paratesticular small mass for diagnosis and treatment. Both patients had a slowly enlarging painless paratesticular mass. On examination, both had a solid, indolent intrascrotal mass, which was clearly separated from the testis and epididymis. Otherwise physical examination was normal in both cases, as was blood chemistry including relevant tumor markers. Ultrasound showed an inhomogeneous tumor structure with normal testis and epididymis. Due to the growing nature of the lesions, surgical exploration was done in both cases and the lesions were removed with wide resection margins. Histology showed a liposarcoma (Figure 1) of the spermatic cord in the 82-year-old patient and a leiomyosarcoma (Figure 2)

in the 65-year-old patient. Surgical margins were negative, the postoperative courses were uneventful and no adjuvant treatment was done. Both patients follow close follow-up due to the high tendency for recurrence.

**Discussion:** In the literature there 185 case reports of liposarcomas of the spermatic cord. A diagnosis based on clinical examination is impossible, palpation of a non-tender mass being the usual findings can [1-5]. Ultrasound should be done as the primary imaging modality clearly distinguishing the mass from the testis and epididymis; its sensitivity for differentiating intratesticular from extratesticular lesions is high (95-100%) [6]. The malignant character is suggested by the solid nature of the lesion and the history of slow enlargement. The differential diagnosis are cystic lesions (funiculocele, hydrocele) but ultrasound can exclude these [1,7-9]. Paratesticular sarcomas usually have a heterogeneous structure and may appear hypervascular if Doppler sonography is done [8,10]. Liposarcomas often have a heterogeneous appearance on ultrasound due to variable amounts of adipose tissue contained [8,10]. Leiomyosarcomas, in contrast, often appear as well-defined masses with a dense connective appearance which may, however, show intratumoral bleeding, necrosis or cystic degeneration [11]. Thus, although sonography is useful with respect to the definition of the extra-testicular origin of the mass, sonographic findings are often variable and unspecific. With regard to tumor size, delineation and pattern of echogenicity there are no clear sonographic diagnostic criteria.

Further imaging is therefore useful if such a tumor is suspected and MRI is most useful for scrotal pathology [5,8]. PET-CT (FDG-PET) can identify dedifferentiated liposarcoma but this has not been established for clinical routine [12]. Likewise, although described, a role of fine needle aspiration cytology in the diagnosis of spermatic cord tumors is not clearly defined [13,14].

Since the spermatic cord is derived from the mesoderm, 90% of all neoplasms of the spermatic cord are sarcomas [15]. The first paratesticular sarcoma was described by Lesauvage in 1845. Overall, there are different histological variants: liposarcoma (46.4%), leiomyosarcoma (20%), histiocytoma (13%) and rhabdomyosarcoma (9%) [1,3].

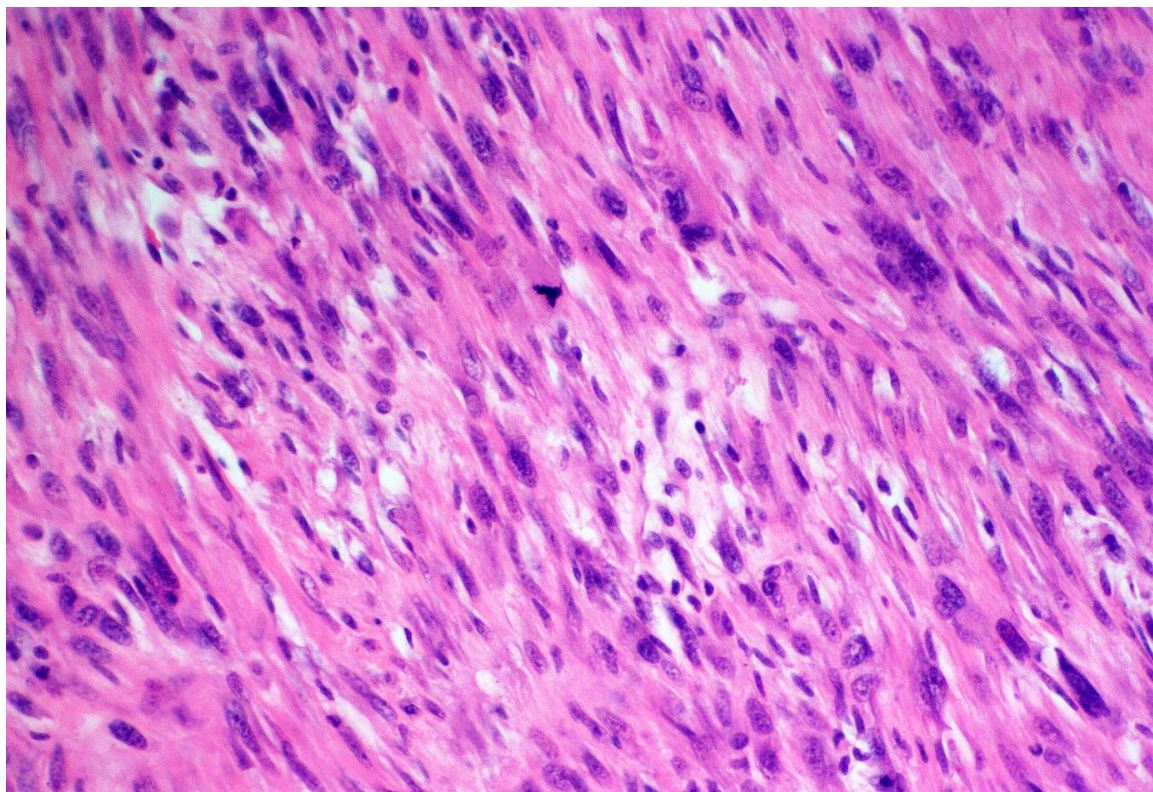
Liposarcomas are most common. The WHO classifies five categories in order of increasing malignancy: well differentiated, dedifferentiated, myxoid, round-cell and pleomorphic. Most liposarcomas are well differentiated, low-grade disease without or only with minimal tendency to metastasize but they can be locally invasive [16]. Most patients acquire this disease in the fifth or sixth decade of life.

With 20%, leiomyosarcomas are the second most common entity, with a peak incidence in the 6th and 7th decade of life. The tumor is derived from the smooth muscle of the vas deferens, blood vessels or the cremaster muscle [17]. Local recurrence is common (50%), despite radical surgery [18,19]. This high rate of recurrence can be reduced by adjuvant radiation. The risk of relapse is related to tumor size, surgical margin status, inguinal location of the tumor, histological dedifferentiation and depth of invasion [1,2,20,21]. Local recurrence is occurs at the residual spermatic cord, the scrotum and the surrounding pelvic tissues, with or without lymph node involvement.

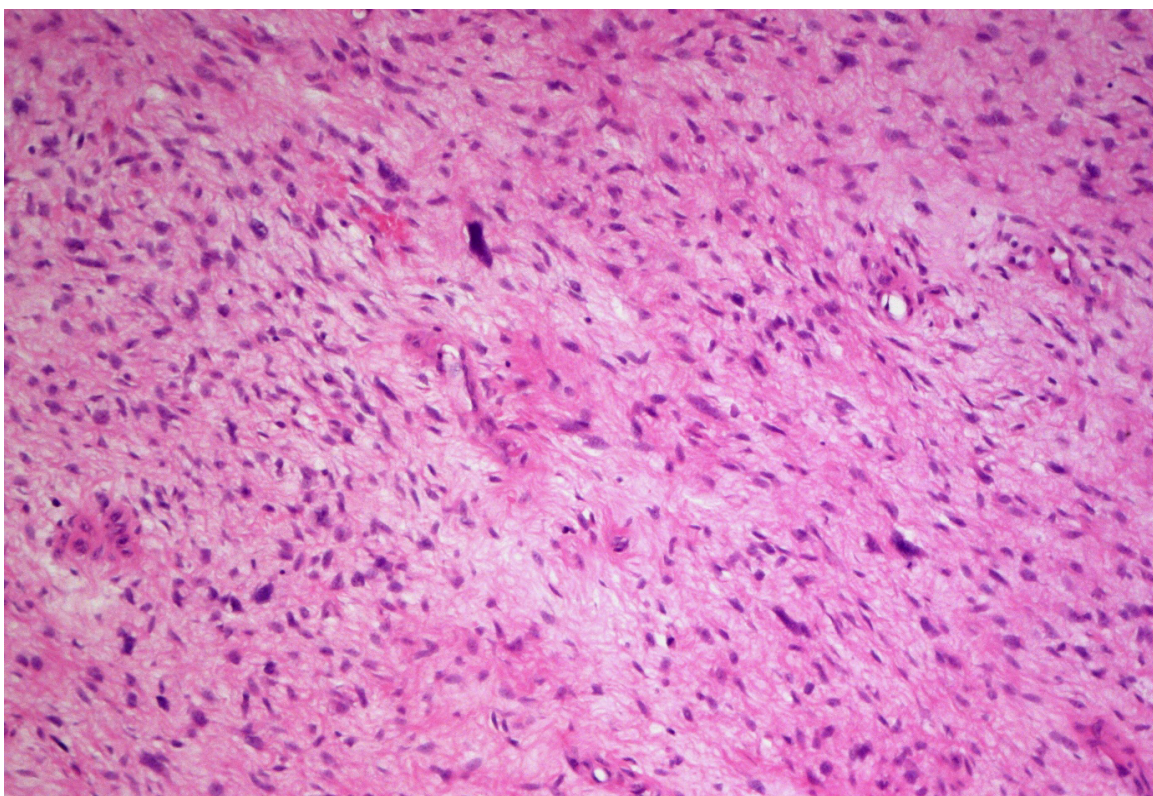
\*Corresponding author: Désirée Louise Dräger, MD, Dept of Urology, University of Rostock, Ernst-Heydemann-Strasse 6, 18057 Rostock, Germany, Tel: 0381 494 7819; E-mail: Desiree-Louise.Draeger@med.uni-rostock.de

Received: May 09, 2016 Accepted: July 13, 2016 Published: July 20, 2016





**Figure 1:** Leiomyosarcoma of the tunica vaginalis testis: The tumor is composed of spindle cells with moderate cellular atypia and scattered mitoses. Hematoxylin & Eosin; Original magnification 200x.



**Figure 2:** Histologic sections showing areas of well differentiated lipomatous tumor with lipoblasts (A) and areas resembling myxofibrosarcoma (B), consistent with the diagnosis of dedifferentiated liposarcoma (hematoxylin & eosin, original magnification 100x in both pictures).



If the lesion occurs in the spermatic cord, a recurrence generally extends along the spermatic cord through the internal inguinal ring into the pelvis. Lymphatic metastases are usually in pelvic and/or para-aortic lymph nodes. Hematogenous spread occurs to the liver and lungs. Late recurrences in the form of distant metastasis are not uncommon, and have been described after 15 years in 42%. Thus, long-term follow-up is required. Patients should be monitored closely for a minimum of 36 months with further, less frequent regular follow-up for 15 years [1]. Follow-up should include chest X-rays and CT scans.

There is no standard treatment protocol as there is no consensus on standardized surgical or adjuvant treatment. Treatment of choice is radical surgical excision (inguinal orchiectomy) [3]. The extent of resection of the surrounding connective tissue is controversial [1]. Certainly a simple excision correlates with a high likelihood of recurrence because these tumors have a “pseudo-capsule” with penetration of tumor cells into the periphery. However, to the anatomical boundaries of the inguinal region a very extensive resection is usually not possible.

Regarding adjuvant treatment there are also no clear standards. The role of prophylactic lymphadenectomy is controversial. Although regularly performed in some centers, the true incidence of para-aortic and pelvic lymph node metastases is unknown [20]. A consensus exists regarding the indication for retroperitoneal lymphadenectomy (pelvic, inguinal and paraaortic) for liposarcoma and leiomyosarcoma of the spermatic cord although such extensive lymphadenectomy carries some morbidity. The role of adjuvant radiotherapy and chemotherapy is also under discussed [1,3]. Patients with high risk tumors and a high risk of recurrence will usually benefit from adjuvant radiotherapy. Also, the general use of prophylactic radiotherapy after surgical resection with negative surgical margins has been described to reduce the local recurrence rate. The rationale for this is that due to the anatomy of the region limiting very radical surgery, adjuvant radiotreatment should be recommended. The radiation field is the inguinal canal and the ipsilateral pelvis and scrotum [1,18,21]. Although this concept seems plausible there is no study large enough to support this strategy on an evidence basis [1]. There are also not enough data regarding the proper radiation dose [22]. The currently recommended dose is 60-65 Gy over 6 weeks [1,18]. For the use of radiotherapy as a neoadjuvant treatment, there is no evidence that this improves outcomes.

Systemic chemotherapy has no clear role except for the treatment of juvenile rhabdomyosarcoma [23]. Rhabdomyosarcomas are the only paratesticular tumors which show a significant response in all stages to combination chemotherapy with vincristine, dactinomycin and ifosfamide/cyclophosphamide.

The prognosis is as varied as the treatment is. Kyle (1966) reported a 5-year survival of 10-15% [24], but more recent data suggest a much better 5-year survival of approximately 50-80% which may be attributed to improved diagnosis and treatment. The prognosis depends on early diagnosis and treatment, as well as tumor stage and -grading and metastatic spread at diagnosis and

the first treatment modality. Adjuvant radiotherapy is certainly needed for undifferentiated tumors and for recurrences but is probably beneficial for more cases. The role of extensive lymphadenectomy is controversial. Only rhabdomyosarcoma in young patients has been shown to benefit from multimodal treatment with surgery, adjuvant radiotherapy and multimodal chemotherapy. Due to the high risk of recurrence close and long-term follow-up is necessary.

## References

- Ballo MT, Zagars GK, Pisters PW, Feig BW, Patel SR, et al. (2001) Spermatic cord sarcoma: outcome, patterns of failure and management. *J Urol* 166: 1306-1310.
- Froehner M, Koch R, Lossnitzer A, Schober RR, Schuler M, et al. (2014) Adult inguinoscrotal sarcomas: outcome analysis of 21 cases, systematic review of the literature and meta-analysis. *World J Urol* 32: 445-451.
- Coleman J, Brennan MF, Alektiar K, Russo P (2003) Adult spermatic cord sarcomas: management and results. *Ann Surg Oncol* 10: 669-675.
- Montgomery E, Fisher C (2003) Paratesticular liposarcoma: a clinicopathologic study. *Am J Surg Pathol* 27: 40-47.
- Woodward PJ, Schwab CM, Sesterhenn IA (2003) From the archives of the AFIP: extratesticular scrotal masses: radiologic-pathologic correlation. *Radiographics* 23: 215-240.
- Frates MC, Benson CB, DiSalvo DN, Brown DL, Laing FC, et al. (1997) Solid extratesticular masses evaluated with sonography: pathologic correlation. *Radiology*. 204: 43-46.
- Chintamani, Tandon M, Khandelwal R, Jain S, Narayan N, et al. (2010) Liposarcoma of the spermatic cord: a diagnostic dilemma. *JRSM Short Rep* 1: 49.
- Akbar SA, Sayyed TA, Jafri SZ, Hasteh F, Neill JS. (2003) Multimodality imaging of paratesticular neoplasms and their rare mimics. *Radiographics* 23: 1461-1476.
- Blaivas M, Brannam L (2004) Testicular ultrasound. *Emerg Med Clin North Am* 22: 723-748.
- Secil M, Kefi A, Gulbahar F, Aslan G, Tuna B, et al. (2004) Sonographic features of spermatic cord leiomyosarcoma. *J Ultrasound Med* 23: 973-976.
- Kyrtzi I, Lolis E, Antypa E, Lianou MA, Exarhos D (2011) Imaging features of a huge spermatic cord leiomyosarcoma: Review of the literature. *World J Radiol* 3: 114-119.
- Lipset RE, Kirpekar M, Cooke KS, Abiri MM (1997) US case of the day. Myxoid liposarcoma of the spermatic cord. *Radiographics* 17: 1316-1318.
- Dalla Palma P, Barbazza R (1990) Well-differentiated liposarcoma of the paratesticular area: report of a case with fine-needle aspiration preoperative diagnosis and review of the literature. *Diagn Cytopathol* 6: 421-426.
- Bosch-Príncipe R, Martínez-González S, Alvaro-Naranjo T, Castellano-Megías VM, Salvadó-Usach MT, et al. (2000) Fine needle aspiration and touch imprint cytology of a malignant fibrous histiocytoma of the spermatic cord. Case report. *Acta Cytol* 44: 423-428.
- Arlen M, Grabstald H, Whitmore WF Jr. (1969) Malignant tumors of the spermatic cord. *Cancer* 23: 525-532.
- Schwartz SL, Swierzewski SJ 3<sup>rd</sup>, Sondak VK, Grossman HB (1995) Liposarcoma of the spermatic cord: report of 6 cases and review of the literature. *J Urol* 153: 154-157.
- Avila PJ, Capell González M, Muniesa Calderó M, Yelletisch Araño A, Badía Torroella F, et al. (1993) Leiomyosarcoma of the spermatic cord. *Actas Urol Esp* 17: 464-467.
- Fagundes MA, Zietman AL, Althausen AF, Coen JJ, Shipley WU (1996) The management of spermatic cord sarcoma. *Cancer* 77: 1873-1876.
- Merimsky O, Terrier P, Bonvalot S, Le Pechoux C, Delord JP, et al. (1999) Spermatic cord sarcoma in adults. *Acta Oncol* 38: 635-638.
- Folpe AL, Weiss SW (2000) Paratesticular soft tissue neoplasms. *Semin Diagn Pathol* 17: 307-318.

## Summary

Despite their rarity malignant spermatic cord tumors are an important differential diagnosis of scrotal masses. The majority of neoplasms of the spermatic cord are of mesenchymal origin, therefore sarcomas and about 30% are malignant. There are few clear treatment standards due to the rarity of the disease with evidence consisting of small series and case reports. Radical surgery with wide resection margins are

21. Rabbani F, Wright JE, McLoughlin MG (1997) Sarcomas of the spermatic cord: significance of wide local excision. *Can J Urol* 4: 366-376.
22. Banowsky LH, Shultz GN (1970) Sarcoma of the spermatic cord and tunicas: review of the literature, case report and discussion of the role of retroperitoneal lymph node dissection. *J Urol* 103: 628-631.
23. Stewart RJ, Martelli H, Oberlin O, Rey A, Bouvet N, et al. (2003) Treatment of children with nonmetastatic paratesticular rhabdomyosarcoma: results of the Malignant Mesenchymal Tumors studies (MMT 84 and MMT 89) of the International Society of Pediatric Oncology. *J Clin Oncol* 21: 793-798.
24. Kyle VN (1996) Leiomyosarcoma of the spermatic cord: a review of the literature and report of an additional case. *J Urol* 96: 795-800.

### Author Affiliations

[Top](#)

<sup>1</sup>Department of Urology, University of Rostock, Ernst-Heydemann-Strasse 6, 18057 Rostock, Germany

<sup>2</sup>Institute of Pathology, University Rostock, Germany

### Submit your next manuscript and get advantages of SciTechnol submissions

- ❖ 50 Journals
- ❖ 21 Day rapid review process
- ❖ 1000 Editorial team
- ❖ 2 Million readers
- ❖ Publication immediately after acceptance
- ❖ Quality and quick editorial, review processing

Submit your next manuscript at • [www.scitechnol.com/submission](http://www.scitechnol.com/submission)

This article is published in the special issue **Testicular Dysgenesis Syndrome: Past, Present and Future** and has been edited by Dr. Lawrence S. Ames, Wright State University Boonshoft School of Medicine, USA