



Case Report

A SCITECHNOL JOURNAL

Mature Teratomas of the Lesser Omentum

Xiaoqian Lu, Ying Liu and Dianbo Cao*

Department of Radiology, The First Hospital of Jilin University, Chang Chun, China

*Correspondence author: D Cao, Department of Surgery, The First Hospital of Jilin University, No.71 Xinmin Street, Chang Chun, China 130021, Tel: 15804300125; E-mail: caotianbo@126.com

Received date: February 19, 2018; Accepted date: April 02, 2018; Published date: April 09, 2018

Abstract

This article describes huge mature teratomas in the lesser omentum, rarely reported in the literatures. Non-enhanced CT scan showed characteristic imaging findings and a correct diagnosis was achieved before operation. Although there are some debates regarding the origin of teratomas in this patient, but operative findings and pathological examination of resected specimen confirms its origin to be from the lesser omentum instead of the pancreas. The CT images will improve our clinical recognition for this rare disease entity. These images are instructive and educative.

Keywords Mature teratomas; Lesser omentum; CT; Treatment

Case Report

A 39-year-old female was admitted to our hospital complaining of intermittent distending pain in the epigastrium for 1 month. She denied the history of any disease or surgery. On admission, there was no mass detected on palpation. Preoperative laboratory test results were normal, and tumour marker tests revealed no elevation of cancer antigen. Abdominal CT scan showed a cystic-solid mass in the lesser omentum, which also contained calcified and adipose components. The mass compressed and displaced adjacent organs (Figures 1 and 2). Based on typical CT imaging characteristics, mature teratomas were diagnosed before operation. At laparotomy, an encapsulated mass measuring 13cm×10cm was found in the region of lesser omentum after opening gastrocolic ligament. Fully dissecting mass from adjacent structures, we could feel pulsatile motion on its surface. Sebum-like liquid came out and two solid milky-white nodules along with hair were seen within the mass when the surface was cut open (Figure 3). Most of the wall of cystic-solid mass was removed, leaving only a small portion of residual cystic wall attached to the pancreatic head. Histopathological examination of the excised tumor was consistent with typical pattern of benign mature teratomas (Figures 4) and there was no evidence of a malignant germ cell component. Postoperative course was uneventful and the patient remained free of disease on the 1 year follow-up.

It is generally accepted that teratomas arise from germ cells that fail to mature normally in the gonads. These totipotent cells can differentiate into tissue components representing derivatives of mesoderm, ectoderm and endoderm. Macroscopically, teratomas can be divided into either mature or immature types [1]. Mature cystic teratomas are cystic tumors composed of well-differentiated

derivations from at least two of the three germ cell layers. Teratomas may develop in multiple locations such as the ovaries, the testes, the anterior mediastinum, the retroperitoneal space, and the presacral and coccygeal areas, pineal and other intracranial sites. However, teratomas of the lesser omentum are extremely rare and the pathogenesis of the occurrence of this tumor in the omentum is still unclear. CT examination is highly specific and sensitive for the detection of fat and calcification. Identification for both components within the lesion can help narrow the diagnosis to liposarcoma, malignant mesenchymoma or teratomas [2].

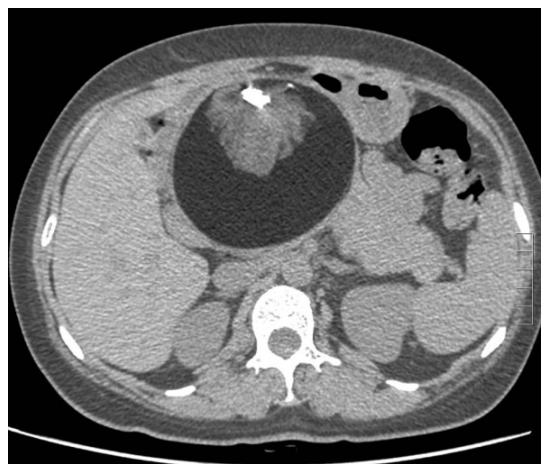


Figure 1: Vertical abdominal CT scan.

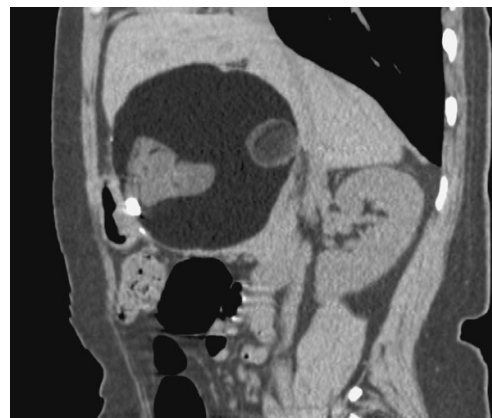

Figure 2: Horizontal abdominal CT scan showed a cystic-solid mass in the lesser omentum.

Principal findings of mature teratomas on CT images are a well-defined mass with separate cystic and solid components of varying proportions, discrete areas with densities similar to that of fat, or coarse, globular calcifications within the solid component. Recognition of these findings may allow the radiologist to make a correct preoperative diagnosis, but often there are diagnostic uncertainties about tracking the organ origin of teratomas due to huge mass. In fact, there are some debates regarding the origin of teratomas in our patient,

but operative findings and pathological examination of resected specimen confirm its origin to be from the lesser omentum instead of the pancreas. The origin and characteristic imaging features are critical for differentiating between lesions that need surgical resection and those that require medical treatment or no treatment at all. Symptomatic mature teratomas in the lesser omentum are easily managed and treatment through surgical intervention is usually sufficient.

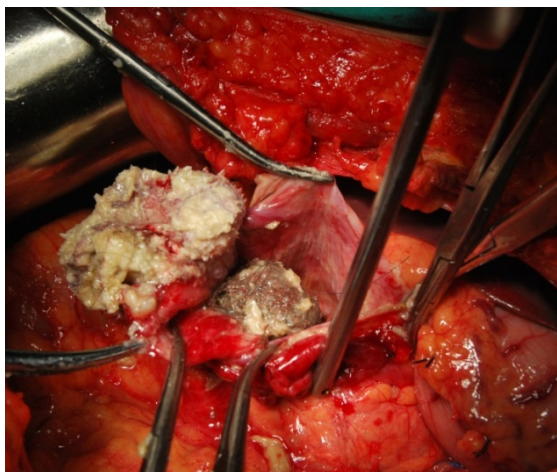

Figure 3: Intraoperative picture.

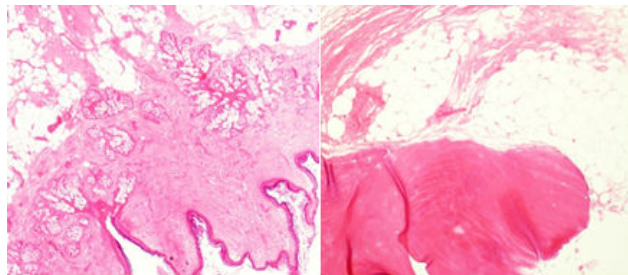


Figure 4: Histopathological examination of the excised tumor was consistent with typical pattern of benign mature teratomas.

References

1. McKenney JK, Heerema-McKenney A, Rouse RV (2007) Extragonadal germ cell tumors: a review with emphasis on pathologic features, clinical prognostic variables, and differential diagnostic considerations. *Adv Anat Pathol* 14: 69-92.
2. Cao D, Liu W, Guo L (2010) Malignant mesenchymoma surrounding the esophageal hiatus. *Ann Thorac Surg* 89: e1.