



Case Report

A SCITECHNOL JOURNAL

Osteomyelitis of the Middle Distal Phalanx Caused by *Arcanobacterium haemolyticum* in an Adolescent Nail Biter

Sarah Becker, Tornia Willie, Maria Novo, Tarik Zahouani*, Leo Sean, Evelyn Erickson and Yekaterina Sitnitskaya

Abstract

Human bites are the third leading cause of bite injuries leading to emergency room visits. Osteomyelitis is a dreaded complication of soft tissue infection contiguous to osseous structures and numerous cases of osteomyelitis due to human bites have been reported. *Arcanobacterium haemolyticum* is a known cause of pharyngitis in adolescents. We report a case of a 12 year old male with nail biting behavior who presented with cellulitis/abscess of the 3rd digit with MRI showing osteomyelitis and wound culture positive for *Arcanobacterium haemolyticum*. MRI should be considered in the evaluation of deep soft tissue infection of the finger.

Keywords

Osteomyelitis; *Arcanobacterium haemolyticum*; Autistic spectrum disorder

Introduction

Human bites are the third leading cause of bite injuries leading to Emergency Room (ER) visits. While these lesions are less often penetrating, as compared to dog or cat bites, they have been associated with greater morbidity and more frequent complications [1]. Contiguous osteomyelitis secondary to soft tissue infection after human bites have been reported [2-4]. One multicenter prospective study showed that *Streptococcus* and *Staphylococcus* species, followed by *Prevotella*, *Fusobacterium* and *Eikenella corrodens*, were the predominant species isolated from wound cultures from infected human bites [5].

Arcanobacterium haemolyticum (*A. haemolyticum*) is an unusual cause of non-streptococcal bacterial pharyngitis in adolescents [6]. It has rarely been isolated from soft tissue and other sterile sites. However, it has not been previously isolated from infected human bite. Here we report the case of a 12 year old autistic boy with a habit of compulsive nail biting behavior, who developed cellulitis/abscess of the 3rd digit with associated underlying osteomyelitis of the adjacent bone caused by *A. haemolyticum*.

Case Presentation

A 12 year old male with Autistic Spectrum Disorder (ASD) and habitual onychophagia presented with erythema, edema and pain in

the left middle finger of 4 days duration. He had no fever, and was noted to have redness, swelling and abundant purulent discharge from the lateral aspect of the distal phalanx of the left middle finger. There was a decreased range of motion in the distal interphalangeal joint of the same finger. The WBC count was $15.5 \times 10^9/\text{mL}$ and Procalcitonin was $<0.05 \text{ ng/mL}$. Because of close proximity of the underlying bone, MRI was performed to rule out osteomyelitis by continuation. The imaging showed soft tissue edema and swelling with associated cortical irregularities in the distal phalanx (Figures 1 and 2). The wound culture grew *A. haemolyticum*. The wound was debrided. The patient was treated with IV ampicillin-sulbactam and clindamycin for 5 days. Three weeks of treatment were completed with oral clindamycin, in accordance with reported sensitivity of the causative organism. At the follow up examination one month later, there was full resolution of symptoms and signs.

Discussion

We report a case of osteomyelitis caused by *A. haemolyticum*, which had its probable origin in the oropharynx of a patient with no manifestations of pharyngitis. Infection inoculated through onychophagia is expected to have the same etiology as infection due to human bite, and to be caused by oral commensals [5]. *A. haemolyticum* is a rare cause of pharyngitis with extremely rarely reported systemic complications from sepsis to focal infection including osteomyelitis [6-11]. However, we found only one previous report of *A. haemolyticum* causing infection due to a bite (inflicted by a dog) [12]. Nevertheless, it makes sense that oropharyngeal bacteria may be inoculated into human bite wound. *A. haemolyticum* isolates are susceptible to penicillins, macrolides and Clindamycin [13,14]. Our initial choice of treatment included Ampicillin-Sulbactam and Clindamycin (for staphylococcal coverage) which resulted in prompt improvement.

A. haemolyticum rarely causes soft tissue infections, usually in old and/or immunocompromised individuals [8,11]. We believe that this is the first report of soft tissue infection in an immune competent pediatric patient. Furthermore, this case is unique because there was a complication of involvement of the underlying bone.

Osteomyelitis by continuation is a rare complication of human bite. On physical exam, it is not possible to determine whether cellulitis or abscess in the digit has extension to the bone, which is also extremely rare [9,10]. In contiguous osteomyelitis, fever usually is absent, and WBC count and inflammatory markers like CRP and Procalcitonin are more often normal rather than elevated. Our patient had no fever, his WBC count was only mildly elevated and procalcitonin was normal. All these findings do not exclude a diagnosis of underlying osteomyelitis. If MRI was not performed in this case, there would have been no recognition for the necessity of long antibiotic treatment because of the presence of osteomyelitis.

Conclusion

We have demonstrated that infection of distal finger secondary to onychophagia might be associated with extension to the underlying bone, and be caused by *A. haemolyticum*. MRI should be considered

*Corresponding author: Zahouani T, MD. Department of Pediatrics, Lincoln Medical and Mental Health Center, 234E, 149 St. Bronx, NY 10451, USA, Tel: 718-579-5030; E-mail: tarikzahouani@gmail.com

Received: May 15, 2017 Accepted: June 15, 2017 Published: June 20, 2017

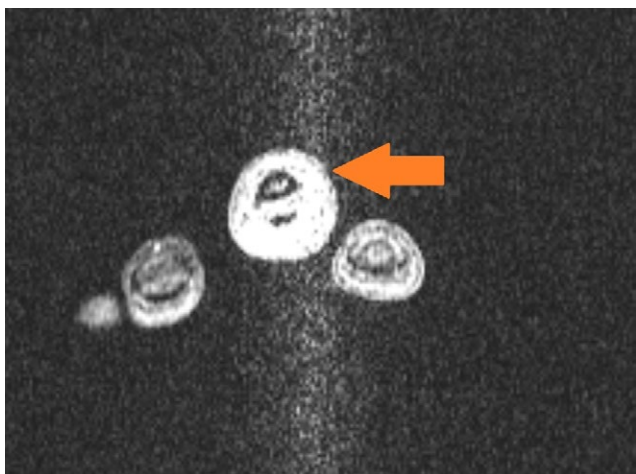


Figure 1: Axial T1 weighted MRI scan showing extensive soft tissue edema and swelling with associated cortical irregularities.

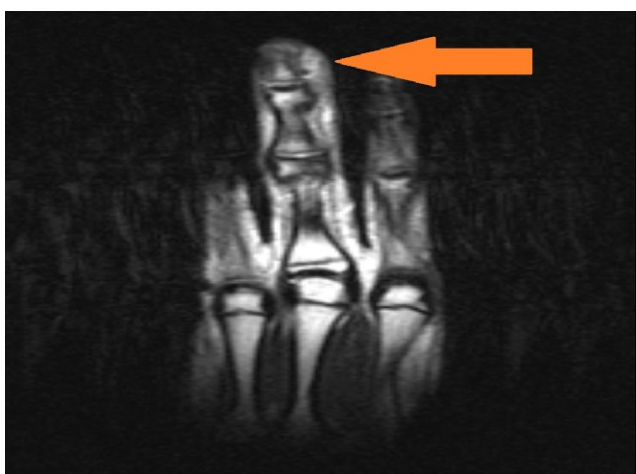

Figure 2: Lateral MRI scan showing extensive soft tissue edema and swelling and osteomyelitis of the distal phalanx.

in the evaluation of deep soft tissue infection of the finger. In our case, empiric treatment with Ampicillin-Sulbactam and Clindamycin achieved prompt clinical resolution of the infection.

References

- Griego RD, Rosen T, Orengo IF, Wolf JE (1995) Dog, cat, and human bites: A review. *J Am Acad Dermatol* 33: 1019-1029.
- Gonzalez MH, P Papierski, RF Hall (1993) Osteomyelitis of the hand after a human bite. *J Hand Surg Am* 18: 520-522.
- Zahouani T, Lopez C, Burdea L, LaCruz AD, Polonio P, et al. (2016) Osteomyelitis of the fifth toe after human bite. *Am J Med Case Rep* 4: 346-348.
- Resnick D, Pineda CJ, Weisman MH, Kerr R (1985) Osteomyelitis and septic arthritis of the hand following human bites. *Skeletal Radiol* 14: 263-266.
- Talan DA, Abrahamian FM, Moran GJ, Citron DM, Tan JO, et al. (2003) Clinical presentation and bacteriologic analysis of infected human bites in patients presenting to emergency departments. *Clin Infect Dis* 37: 1481-1489.
- Mackenzie A, Fuite L A, Chan F T, King J, Allen U, et al. (1995) Incidence and pathogenicity of *Arcanobacterium haemolyticum* during a 2-year study in Ottawa. *Clin Infect Dis* 21: 177-181.

- Gaston DA, Zurowski SM (1996) *Arcanobacterium haemolyticum* Pharyngitis and Exanthem. Three Case Reports and Literature Review. *Arch Dermatol* 132: 61-64.
- Kavitha K, Latha R, Udayashankar C, Jayanthi K, Oudeacoumar P, et al. (2010) Three cases of *Arcanobacterium pyogenes*-associated soft tissue infection. *J Med Microbiol* 59: 736-739.
- Thean YT, Siew YN, Thomas H, Chan BK (2006) *Arcanobacterium haemolyticum* bacteremia and soft tissue infections: Case report and review of literature. *J Infect* 53: 69-74.
- Therriault BL, Daniels LM, Carter YL, Raasch RH (2008) Severe sepsis caused by *Arcanobacterium haemolyticum*: a case report and review of the literature. *Ann Pharmacother* 42: 1697-702.
- Dobinsky S, Noesselt T, Rucker A, Maerker J, Mack D (1999) Three cases of *Arcanobacterium haemolyticum* associated with abscess formation and cellulitis. *Eur J Clin Microbiol Infect Dis* 18: 804-806.
- Lee S, Roh KH, Kim CK, Chong Y et al. (2008) A Case of Necrotizing Fasciitis Due to *Streptococcus agalactiae*, *Arcanobacterium haemolyticum*, and *Finnegoldia magna* in a Dog-bitten Patient with Diabetes. *Korean J Lab Med* 28: 191-195.
- Skov RL, Sanden AK, Danchell VH, Robertsen K, Ejlersen T (1998) Systemic and deep-seated infections caused by *Arcanobacterium haemolyticum*. *Eur J Clin Microbiol Infect Dis* 17: 578-582.
- Linder R (1997) *Rhodococcus equi* and *Arcanobacterium haemolyticum*: two "coryneform" bacteria increasingly recognized as agents of human infection. *Emerg Infect Dis* 3: 145-153.

Author Affiliations

Top

Department of Pathology, Mount Sinai Medical Center, Miami Beach, Florida, USA

Submit your next manuscript and get advantages of SciTechnol submissions

- ❖ 80 Journals
- ❖ 21 Day rapid review process
- ❖ 3000 Editorial team
- ❖ 5 Million readers
- ❖ More than 5000 
- ❖ Quality and quick review processing through Editorial Manager System

Submit your next manuscript at • www.scitechnol.com/submission