



## The Application of Carotid Cistern Drainage in Neurosurgery

Bobur Khasanov<sup>1\*</sup> and Jin Guoliang<sup>2</sup>

<sup>1</sup>Department of Neurosurgery, Medical College of Shaoxing University of Arts and Sciences, Zhejiang Province, Shaoxing City, China

<sup>2</sup>Department of Neurosurgery, Shaoxing people's Hospital, Zhejiang, China

\*Corresponding author: Jin Guoliang, Department of Neurosurgery, Shaoxing people's Hospital, Zhejiang Province, Shaoxing City Zhongxing, China, Tel: +(86)13905751168; E-mail: [jingl168@163.com](mailto:jingl168@163.com)

Received date: February 20, 2021; Accepted date: March 10, 2021; Published date: March 20, 2021

### Abstract

**Purpose:** This paper introduces a safe, effective and convenient method of Cerebrospinal Fluid (CSF) drainage. A very soft, elastic, small lumbar cisterna drainage tube is used, which is conveniently placed into the basilar cisterna (carotid cisterna, etc.) during craniotomy. Drainage of CSF from the basal cistern is of great significance in craniotomy, it plays a positive role in controlling intracranial pressure, excluding bloody cerebrospinal fluid, reducing the incidence of cerebrospinal fluid leakage, and alleviating headache and other symptoms of patients. Because the tip of the drainage tube is round and blunt, the diameter will not exceed 1.5 mm and the surface is smooth, it will not damage the peripheral blood vessels and nerves when placed into the basal cistern of the brain, so it is very safe.

**Methods:** After intracranial surgery, such as aneurysm clipping, traumatic or spontaneous hematoma removal and intracranial tumor resection, the basal cistern (carotid cistern, suprasellar cistern, endplate cistern, cerebellopontine angle cistern, etc.) was opened near the operation area after intracranial surgery, and a drainage tube was placed to continuously drain cerebrospinal fluid through skin tunnel for 2-5 days to control postoperative intracranial hypertension and reduce postoperative complications.

**Results:** 36 cases of intracranial surgery were treated with basal cistern cerebrospinal fluid drainage, including 12 cases of intracranial aneurysm clipping, 14 cases of intracranial hematoma clearance, and 10 cases of intracranial tumor resection. During the operation, the basilar cistern was exposed under the microscope, the arachnoid membrane was opened and the drainage tube was placed smoothly. The postoperative drainage of CSF was smooth, and the intracranial pressure control effect was satisfactory. The headache symptoms of the patients were mild and the recovery was fast.

**Conclusion:** This paper introduced 36 clinical cases, including clipping of intracranial aneurysm, resection of skull base tumor, and removal of traumatic or spontaneous intracranial hemorrhage, this method has achieved satisfactory results. Continuous drainage of cerebrospinal fluid from carotid cistern plays a positive role in controlling intracranial hypertension, improving symptoms and prognosis after cranio cerebral surgery. Through four typical cases, described in detail the way

of drainage tube placement and matters needing attention, and discussed with reference to the literature.

**Keywords:** Basal cistern; Craniotomy; Cerebrospinal fluid drainage; Cerebello pontine angle; Aneurysm; Traumatic brain injury; Sellar meningioma

### Case Report

Controlling intracranial hypertension and reducing the stimulation of bloody cerebrospinal fluid to the brain tissue have attracted much attention in the field of neurosurgery. Whether it is brain injury, spontaneous cerebral hemorrhage, intracranial aneurysm clipping operation or intracranial tumor resection, effective drainage of cerebrospinal fluid during and after operation has positive clinical significance in reducing intracranial pressure, relieving symptoms such as headache and fever, reducing cerebrospinal fluid leakage after operation, and improving prognosis [1-4]. This paper introduces the method of opening the basal cistern (carotid cistern, suprasellar cistern, end-plate cistern, Cerebello Pontine Angle (CPA) cistern, etc.) during the operation, and the drainage tube was placed into the basal cistern. After the operation, the cerebrospinal fluid was continuously drained and satisfactory results were obtained.

### Clinical data and methods

**Clinical data:** From July 2018 to June 2020, 36 patients (16 male, 20 female, aged 42-79 years, with an average of 54.5 years) were used for cerebrospinal fluid drainage from the basal cistern in different neurosurgical operations. The intracranial aneurysm was clipped in 12 cases, the intracranial hematoma was removed in 14 cases (including TBI patients), and the intracranial tumor was removed in 10 cases.

**Operation method:** After clipping of intracranial aneurysms or removal of hematoma or tumor resection, the basal cistern of the brain was exposed under microscope near the operation area, such as carotid cistern, suprasellar cistern, end-plate cistern, and cerebellopontine angle cistern. After the arachnoid membrane was opened, a drainage tube (lumbar cistern drainage tube, model: 27302, Medtronic company) was placed into it. After cerebrospinal fluid outflow the drainage height was controlled at the range of 80-180 mm to maintain normal intracranial pressure. According to the postoperative clinical manifestations and head CT Reexamination, cerebrospinal fluid was continuously drained for 2-5 days.

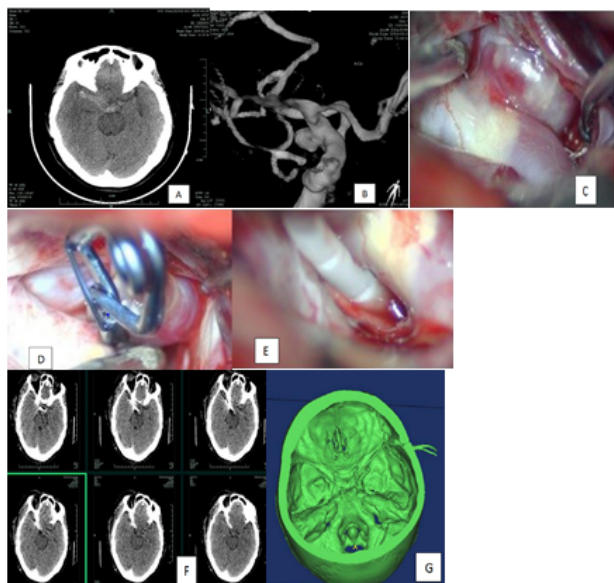
**Observation index:** The patients' consciousness, Intracranial Pressure (ICP), Numerical Rating Scale(NRS), volume of the drained cerebrospinal fluid and color, head CT Reexamination were observed after the operation.

### Results

36 cases of surgical patients, drainage was unobstructed, daily drainage of cerebrospinal fluid 75-320 ml, no cerebrospinal fluid incision leakage, no intracranial infection occurred, the median intracranial pressure during drainage was 6-12 mmhg, the headache NRS score of conscious patients was 1-6. The patients were followed up for 3-6 months. The Glasgow Outcome Scale (GOS) scale was 5 in 33 cases and 4 in 3 cases.

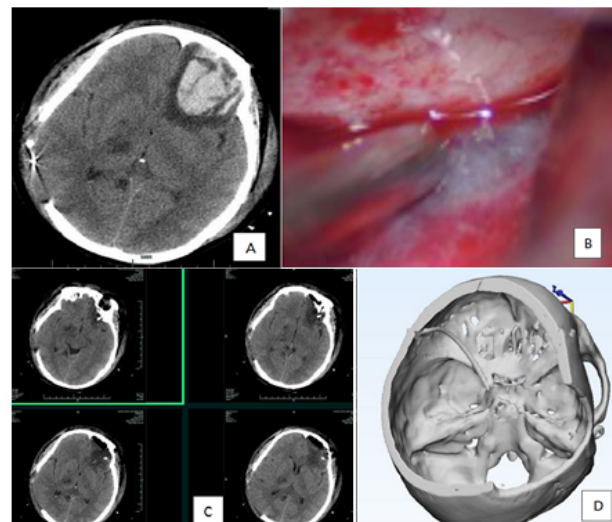
## Case Introduction

- A 58-year-old female presented with sudden onset of headache, in head CT scan revealed subarachnoid hemorrhage; DSA showed the right Internal Carotid Artery (ICA) posterior communicating artery aneurysm. Diagnosis: Right ICA PCoA Aneurysm. The patient underwent (right ICA, PCoA) an aneurysm clipping surgery. After the aneurysm was clipped, a drainage tube was inserted into the carotid cistern through the conventional right pterional approach. The patient recovered well and was followed up for 6 months with GOS grade 5 (Figure 1).



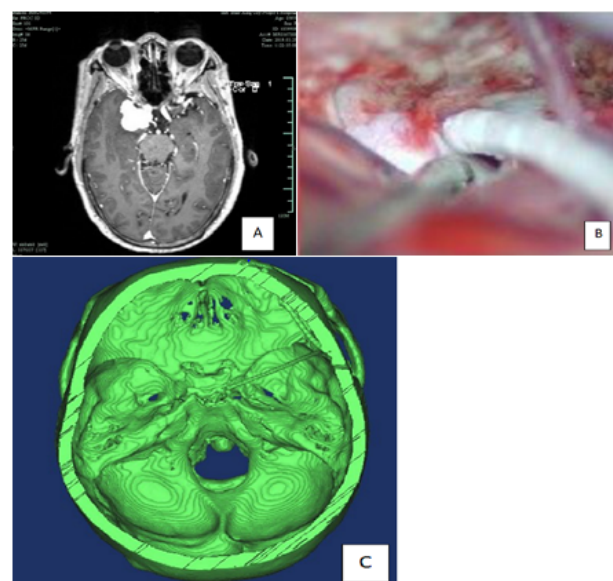
**Figure 1:** A-CT scan showed a subarachnoid hemorrhage, B-DNA showed the right Internal Carotid Artery (ICA) posterior communicating artery aneurysm, C-PCoA aneurysm under the microscope, D-PCoA aneurysm clipped from the neck of the aneurysm, E-putting the drainage tube in the suprasellar cistern under the microscope, F-the next day CT scan shows reduced bloody CSF and metal artifact (the clip), G-3D module of the patient's head (can see drainage tube is on the suprasellar area).

- A 59-year-old female presented with the head injury, caused by a traffic accident, in head CT scan revealed; epidural hematoma in the right occipital lobe and intracerebral hematoma in the left frontal lobe. Diagnosis: Left frontal lobe intracerebral hematoma, right occipital lobe epidural hematoma. The patient underwent intracerebral hematoma removal operation. After the removal of the intracerebral hematoma in the frontal lobe, the carotid cistern was separated and the drainage tube was placed. In postoperative period, the cerebrospinal fluid was continuously drained. The CT scan of the next day showed the drainage tube in the carotid cistern. Patient were followed up for 6 months, no complaints, recovery period went very well and achieved complete recovery (Figure 2).



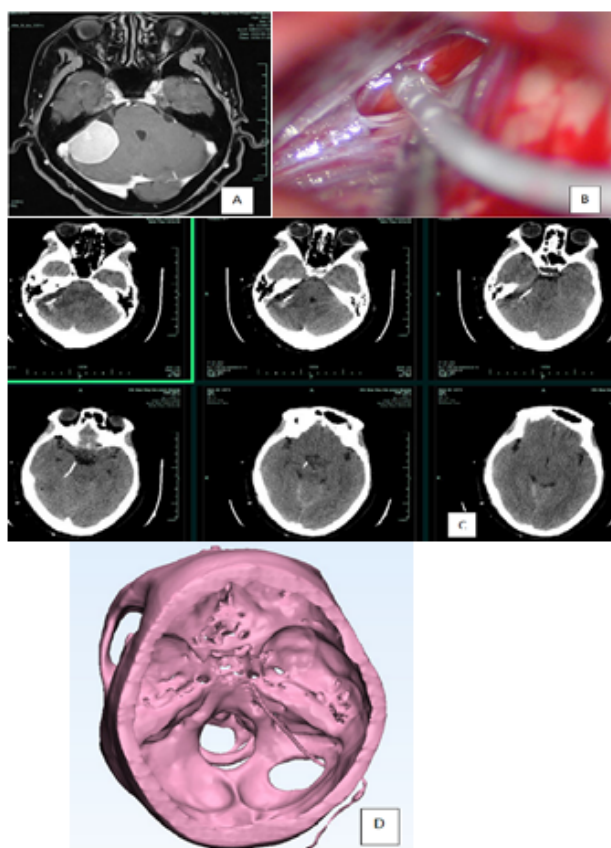
**Figure 2:** A-CT scan; epidural hematoma in the right occipital lobe (after the decompression operation) and intracerebral hematoma in the left frontal lobe, B-putting the drainage tube in the suprasellar cistern under the microscope, C-the next day CT scan showed total removed hematoma and drainage tube in the suprasellar cistern, D-3D module of the patient's head (can see drainage tube is on the suprasellar area).

- 3. A 59-year-old female presented with the headache for a month. In head CT scan revealed right sellar meningioma. Diagnosis: Right parasellar and sellar meningioma. The patient underwent tumor resection (in the right sellar area) operation. After tumor resection, the drainage tube was placed in the right carotid cistern and the Cerebrospinal Fluid (CSF) was continuously drained after the operation. The head CT scan was reexamined the next day, the drainage tube was in the place (carotid cistern). Recovery period went good without any complications (Figure 3).



**Figure 3:** A-CT scan showed right sellar meningioma; B-putting the drainage tube in the suprasellar cistern under the microscope, C-3D module of the patient's head (can see drainage tube is on the suprasellar area).

- A 60-year-old female presented with headache. In head CT scan revealed right Cerebello Pontine Angle (CPA) meningioma. Diagnosis: Right CPA Meningioma. The patient underwent CPA meningioma removal operation. After tumor resection, the drainage tube was placed into a suprasellar cistern through the infratentorial cerebellum and CPA cistern. Cerebrospinal fluid was continuously drained after the operation, and the patient recovered smoothly, no any complications (Figure 4).



**Figure 4:** A-CT scan showed right Cerebello Pontine Angle(CPA) meningioma, B-putting the drainage tube under the microscope into the carotid cistern through the subarachnoid space C-CT scan after the operation showed tube in the place (carotid cistern) and subarachnoid hemorrhage, D-3D module of the patient's head (can see drainage tube is on the suprasellar ar).

## Discussion

In neurosurgery, the effectiveness of patient treatment depends on the disease itself and other factors besides the disease itself, such as age, lesion location, intracranial pressure, cerebrospinal fluid circulation, infection, coma, etc. In severe Traumatic Brain Injury (TBI) patients, External Ventricular Drainage (EVD) drain CSF and may decrease ICP; however, presently the evidence that EVD uses either improves or lowers morbidity in adults with severe TBI is not established. Continuous CSF drainage may be superior to lower ICP compared with intermittent drainage, but this would be verified by a multi-institutional study and complications would need to be assessed [1]. In severe TBI patients, GCS is the most important in the preoperative period, is this equal or less than 6, or more than 6 will play a crucial role in the outcome. It is undeniable that the surgical

method is very important also. Intracranial pressure is closely related to the prognosis of patients. Fever is very common during the intermediate period, occurring in up to 75% of all patients and correlating with greater subarachnoid and intraventricular blood volume [2], so it's important in timely to drain bloody CSF continuously to reduce the symptoms. Timely removal of cerebrospinal fluid circulation disorder and clearance of subarachnoid hemorrhage is one of the key factors of treatment. After completing intracranial operations, such as aneurysm clipping, hematoma removal, and tumor resection, we use the method of cerebrospinal fluid drainage from the basal cistern, which can not only control intracranial pressure, but also avoid serious consequences caused by cerebrospinal fluid circulation disorder, reduce the meningeal stimulation reaction produced by blood to the subarachnoid space, reduce the occurrence of hydrocephalus and cerebrospinal fluid leakage, effectively reduce the incidence of postoperative complications and symptoms, it plays a positive role in improving prognosis. In late period (more than 14 days) of aneurysmal SAH hydrocephalus persists into this period in 18%-26% of patients, with older patients and those with large amount of intraventricular blood at the highest risk for hydrocephalus [3], it's important to drain the bloody CSF in the early stages like at the first attempt and put the drainage tube in the carotid cistern. In all cases we putted the drainage tube after surgery immediately. Transient left ventricular dysfunction in SAH occurs in 11% of patients [4]. Vasospasm one of the biggest problems in large SAH patients can lead to cerebral infarction, by draining bloody CSF early and effectively, we can achieve a good result, in the usual time with the treatment (diuretics and utilizing inotropic agents) most patients begin to improve in 48 hours. In these groups of cases, after intracranial operations, such as aneurysm clipping, hematoma removal, and tumor resection, the brain tissue collapse or swelling during the operation is temporarily relieved. The brain pool near the lesion is not difficult to expose under the microscope. The brain tissue can be separated from the internal carotid artery and the optic nerve under the microscope, the arachnoid membranes were cut and the drainage tube was placed into the carotid cistern. According to the depth of the drainage tube, it can be placed in the carotid cistern, the suprasellar cistern, and the anterior pontine cistern. When the anterior communicating aneurysm is clipped, the endplate cistern can be opened and the drainage tube can be placed into the third ventricle. During the operation of posterior fossa lesions, a drainage tube was placed through the cerebellopontine angle cistern, above the trigeminal nerve and lateral pontine to reach the suprasellar cistern. We suggest using the soft lumbar cistern drainage tube. Because the structure around the basal cistern is important and adjacent to the brain stem, the drainage tube must be thin and soft to avoid damaging the optic nerve, oculomotor nerve, and brain stem penetrating blood vessels. The duration of drainage tube placement was determined by patient headache score (NRS), intracranial pressure monitoring, head CT reexamination, and cerebrospinal fluid drainage volume. In our data, the drainage tube was removed after 2-5 days of continuous drainage. We believe that the drainage time can be extended to 7-10 days or longer depending on the situation and the condition of the patient. Of course, the longer the drainage time, the higher the risk of infection.

According to Schmidek [5] in neurosurgery, 4-7 days of external ventricular drainage is more appropriate. Consistent with our point of view, there are indications and applicable situations basal cistern drainage can be used. We believe that this method is suitable for the operation of skull base lesions or the operation where the bone



window is located or close to the skull base. When decompressive craniectomy for Traumatic Brain Injury (TBI), the bone flap should be as close as possible to the skull base, and the drainage of carotid cistern can also be used. This method is not suitable for patients with non-skull base diseases and the bone flap is not close to the skull base because of the difficulty in exposing the basal or carotid cistern.

Robert F, et al. [6] introduced in cerebrovascular surgery 2015 that Extra Ventricular Drainage (EVD) should be applied when intracranial artery clipping surgery, including Middle Cerebral Artery (MCA) aneurysm, Anterior Communicating Artery (ACoA) aneurysm and Internal Carotid Artery (ICA) aneurysm. In patients with anterior cerebral artery aneurysms putting the EVD before the operation is additional trauma to the brain and put it in the place after the operation to maintain the ICP, also open the carotid cistern to expose the aneurysm "lateral supraorbital approach followed by frontal ventricular drainage was applied to reduce intracranial pressure before dura opening. Intradurally, the carotid cistern was opened to release some extra Cerebrospinal Fluid (CSF) and to expose the internal carotid artery bifurcation and the A1 segment" will provide open access to the carotid cistern, and with it can ease putting drainage tube into the cistern. We believe that carotid cistern drainage has its advantages in the case where exposure of aneurysms is not difficult. If it is accompanied by acute hydrocephalus and the need for aneurysm clipping, because of the high intracranial pressure, it is difficult to separate the fissure cerebri lateralis. Compared with lumbar cistern drainage, we believe that each has its advantages and disadvantages. For patients with increased intracranial pressure, preoperative and postoperative lumbar cistern drainage may induce occipital foramen hernia. Moreover, lumbar cistern drainage is not very convenient. Patients need to lie on their side and flex their bodies. For patients with intracranial hypertension, especially patients with subarachnoid hemorrhage, neck resistance exists, lumbar cistern puncture is not very easy to perform. Sometimes, for patients with disturbance of consciousness or irritability, lumbar cistern drainage is not easy that's why sedation, analgesia and anesthesia are needed. It is also time-consuming and laborious to move patients in the operating room because of limited aseptic conditions. The cistern drainage is convenient, practical and safe because of its operation in the operation area and already aseptic, it'll be performing right after finishing the main surgery just before the closure of the operated area. Of course, carotid cistern drainage is a supplementary method used in neurosurgery. For some patients with subarachnoid hemorrhage or surgical wound bleeding that may enter the subarachnoid space, or

predict that the intracranial pressure is still high and the brain edema is serious, this drainage method can be used for these patients, but it is not required in every operation. Due to the lack of clinical data sample size, it is difficult to set up a control group.

## Conclusion

Based on our Neurosurgery department's experiences we briefly concluded that this method can be used (when the lesion near to skull base operations or related to this area surgeries) in many operations and cannot be used (when it's difficult to exposure or the surgery zone is far away from the skull base operations) or not recommended. But we believe that this method has a lot advantages like; timely effective CSF (or bloody CSF) drainage, reducing ICP, reducing irritability to the brain, easy access, less or not complications, mild or total reducing symptoms (fever, headache etc.), accessibility for many kind of surgeries (aneurysm clipping, brain tumors, traumatic brain injuries, intracranial hematomas etc.). Continuous drainage of cerebrospinal fluid from carotid cistern plays a positive role in controlling intracranial hypertension, improving symptoms and prognosis after cranio cerebral surgery. Further clinical researches are needed to improve this method!

## References

1. Nancy C, Annette MT, Cindy O'Reilly, et al. (2016) Guidelines for the management of severe traumatic brain injury 4th edition (Reviewed for evidence-based integrity and endorsed by the American Association of Neurological Surgeons and Congress of Neurological Surgeons). Cerebrospinal fluid drainage pp 62-67.
2. Fernandez A, Schmidt JM, Claasen J, et al. (2007) Fever after subarachnoid hemorrhage: risk factors and impact on outcome. *Neurology* 68:1013-1019.
3. Doria Z, Hynan LS, Kopitnik TA, Samson D (2003) Factors related to hydrocephalus after aneurysmal subarachnoid hemorrhage. *Neurosurgery* 52:763-769.
4. Temes RE, Tessitore E, Schmidt JM, et al. (2010) Left ventricular dysfunction and cerebral infarction from vasospasm after SAH. *Neurocrit Care* 13:359-365.
5. Henry H (2002) Schemidek "Operative neurosurgical techniques. Section xiv posterior fossa tumors pp 975-1006.
6. Robert F, Spetzler M, Yashar S, Kalani Peter N (2015) Neurovascular surgery 2015.III-subarachnoid hemorrhage.