



Utility of Laminar Fiducials for Registration to Maximize Safety of C2 Pedicle Screw Placement for Atlantoaxial Instability due to Os Odontoideum in Down Syndrome: A Technical Note

Nathan Oh^{1*}, Alice Wang¹, Khodayar Goshtasbi², George Hanna¹ and Gilbert Cadena¹

Abstract

Atlantoaxial instability secondary to os odontoideum is a possible complication in Down syndrome. Common surgical treatment strategies include C1-2 fusion or occipitocervical fusion. The primary advantage of C1-2 fusion is motion preservation at the C0-C1 joint, however, various anatomic abnormalities can preclude safe pedicle screw placement at C2. 5 mm and smaller C2 pedicles create a challenge in one-third of os odontoideum cases, thus appropriate utilities or alternative surgical strategies must be considered. Here we detail the utility of a real-time intraoperative navigation setup that allows for multiple *in situ* re-registrations for precise localization. We present a patient with Down syndrome with progressive myelopathy secondary to atlantoaxial instability from os odontoideum where *in situ* C2 and C3 laminar bone fiducials allowed for precise intraoperative navigation and successful cannulation of sub-5 mm C2 pedicles. Real-time feedback for operative navigation can provide immense value in similar high-risk cases.

Keywords

Atlantoaxial instability; C1-2 fusion; C2 pedicle screws; Spinal navigation; Down syndrome; Os odontoideum

Introduction

Atlantoaxial instability has been reported to occur in 14%-24% of patients with Down syndrome, though symptomatic instability is seen in only 1%-2% of cases [1,2]. Os odontoideum represents one possible etiology for symptomatic neurologic dysfunction due to atlantoaxial instability. Occipital cervical (OC) fusion and C1-2 fusion have been advocated and validated as successful treatment strategies in these cases after considering various nuances of the C0-C1 joint, degree of subluxation and rotation, and need for distraction [1]. Various fixation methods at C2 have been used to achieve solid arthrodesis, including pedicle screws, laminar screws, and transarticular screws [3,4]. Anatomical studies in patients with os odontoideum suggest that up to 34.5% have pedicle diameters that are insufficient for safe pedicle screw placement [2]. Some have suggested that C2 pedicles smaller than 4.5-5.5 mm are not suitable for screw placement [2,4].

*Corresponding author: Nathan Oh, Department of Neurological Surgery, University of California, Irvine, USA, Tel: 714-456-6966; E-mail: noh@uci.edu

Received: June 24, 2019 Accepted: July 26, 2019 Published: August 05, 2019

Experienced surgeons have shown that axis pedicle diameters of less than 6 mm have a two-fold higher incidence of the cortical breach with potentially significant neurologic consequences. Other series have confirmed a significant increase in C2 pedicle screw malposition in pedicles less than 5 mm, supporting the use of navigation-based screw placement [5]. As a result, supplemental techniques that offer potential intraoperative assistance should be considered. A variety of commonly used navigation systems exist to aid in hardware placement in complex cases, but most are fraught with the inability to provide practical re-registration and accurate localization without the need for an additional intraoperative scan. Here we show the utility of a navigation system setup that allows for re-registration and improved accuracy *in situ* without the need for additional intraoperative scans, thereby reducing operative time, cost, radiation exposure and time under anesthesia.

Case Report

HMH history and presentation

A 21-year old woman with Down syndrome initially presented with progressive myelopathy secondary to atlantoaxial instability related to os odontoideum. Preoperative MRI imaging revealed severe spinal cord compression from C1 anterior subluxation (Figure 1) with respect to C2. Maximal C2 pedicle width was measured to be 3.8 mm on the left (Figure 2) and 4.3mm on the right (Figure 3) on axial CT slices. C2 laminae were similarly small and measured (R) 3.6 mm and (L) 3.9 mm on axial CT sections (figures not shown). Flexion extension X-rays confirmed gross atlantoaxial instability with ADI increasing to 9.9 mm in flexion from 2.8 mm in neutral position (Figure 4). After a thorough discussion of the surgical options and risks, the patient and her family elected to undergo surgical decompression and fusion.

Operative procedure

The patient was fiber optically intubated by the anesthesia team. Total IV anesthesia was provided with remifentanyl and Propofol

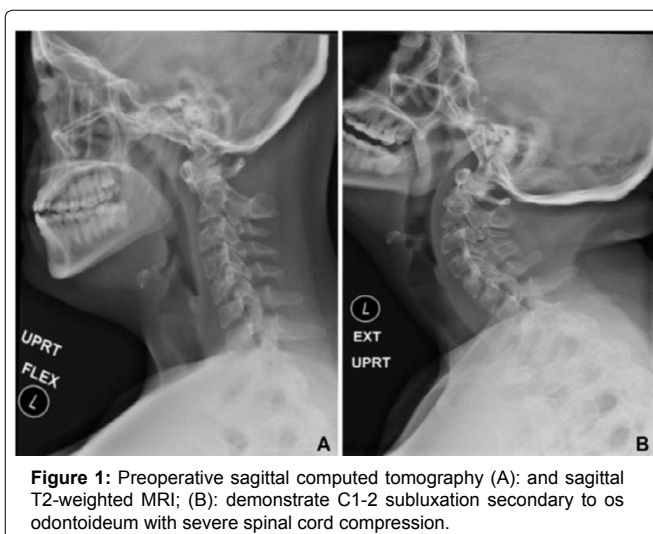


Figure 1: Preoperative sagittal computed tomography (A); and sagittal T2-weighted MRI; (B); demonstrate C1-2 subluxation secondary to os odontoideum with severe spinal cord compression.

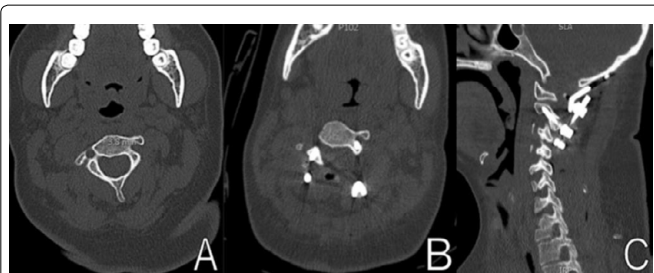


Figure 2: (A): Preoperative axial CT showing maximum left C2 pedicle diameter of 3.8 mm; (B): Postoperative axial CT window shows left C2 pedicle screw with Type I breach; (C): Postoperative sagittal CT scan shows left C2 pedicle screw trajectory and fusion construct.

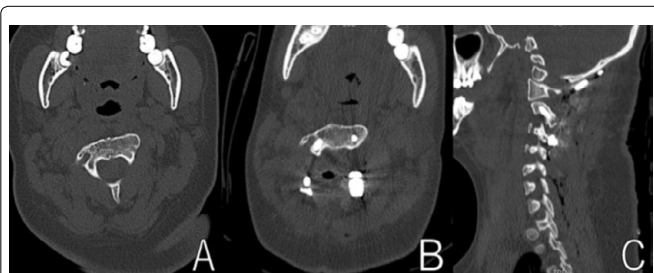

Figure 3: (A): Preoperative axial CT showing maximum right C2 pedicle diameter of 4.3 mm; (B): Postoperative axial CT window shows right C2 pedicle screw trajectory; (C): Postoperative sagittal CT scan shows right C2 pedicle screw trajectory.

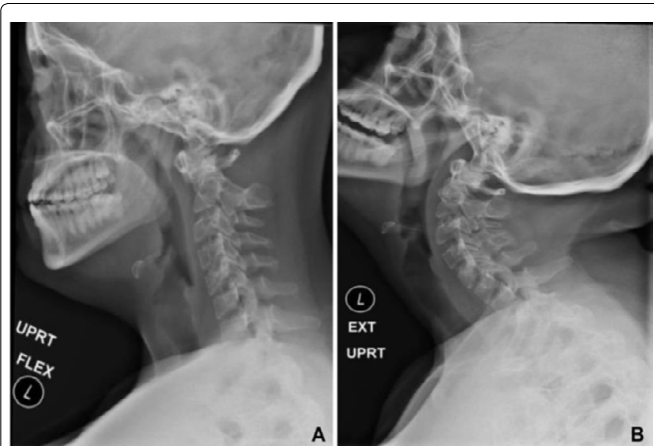


Figure 4: Flexion-extension X-rays of the cervical spine demonstrate dynamic instability of atlantoaxial complex. (A): ADI is 9.9 mm in flexion; (B): Resolves in extension.

to allow for intraoperative neuromonitoring. Neuromonitoring electrodes were placed and baseline Somatosensory Evoked Potentials (SSEP) and transcranial Motor-Evoked Potentials (MEP) were obtained prior to initiating our flip. The patient's head was pinned using a Mayfield three-pin head holder (Integra Life sciences Corporation, Plainsboro, NJ). While positioning the patient prone MEPs and SSEPs dropped significantly. The head was gently repositioned with the return of signals to baseline. AP and lateral X-rays were obtained to ensure neutral alignment. The bed was subsequently turned 180 degrees in the room and lined up with the bore of our BodyTom intraoperative CT scanner (NeuroLogica Corporation, Danvers, MA). Exposure of the occiput down to C3 was performed in standard fashion. Four 3mm screws were placed as

bone fiducials on the bilateral C2 and C3 laminae. The C1 posterior arch was taken down to achieve early spinal cord decompression (Figures 2 and 3). An intraoperative CT scan of the cervical spine was performed with fiducials in place. Intraoperative registration was performed using the four bone fiducials and verification was performed using anatomical landmarks (Figures 5 and 6). We found that the patient's short neck and small anatomy required multiple adjustments to our self-retaining retractors. As we checked our registration after each adjustment we found that anatomy had shifted subtly such that or accuracy dropped by 1 mm or more. Given our limited margin for error, bone fiducials provided a means of easy re-registration multiple times throughout the case without requiring a separate CT scan or abandoning our initial plan for pedicle screw placement. C2 pedicles were successfully cannulated with (R) 4 mm and (L) 3.5 mm screws. There were no palpable breaches and no evidence of vascular or neurological compromise during the case. Neuromonitoring remained stable and at baseline for the remaining duration of the case.

Postoperative course

The patient was extubated post-operatively and had no identifiable postoperative weakness. She experienced new transient patchy numbness in the legs postoperatively. She was mobilized and discharged to acute rehab. Post-operative CT showed satisfactory hardware placement (Figures 5 and 6). The left C2 pedicle screw showed evidence of a Type I breach without clinical sequelae [6]. Her functional status at 1 month was significantly improved and continued to improve at 6 months follow up. At 1 year follow up, the patient's strength and gait had significantly improved to the point where she no longer experienced falls. Flexion/Extension X-rays demonstrated no evidence of subluxation with successful fusion (Figure 7).

Discussion

Posterior C1-2 instrumented fixation is challenging due to the complicated neurovascular anatomy in this region. Anatomical studies have shown a variable vertebral artery course in up to 23%

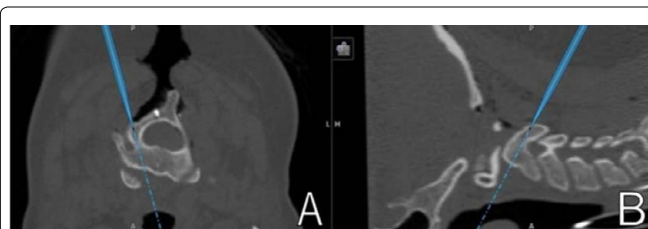


Figure 5: (A): Laminar bone fiducials served as the reference frame to guide intraoperative navigation for C2 pedicle screw instrumentation. Only one laminar bone fiducial is visible in this image. The blue line denotes the right C2 pedicle trajectory in (A): Axial view and (B): Sagittal view.

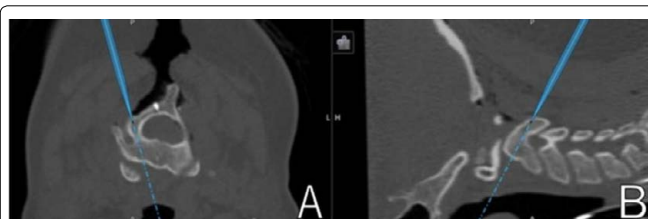

Figure 6: Laminar bone fiducials are seen in this on bilateral C2 laminae. (A): Left C2 pedicle screw trajectory is denoted by the blue line in (A): The axial view and; (B): Sagittal view.

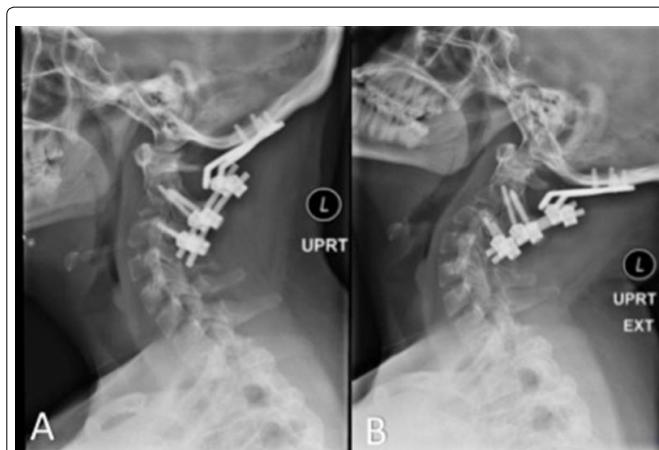


Figure 7: 1 year follow-up Flexion/Extension X-rays demonstrating stable construct without evidence of hardware failure or subluxation. (A): Flexion and; (B): Extension.

of specimens that preclude safe instrumentation with a transarticular screw technique [7]. C2 pedicle screws present different challenges and various studies have evaluated the utility of navigation-based systems or fluoroscopy compared with free-hand techniques in reducing malposition and improving safety [6,8,9]. Overall, the freehand technique was deemed to be safe with a 14%-23% risk of a cortical breach, most of these being Grade I or equivalent with up to 2% risk of vertebral artery injury and approximately 1% risk of perioperative stroke [6,8,9]. A recent large meta-analysis of clinical series' comparing VA injury in transarticular screw placement and C2 pedicle screw placement found a 1.84% and 0.34% rate of clinically significant misplacement, respectively [10]. Importantly, most of these studies are retrospective in nature and clear criteria for minimum pedicle screw diameter are not uniformly reported, therefore impacting the generalizability of these results. Interestingly, CT-based navigation systems alone do not seem to reduce the rate of cortical breach completely with some authors reporting rates of breach ranging from 8.6%-10% [8,11].

Many intraoperative navigation systems have been developed and improved over the years to help surgeons minimize complication rates due to screw breach and malpositioning. Current intraoperative navigation techniques include, but are not limited to, Airo Mobile Intraoperative Computer Tomography (CT)-based Spinal Navigation (Brainlab®, Feldkirchen, Germany), Stryker Spinal Navigation with SpineMask Tracker and SpineMap Software (Stryker®, Kalamazoo, Michigan), Stealth Station Spine Surgery Imaging and Surgical Navigation with O-arm (Medtronic®, Minneapolis, Minnesota), and Ziehm Vision FD Vario 3-D with NaviPort integration (Ziehm Imaging®, Orlando, Florida) [9]. These intraoperative navigation techniques are not without limitations. For example, most techniques utilize a clamp which is fixed to the spinous process of the adjacent level to act as a reference frame [5,9,12]. A frequently cited issue is that the frame is relatively mobile and displacement of a few millimeters can lead to inaccuracy. If unrealized, this can lead to serious complications including canal breach, cord injury and/or VA injury. If the accuracy becomes unreliable, the patient must be reimaged and re-registered in order to generate a new reference map, thereby subjecting the patient to more radiation, increased intraoperative time and expense [2,11,12]. Another concern is the spatial footprint of the reference frame which often occupies a significant amount of space within the surgical cavity thus causing physical interference for

the surgeon. This becomes problematic in the upper cervical spine where working space is generally deep and limited. Another less-cited issue is with respect to intraoperative anatomical shifts. For example, brain shift is a well-described phenomenon in intracranial surgery and various methods have been devised to account for this, though no perfect answer exists. Most regions in the spine have anatomy large enough to accommodate even a couple of millimeters of error. However, a highly mobile, deep space with difficult angles and high risk of neurovascular injury such as that seen at the craniovertebral junction demands high precision with little margin for error.

Newer techniques have been explored to reduce surgical errors by using novel technology like 3D printing and modified drill guides [13]. Although individualized 3D printing navigation templates for cervical pedicle screw fixation is easy, safe, and accurate, some limitations include a steep learning curve for surgeons to be proficient with required computer software and errors in image data reconstruction and navigation template design and printing [14]. In another study, Jiang et al. showed that the use of a modified drill guide template for atlantoaxial pedicle screw placement yielded a higher accuracy in screw insertion [13]. Both studies utilized templates in their surgeries, but making a template for each patient is time-consuming and more importantly, does not account for anatomical changes during the course of an operation.

Robot-assisted spinal surgery has been in use to improve accuracy in screw instrumentation. For example, SpineAssist/Renaissance robot (MAZOR Robotics Inc®, Orlando, Florida and ROSA® robot (Medtech, S.A., Montpellier, France) are two surgical robots to help neurosurgeons navigate and implant screws [9]. However, these robots still carry issues such as reference point translation, additional incisions, and a lack of real-time navigation. Care must be taken to not touch the bulky reference frame at the spinous process or iliac wings. If mobilized, the robot would interpret that as body movement, update itself, and subsequently induce an error in screw placement. Moreover, to accommodate for reference point positioning such as at the iliac wings, additional incisions must be made. Furthermore, the spine is dynamic due to respiration motion and surgical procedures. If the spine moved significantly, then rescanning and reregistration would be necessary because the original anatomic map the robot follows would be outdated. Rescanning increases patient radiation exposure. Robotic-assisted spinal surgery should consider changing its form and location of reference to laminar bone fiducials. The use of laminar bone fiducials would eliminate reference point translation, additional incisions, and non-real-time navigation. Laminar bone fiducials are fixed and immobile and allowed for easy reregistration during the surgery without the need to rescan to acquire the transient real-time anatomical layout. This combo-immobile reference points and high-tech instrumentation would reduce neuromuscular injury, breaching, or other complications.

The use of bone fiducials is not a new concept. From Allen's proposal in 1987 to replace the stereotactic frame with skull-based fiducials to the historic Acustar trial in 1997, fiducials have since gained popularity [15]. Holloway et al. found that the use of bone fiducials in Deep Brain Stimulation (DBS) yielded a comparable level of accuracy in final lead placement when compared to the use of the Leksell frame. In a more recent study, frameless DBS surgery (bone fiducials) was shown to have a comparable patient outcome relative to frame-based surgery. The frameless guidance revolution has evolved to become a standard for neurosurgery [15]. We see the use of bone fiducials in spine surgery to improve the registration process,

the accuracy in surgical guidance, and ultimately pedicle screw placement. We also envision using a deep-release drive system such as PosiSeat™ to eliminate over-and under-insertion while achieving more consistent placement of bone-implanted fiducials than manual insertion.

Here we present, to the best of our knowledge, a novel intraoperative navigation technique that has yet to be reported in the placement of C2 pedicle screws for atlantoaxial instability. The described technique eliminates the limitations discussed previously reference frame translation, surgeon interference, and lengthening the incision-while allowing for highly accurate screw placement in difficult cases with significant anatomical constraints. By utilizing low-profile screws as *in situ* bone fiducials, we were able to minimize surgeon interference by eliminating the need for a large fixed reference frame. The degree of anatomical “shift”, an issue that continues to plague cranial neurosurgery, could be accounted for by means of re-registration throughout the case, thus allowing us to navigate in as close to “real-time” as possible without added scans. Even though postoperative CT scan showed grade I breach of the left transverse foramen, there was no intraoperative or postoperative concern for vascular injury and no clinical sequela. This method allowed for safe cannulation of very small C2 pedicles without incurring neurovascular injury. Furthermore, laminar fiducials which remain fixed in the lamina allow for reregistration without the need for repeating imaging in contrast to utilizing a reference frame which would require repeat imaging.

Conclusion

To the best of our knowledge, we describe the first case report to use *in situ* C2 and C3 laminar bone fiducials for real-time intraoperative navigation that led to subsequent successful cannulation of small C2 pedicles. This novel technique may be applicable to similar high-risk cases.

References

1. Kast E, Mohr K, Richter HP, Borm W (2006) Complications of transpedicular screw fixation in the cervical spine. *Eur Spine J* 15: 327-334.
2. Jacobs C, Roessler PP, Scheidt S, Ploger MM, Jacobs C, et al. (2017) When does intraoperative 3D-imaging play a role in transpedicular C2 screw placement? *Injury* 48: 2522-2528.
3. Gelalis ID, Paschos NK, Pakos EE, Politis AN, Arnaoutoglou CM, et al. (2012) Accuracy of pedicle screw placement: a systematic review of prospective in vivo studies comparing free hand, fluoroscopy guidance and navigation techniques. *Eur Spine J* 21: 247-255.
4. Shimokawa N, Takami T (2017) Surgical safety of cervical pedicle screw placement with computer navigation system. *Neurosurg Rev* 40: 251-258.
5. Costa F, Ortolina A, Attuati L, Cardia A, Tomei M, et al. (2015) Management of C1-2 traumatic fractures using an intraoperative 3D imaging-based navigation system. *J Neurosurg Spine* 22: 128-133.
6. Anaizi A, Kalhorn C, McCullough M, Voyadzis JM, Sandhu F (2015) Thoracic spine localization using preoperative placement of fiducial markers and subsequent CT. A technical report. *J Neurol Surg A Cent Eur Neurosurg* 76: 66-71.
7. Overlay SC, Cho SK, Mehta AI, Arnold PM (2017) Navigation and robotics in spinal surgery: Where are we now? *Neurosurgery* 80: S86-S99.
8. Kaneyama S, Sugawara T, Sumi M (2015) Safe and accurate midcervical pedicle screw insertion procedure with the patient-specific screw guide template system. *Spine* 40: E341-E348.
9. Mueller CA, Roessler L, Podlogar M, Kovacs A, Kristof RA (2010) Accuracy and complications of transpedicular C2 screw placement without the use of spinal navigation. *Eur Spine J* 19: 809-814.

10. Waschke A, Walter J, Duenisch P, Reichart R, Kalff R, et al. (2013) CT-navigation versus fluoroscopy-guided placement of pedicle screws at the thoracolumbar spine: single center experience of 4,500 screws. *Eur Spine J* 22: 654-660.
11. Ling JM, Tiruchelvarayan R, Seow WT, Ng HB (2013) Surgical treatment of adult and pediatric C1/C2 subluxation with intraoperative computed tomography guidance. *Surg Neurol Int* 4: 109-117.
12. Kim SU, Roh BI, Kim SJ, Kim SD (2014) The clinical experience of computed tomographic-guided navigation system in c1-2 spine instrumentation surgery. *J Korean Neurosurg Soc* 56: 330-333.
13. Jiang L, Dong L, Tan M, Qi Y, Yang F, et al. (2017) A Modified personalized image-based drill guide template for atlantoaxial pedicle screw placement: A clinical study. *Med Sci Monit* 23: 1325-1333.
14. Guo F, Dai J, Zhang J, Ma Y, Zhu G, et al. (2017) Individualized 3D printing navigation template for pedicle screw fixation in upper cervical spine. *PLoS One* 12: e0171509.
15. Holloway KL, Gaede SE, Starr PA, Rosenow JM, Ramakrishnan V (2005). Frameless stereotaxy using bone fiducial markers for deep brain stimulation. *J Neurosurg* 103: 404-413.

Author Affiliation

Top

¹Department of Neurological Surgery, University of California, Irvine, USA

²School of Medicine, University of California, Irvine, USA

Submit your next manuscript and get advantages of SciTechnol submissions

- ❖ 80 Journals
- ❖ 21 Day rapid review process
- ❖ 3000 Editorial team
- ❖ 5 Million readers
- ❖ More than 5000 
- ❖ Quality and quick review processing through Editorial Manager System

Submit your next manuscript at • www.scitechnol.com/submission