



Research Article

## Protection of Paravertebral Muscles and Short Segment Stabilization in Surgical Treatment of Thoracic and Lumbar Compression Fractures

Sukru Oral<sup>1\*</sup>, Atilla Yilmaz<sup>1</sup>, Ahmet Kucuk<sup>2</sup>, Halil Ulutabanca<sup>2</sup> and Ahmet Selcuklu<sup>2</sup>

### Abstract

**Objective:** In this study, patients with thoracolumbar and lumbar fracture fractures were treated with preservation of the paravertebral muscles, unfused posterior short-segment pedicle instrumentation technique.

**Methods:** Between the years 2009-2015, 24 patients were applied short-segment posterior instrumentation surgery for thoracolumbar and lumbar compression fractures in our clinic included in the study. On radiological evaluation, loss of height in spinal anterior corpus (LHSAC) and local angle of kyphosis (LAK) were used. In the operation, the thoracolumbar fascia opened linearly, fascia was excised laterally and finger-dislocated between the multifidus and longissimus muscles. The transversal processes of vertebrae and manufactured objects were found. The transpedicular screws were placed with the C-arm.

**Results:** The mean local angle of kyphosis measured preoperatively was 11.03 degrees and this angle 7.24 degrees at the end of the first year. Before the operation, loss of height in the spinal anterior corpus (LHSAC) was determined as 27.21% on average. At the end of the 1st year, the mean LHSAC was measured as 22.83%. Mean duration of the operation was 103.75 min and mean blood loss was 123.12 ml.

**Conclusion:** In this surgical procedure, preservation of the paravertebral muscles contributes to vertebral column stabilization in cases of short segment instrumentation. For this reason, short segment instrumentation in thoracic and lumbar locations provides a significant kyphotic improvement in patients with compression fractures.

### Keywords

Short segment; Paravertebral muscles; Compression fracture

### Introduction

Fractures and injuries in the thoracolumbar (T11-L2) area are the most common pathologies in spinal injuries. They constitute 20% of all spinal traumas, and 4-42% of these cases have neurological damage [1]. Lower lumbar location (L3-L5) fractures are less common, and it's

\*Corresponding author: Sukru Oral, Department of Neurosurgery, Mustafa Kemal University, Tayfur Ata Sökmen Medical Faculty, Serinyol, Antakya, 31040, Hatay, Turkey, Tel: +90 5072335288; E-mail: sukruor@yahoo.com

Received: September 09, 2018 Accepted: September 20, 2018 Published: September 27, 2018

usually shaped a burst fracture [2]. Nowadays, many conservative and surgical methods are applied for thoracolumbar and lumbar location fractures. In the treatment of these fractures, the aim is to provide neurological and mechanical stability [3]. There are many different views and classifications about the selection of surgical methods. For surgical methods, techniques including with fusion and non-fusion posterior, anterior and combined instrumentation are used recently [4]. Posterior short-segment pedicle instrumentation is a widely used method for the treatment of instability, emerging after thoracolumbar and lumbar location fractures [5]. Multifidus muscles in the paravertebral location are responsible for spinal extension, rotation and stabilization. These muscles spread to three joint segments and work to stabilize joints at each segment level. In addition, these muscles reduce degeneration of joints. Unfortunately, these muscles are sometimes damaged during trauma, often during surgical dissection. In this study, patients with thoracolumbar and lumbar fracture fractures were treated with preservation of the paravertebral muscles, unfused posterior short-segment pedicle instrumentation technique, and postoperative clinical and radiological results are stated.

### Material and Methods

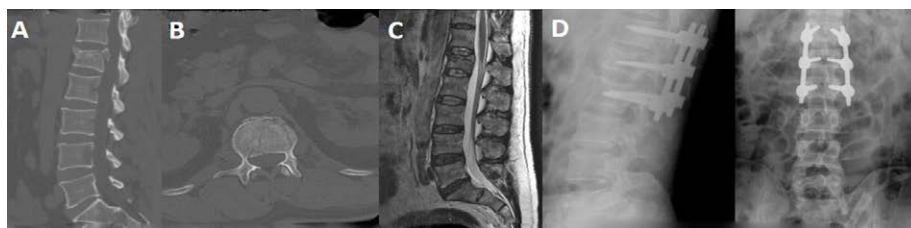
Between the years 2009-2015, 24 patients were applied short-segment posterior instrumentation surgery for thoracolumbar and lumbar compression fractures in our clinic (Erciyes University Medical Faculty, Neurosurgery Department) were evaluated. We collected information of patient demographics (age and sex), operation time and blood loss (Table 1). Their clinical and radiological results were followed at certain time intervals. The neurological status of the cases was evaluated by Frankel Classification. Patients with Frankel E were taken to study. Preoperative evaluation of the patients was done with CT (Computer Tomography) and MRI (Magnetic Resonance Imaging). X-ray and CT were used at the postoperative 6th month and 1st year controls of the patients (Figure 1 and Figure 2). Patients without additional problems were mobilized with a lumbosacral or thoracolumbar corset in the postoperative early period (8-24 hours). And patients were provided to have been using corsets for 8-12 weeks. On radiological evaluation, loss of height in spinal anterior corpus (LHSAC) and local angle of kyphosis (LAK) were used. LHSAC was calculated by Keene method (Figure 3). LAK was measured by calculating the angle between the parallel line drawn on the upper end plate of the stable vertebrae above the broken vertebrae and the parallel lines drawn on the lower vertebrae (Figure 3).

### Surgical technique

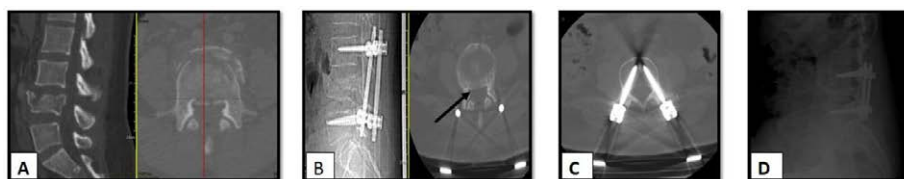
All the patients underwent surgery in prone position under general anesthesia. While the prone position was given, head part was supported with special cushions in the form of bagels as eyes and nose is free and open, thorax and pelvis upper part is supported by rolls and pillows. Elastic bandages were used to prevent venous ponding in the lower extremities. 1 hour before the operation, the patients are routinely treated with 25 mg/kg of prophylactic or max. 2 gr. of intravenously cefazolin was applied. The incision was made of a middle line of the broken vertebra covering a top and a bottom. The thoracolumbar fascia opened bilaterally linearly. Fascia was excised

**Table 1:** Information of patient demographics (age and sex), operation time and blood loss.

Age	Sex	Level of fracture	Frankel Score	LAK Preop.	LAK Postop.	Blood loss (ml)	LHSAC Preop.(%)	LHSAC Postop. (%)	Operation time (Min)
58	K	L2	E	6,92	0,77	110	34	27	105
40	K	L4	E	14,16	6,05	145	25	17	95
63	K	T12	E	22,42	17,85	125	43	34	90
26	E	T12	E	24,71	18,56	105	25	40	110
51	K	L2	E	0,81	2,76	165	18	22	120
34	K	L1	E	14,26	7,24	150	19	20	85
35	E	L2	E	5,64	1,21	120	11	16	90
41	K	T12	E	24,79	19,94	110	35	20	90
44	E	T12	E	21,34	10,47	135	37	35	95
38	E	L2	E	17,25	5,67	130	20	20	105
27	K	T12	E	23,4	16,23	125	45	16	110
36	E	L3	E	7,64	2,52	115	33	24	85
29	E	L1	E	13,8	8,21	110	22	18	90
34	K	L4	E	12,18	6,45	100	33	24	95
56	K	L2	E	5,87	1,76	105	18	17	90
46	E	L2	E	1,77	2,32	120	20	15	90
32	E	T12	E	12,95	7,21	145	34	20	105
16	E	L2	E	6,87	4,55	120	23	19	100
53	K	L2	E	4,57	1,33	125	18	10	130
52	K	L1	E	0,08	9,92	120	10	24	110
34	E	L2	E	10,02	8,92	105	37	30	125
58	E	L2	E	3,84	2,26	160	35	40	150
32	E	L1	E	4,24	3,16	110	28	20	130
50	E	T12	E	5,34	8,48	100	30	20	95



**Figure 1:** 32 Age, Male patient, low back pain after 2.5 m high, neurological deficit A,B,C: L1 Compression burst fracture in preoperative sagittal and axial CT and sagittal MRI section D: Lumbar radiographs taken at 6 months postoperatively



**Figure 2:** 34 Age, Female patient, back pain after car traffic accident, no neurological deficit A: Preoperative BT sagittal and axial section L4 burst fracture B: Indirect reduction which was performed by ligamentotaxis technique has been demonstrated after operation C,D: Postoperative 12th Axial CT section and Lateral Rontgenogram

laterally and finger-dislocated between the multifidus and longissimus muscles. The transversal processes of vertebrates and manufactured objects were found. The transpedicular screws were placed with the C-arm. The rods were fixed, paying attention to lordosis and kyphosis (Figure 4). Ligamentotaxis was performed and the reduction was provided. Since the paravertebral muscles were protected, transverse connection and fusion were not put. Then the fascias, subcutaneous and skin were closed appropriately.

### Statistical method

Whether the distribution of the groups was normal or not was

determined by using the Shapiro-Wilk-W test for parametric tests. In addition to this test, normalization of the distributions was examined by using the SPSS program. Obtained continuous data were given as an average. For intergroup analysis, the Paired-T test was used. The obtained value of “p” < 0.05 was accepted as statistical significance level. SPSS Statistics 22.0 program was used for the statistical calculations.

### Discussion

The mean LAK measured preoperatively was 11.03 degrees and this angle 7.24 degrees at the end of the first year. This improvement in the mean local angle of kyphosis with 3.79 degrees was found to

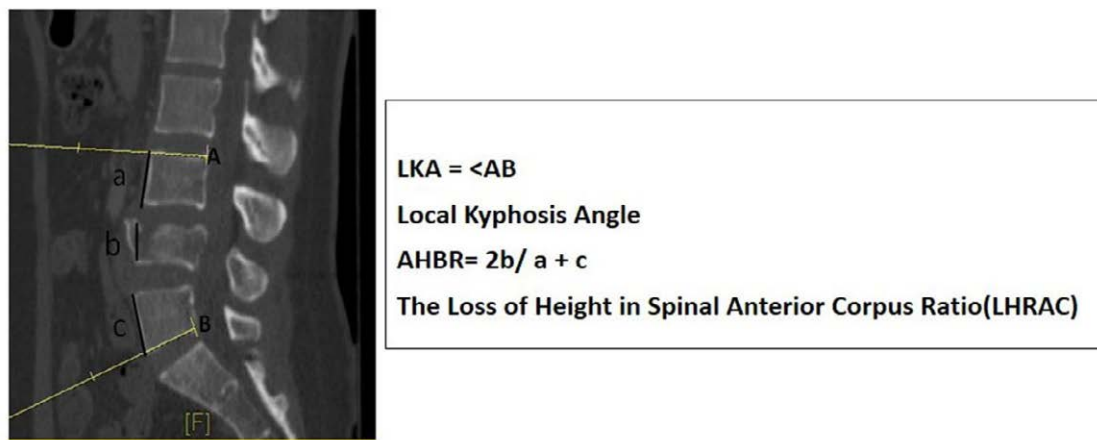

Figure 3: Loss of height in the spinal anterior corpus and local angle of kyphosis measurement

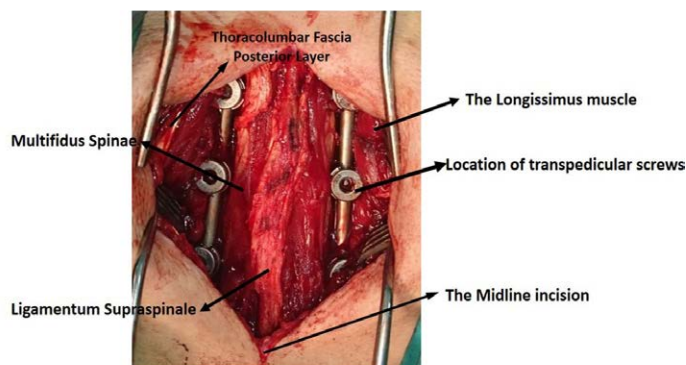


Figure 4: The application of surgical incision and posterior instrumentation has been demonstrated.

Table 2: Changes in LAK and LHSAC before and after surgery

	n	Mean (%)	Standart deviation	Mean of change	P Değeri
Preoperative LKA	24	11,0363	7,86162	3,79	P=0.01
Postoperative LKA	24	7,2433	5,78102		
Preoperative LHSAC	24	27,21	%9,523	%4,38	P=0.03
Postoperatie LHSAC	24	22,83	%7,828		
LKA:	Local Angle of Kyphosis				
LHRAC:	Loss of Height in Spinal Anterior Corpus				

be statistically significant ( $p=0.01$ ). Before the operation, LHSAC was determined as 27.21% on average. At the end of the 1st year, the mean LHSAC was measured as 22.83%. This height loss seen in the Anterior Body Height Ratio (ABHR) was statistically significant ( $p=0.03$ ) (Table 2). Mean duration of the operation was 103.75 min and mean blood loss was 123.12 ml (Table 1).

Thoracolumbar (T10-L2), traumatic fractures of the spine are the most common fractures of the spinal column [6]. The thoracolumbar burst fracture may be caused by a failure of the anterior vertebral body against this force when the vertebral body is subjected to significant axial, and possibly flexural, forces [7]. These injuries can be treated in different ways by evaluating the clinical status and radiographic findings of the cases. Conservative and surgical methods can be used in the treatment. Neurological deficits and spinal instability are the most important factors in determining

the need for surgery. However, in the conservative treatment of thoracolumbar burst fractures, corset use and limited mobilization reduce the need for surgical intervention and the morbidity that the surgical will create. Therefore, the choice of surgical or conservative treatment for the treatment of thoracolumbar burst fractures and the efficiency of these methods are still controversial, especially in non-neurological deficit cases [8]. However, the general opinion is that surgical treatment is necessary for cases without neurological deficit when 50% and above the canal pressure, and 25° and above kyphotic angulation is found [9]. The aim of surgical treatment of thoracolumbar burst fractures is to provide a rigid stabilization of the spinal canal and nerve roots to get decompression, neurological recovery, and restoration, ease of nursing care, early ambulance and rehabilitation. Furthermore, the surgical treatment limits the number of posttraumatic progressive deformities and vertebrae moving segments [10]. Approach to thoracolumbar burst fractures

and their stabilization choice of surgical technique has long been a matter of debate. Among the surgical approaches for thoracolumbar fractures, posterior short segment pedicle instrumentation is one of the most commonly used techniques due to the availability of 3-column stabilization [11]. Markel and colleagues compared short segment fixation with long segment instrumentation and fusion in the treatment of some thoracolumbar burst fractures and showed that short segment fixation gave more successful results [12]. Similarly, Parker and colleagues reported that the most successful way of in thoracolumbar burst fractures is short segment transpedicular stabilization [5]. However, nowadays debate is whether short segment transpedicular stabilization is still an appropriate method. We also performed short segment transpedicular instrumentation to our cases. Advanced surgical techniques and implants with spinal surgery, give satisfactory results. Surgical treatment provides immediate spinal stability and more reliable sagittal alignment, vertebra height is maintained, and canal pressure is removed. Alvine et al. [13] reported that in patients with paraplegic and unstable fractures, indirect decompression is as effective as direct decompression. Similarly, Gertzbein et al. [14] reported that with ligamentotaxis the incidence of canal stenosis was reduced from 54% to 40%, especially in patients who were treated in the first 4 days. In our study, we also performed ligamentotaxis on all of our cases and we achieved the reduction by indirect decompression. In their study comparing short and long segment stabilization in thoracolumbar burst fractures of Tezeren and Kuru, found a 55% ratio 10-degree loss of correction in sagittal alignment in the short-segment instrumentation group, but they reported that there was no such loss of correction in long segment stabilization structures [15]. In our study, there was no loss of local kyphosis at the end of the first year in our patients, and an average improvement of 3.79 degrees was observed. And our results supported the knowledge of the literature. Spinal fusion has always been a part of the stabilization procedure. Theoretically, unless spinal fusion was used, the stabilization surgeon might be less successful. However, Sanderson and colleagues achieved satisfactory results in the short-segment fusion-free stabilization of thoracolumbar burst fractures and they noted that posterior or posterolateral fusion in short segment stabilization is unnecessary [16]. Wang and colleagues compared two groups having thoracolumbar burst fractures by using fusion and non-fusion in their study. They reported that there was no significant difference in loss of kyphotic angle between the two groups. In addition, in the same study, the anterior vertebral body height loss was measured between 3.6% and 8.3% [17]. In our study, the loss of height anterior vertebrae was measured as 4.38% at the end of the first year. In addition, our patients had not been given any fusion since the paravertebral muscles were protected. In our sagittal series, no loss of cornea was observed. Our findings were consistent with the literature. This idea is supported in recent years [9,18,19]. Therefore, we think that fusions made with various grafts are not needed in cases of thoracolumbar burst fractures. In addition, costs and infections caused by graft use can be reduced. In the traditional treatment of thoracolumbar burst fractures, muscle dissection and retraction are performed. Multifidus muscles are separated from the laminae, longissimus and iliolumbar muscles by adhesions to the facet joints, either by cutting with surgical scissors or by coagulating with electrocautery. Patients with this type of surgery have waist and back pain complaints postoperatively. Unlike other paraspinal muscles, the multifidus muscles can be easily injured during surgery because they are only underwired by the medial branches of the dorsal ramus [10]. In many studies, minimally invasive techniques have been shown to have less paraspinal muscle atrophy. Therefore, in minimally

invasive approaches, atrophy of paravertebral muscles are prevented, intraoperative bleeding is decreased, the drainage system is not needed and pain is less in the postoperative period [20]. Multifidus muscles provide lateral flexion, extension and rotation movements of the vertebral column. They are also responsible for the stabilization of the vertebral column. In our study, the multifidus muscles were preserved during the surgical procedure and intraoperative bleeding was minimal and no drainage system was needed. So, we didn't use monoaxial pedicle screw. Because, you will appreciate that It is very difficult to place the rod system in this technique. But, we know that monoaxial pedicle screw exhibited more stability in flexion and extension than the polyaxial pedicle screw in in short-segment fixation.

In our method, transpedicular instruments were placed between the paravertebral muscles by making a single linear incision in the middle hump in the thoracic or lumbar location. In other minimally invasive methods mentioned in the literature, two paramedian skin incisions or in the percutaneous method, a separate incision was made for each instrument [9,21,22]. Therefore, our technique can be implemented more easily and quickly than other minimally invasive techniques.

## Conclusion

In this study, for the first time, we demonstrated the technique of short segment transpedicular instrument placement in compression fractures with a single surgical incision made in the dorsal midline. This technique may be preferred in terms of reduced intraoperative bleeding in surgery, short operative time, postoperative hospital stay, and not using fusion, in appropriate cases. In addition, in this surgical procedure, preservation of the paravertebral muscles contributes to vertebral column stabilization in cases of short segment instrumentation. For this reason, short segment instrumentation in thoracic and lumbar locations provides a significant kyphotic improvement in patients with compression fractures.

## References

1. Esses SI, Botsford DJ, Kostuik JP (1990) Evaluation of surgical treatment for burst fractures. *Spine* 15: 667-673.
2. Sansur CA, Shaffrey CI (2010) Diagnosis and Management of Low Lumbar Burst Fractures. *Seminars in Spine Surgery* 22: 33-37.
3. Benson DR, Burkus JK, Montesano PX, Sutherland TB, McLain RF (1992) Unstable thoracolumbar and lumbar burst fractures treated with the AO fixateur interne. *J Spinal Disord* 5: 335-343.
4. Dai LY, Jiang SD, Wang XY, Jiang LS (2007) A review of the management of thoracolumbar burst fractures. *Surg Neurol* 67: 221-231.
5. Parker JW, Lane JR, Karaikovic EE, Gaines RW (2000) Successful short-segment instrumentation and fusion for thoracolumbar spine fractures: A consecutive 41/2-year series. *Spine* 25: 1157-1170.
6. Wood KB, Li W, Lebl DR, Ploumis A (2014) Management of thoracolumbar spine fractures. *Spine J* 14: 145-164.
7. Briem D, Lehmann W, Ruecker AH, Windolf J, Rueger JM, et al. (2004) Factors influencing the quality of life after burst fractures of the thoracolumbar transition. *Arch Orthop Trauma Surg* 124: 461-468.
8. Rajasekaran S (2010) Thoracolumbar burst fractures without neurological deficit: The role for conservative treatment. *Eur Spine J* 1: S40-7.
9. Lee JK, Jang JW, Kim TW, Kim TS, Kim SH, et al. (2013) Percutaneous short-segment pedicle screw placement without fusion in the treatment of thoracolumbar burst fractures: Is it effective? Comparative study with open short-segment pedicle screw fixation with posterolateral fusion. *Acta Neurochir (Wien)* 155: 2305-2312.
10. Hu ZJ, Fang XQ, Fan SW (2014) Iatrogenic injury to the erector spinae during

- posterior lumbar spine surgery: Underlying an anatomical considerations, preventable root causes, and surgical tips and tricks. *Eur J Orthop Surg Traumatol* 24: 127-135.
11. Siebenga J, Leferink VJ, Segers MJ, Elzinga MJ, Bakker FC, et al. Treatment of traumatic thoracolumbar spine fractures: A multicenter prospective randomized study of operative versus nonsurgical treatment. *Spine* 31: 2881-2890.
  12. Markel DC, Graziano GP (1995) A comparison study of treatment of thoracolumbar fractures using the ACE Posterior Segmental Fixator and Cotrel-Dubousset instrumentation. *Orthopedics* 18: 679-686.
  13. Alvine GF, Swain JM, Asher MA, Burton DC (2004) Treatment of thoracolumbar burst fractures with variable screw placement or Isola instrumentation and arthrodesis: Case series and literature review. *J Spinal Disord Tech* 17: 251-264.
  14. Gertzbein SD, Crowe PJ, Fazl M, Schwartz M, Rowed D (1992) Canal clearance in burst fractures using the AO internal fixator. *Spine* 17: 558-560.
  15. Tezeren G, Kuru I (2005) Posterior fixation of thoracolumbar burst fracture: Short-segment pedicle fixation versus long-segment instrumentation. *J Spinal Disord Tech* 18: 485-488.
  16. Sanderson PL, Fraser RD, Hall DJ, Cain CM, Osti OL, et al. (1999) Short segment fixation of thoracolumbar burst fractures without fusion. *Eur Spine J* 8: 495-500.
  17. Wang ST, Ma HL, Liu CL, Yu WK, Chang MC, et al. (2006) Is fusion necessary for surgically treated burst fractures of the thoracolumbar and lumbar spine?: a prospective, randomized study. *Spine* 31: 2646-2652.
  18. Jindal N, Sankhala SS, Bachhal V (2012) The role of fusion in the management of burst fractures of the thoracolumbar spine treated by short segment pedicle screw fixation: A prospective randomised trial. *J Bone Joint Surg Br* 94: 1101-1106.
  19. Hwang JU, Hur JW, Lee JW, Kwon KY, Lee HK (2012) Comparison of posterior fixation alone and supplementation with posterolateral fusion in thoracolumbar burst fractures. *J Korean Neurosurg Soc* 52: 346-352.
  20. Kim CW (2010) Scientific basis of minimally invasive spine surgery: Prevention of multifidus muscle injury during posterior lumbar surgery. *Spine* 35: S281-286.
  21. Hoh DJ, Wang MY, Ritland SL (2010) Anatomic features of the paramedian muscle-splitting approaches to the lumbar spine. *Neurosurgery* 66: 13-24.
  22. Wiltse LL, Spencer CW (1988) New uses and refinements of the paraspinous approach to the lumbar spine. *Spine* 13: 696-706.


### Author Affiliation

Top

<sup>1</sup>Department of Neurosurgery, Mustafa Kemal University, Turkey

<sup>2</sup>Department of Neurosurgery, Erciyes University Medical Faculty, Turkey

### Submit your next manuscript and get advantages of SciTechnol submissions

- ❖ 80 Journals
- ❖ 21 Day rapid review process
- ❖ 3000 Editorial team
- ❖ 5 Million readers
- ❖ More than 5000  Facebook fans
- ❖ Quality and quick review processing through Editorial Manager System

Submit your next manuscript at • [www.scitechnol.com/submission](http://www.scitechnol.com/submission)