



Acute Scrotum during the First Year of Life

Mäkelä E^{1*} and Lahdes-Vasama T²

Abstract

Objective

The aims were to characterize spermatic cord torsion (SCT), to compare it with other causes of acute scrotum during the first year of life and to describe the distinctive features of each causative group.

Material and Methods

Ninety-one consecutive neonates (44) and infants (47) were operated on for acute scrotum and the definitive diagnoses for the testicles thus confirmed. The duration of the symptoms and the physical findings were recorded. The histopathology of the removed testicles was studied and bacterial cultures were obtained from patients with epididymitis (ED).

Results

Thirty-five boys (39%) had SCT, and incarcerated inguinal hernia (IH) and epididymitis were found in 22 (24%) and 21 (23%) cases, respectively. Torsion of the testicular appendage (TAT) was only seen once. A dark, hard testicle was observed in 91% of the SCT patients, but erythema and tenderness were infrequent. 30 out of 39 (77%) patients had SCT during the neonatal period, including 15 cases in which torsion had occurred prenatally. Only four testicles (11.4%) with SCT were salvaged.

Conclusions

The cause of acute scrotum during the first month of life was mostly SCT, while ED was seen more frequently between the ages of 3 and 6 months. A dark, hard testicle was a common finding in the SCT patients, while swelling and erythema were typical of ED. Neonatal SCT has a poor prognosis.

Keywords

Acute scrotum; Spermatic cord torsion; Infant

Introduction

“Acute scrotum” is a rather common problem needing urgent action in a paediatric surgery emergency department. The most common causes in children less than 18 years of age are torsion of a testicular appendage (TAT) in 10 to 46% of emergency department patients, spermatic cord torsion (SCT) in 11 to 31% and epididymitis (ED) in 10 to 71% [1-3]. Inguinal hernia (IH), acute hydrocele, orchitis, Henoch-Schönlein purpura, idiopathic scrotal oedema, varicocele, tumour, abscess and leukaemic infiltration into the

scrotum occasionally mimic the symptoms of SCT.

In the rare instances in which acute scrotum has been studied during the first year of life the spectrum of diagnoses in this age group has been somewhat different: SCT is the most common (39–59%), followed by ED (23–31%) and TAT (1–9%) [4-7].

The incidence of causative factors in acute scrotum is often based on imaging of the scrotum with ultrasonography. In the present retrospective study consecutive patients with acute scrotum were operated on and the diagnoses thus confirmed. Our main interest was to compare the frequency of SCT with that of other causes of acute scrotum in boys less than one year of age treated in a university hospital serving a population of one million people.

By definition acute scrotum entails sudden pain and swelling in the hemiscrotum, indicating possible inflammation or ischaemia. The historical features and findings on physical examination nevertheless differ between babies and older patients, who are more able to express their symptoms [7]. A second aim of this work was to explore possible differences in physical findings between the various diagnoses that could perhaps help the clinician to decide whether or not to operate on acute scrotum in an infant or neonate male [8-13].

Material and Methods

The medical records of all males under one year of age who entered the Hospital for Children and Adolescents (part of Helsinki University Hospital) between 1977 and 1995 because of acute scrotum were reviewed. All the patients had been operated on. Clinical findings such as temperature, tenderness, oedema, redness or erythema, darkness and hardness of the scrotum, duration of the symptoms and the eventual cause of the acute scrotum decided upon after exploration were recorded. The scrotum was considered acute if there had been clinical presentation characterized by a change in colour and rapid oedema and possibly pain or tenderness of the scrotum or there had been a suspicion of SCT or incarcerated inguinal hernia. Large hydroceles with a clear transillumination sign had not been classified as “acute scrotum” and were not operated on or included in the present series. Patients with obvious urinary tract infections and acute scrotum were included.

The durations of symptoms before the surgical approach were obtained from the charts. In cases of SCT the testicle was first de-rotated and if the colour and blood circulation recovered it was fixed in place with non-absorbable sutures. The contralateral testicle was also observed and fixed to the scrotal septum with non-absorbable sutures simultaneously. If the de-rotated testis did not recover within 5 minutes when wrapped in warm saline-soaked towels, it was removed and the contralateral testicle was fixed. All removed testicles were sent for microscopic examination.

The diagnostic criteria for acute epididymitis were three or more of the following clinical findings: gradual onset of pain, fever, abnormal urine sediment, tenderness and induration of the epididymis, recent catheterization or a history of genitourinary abnormality [1]. Radiological imaging was arranged for patients with epididymitis to determine the underlying anatomical anomalies, and sonography of the urinary tract, a voiding cystourethrogram

*Corresponding author: Eija Mäkelä, Ph.d, Consultant in Pediatric Urology, Paediatric Surgery, Harri Rajakorpi, Vaasa Central Hospital, P.O. Box 2000, FIN-33521 Tampere, Finland, Phone: +358 505366385, Fax: +358 331166098+358 331166098; E-mail: eija.makela@pshp.fi

Received: December 14, 2015 Accepted: March 09, 2016 Published: March 16, 2016

(VCUG) and occasionally urography were carried out after the acute inflammatory period. Bacterial cultures were obtained either from urinalysis or biopsies of the necrotic epididymis or samples of tissue fluid taken preoperatively. The urinalysis was obtained from double urine samples or from a bladder puncture.

Results

Thirty-five (39%) of the 91 boys aged less than one year who had been operated on for acute scrotum actually had SCT. Thirty of these were neonatal cases, of which 15 were perinatal or prenatal. Twenty-one were on the right side and 14 on the left. There were no bilateral cases. Incarcerated inguinal hernia was found in 22 (24%) patients, epididymitis in 21 (23%) and sudden hydrocele in 9 (10%). Other findings (4%) were one TAT, two scrotal haematomas and one orchitis due to mumps. The incidences of SCT, IH and ED by age in months are indicated in Figure 1.

The durations of the symptoms of SCT, IH and ED are presented in hours and days in Figure 2. The median duration of SCT symptoms preoperatively was 12 hours (range 0–24) in 29 out of 35 boys. The median preoperative duration of symptoms in the patients who suffered from epididymitis was 12 to 24 hours, while the duration of symptoms of inguinal hernia was more diverse, but the median was one day.

Only nine out of 35 (26%) testicular torsion patients were operated on within 6 hours of the first symptoms. A dark, bluish, hard testis seemed to be specific for SCT (32/35, 91%), but this finding was also positive in patients with strangulated hernias and necrosis of the testicle (7/22, 32%). Four testicles (11.4 %) were salvaged, two of which were considered prenatal or perinatal with an abnormal scrotal finding detected at birth. The salvage was ensured clinically after 6-12 months of follow-up. Thirty-one testicles were found to be clinically necrotic and were removed. Histopathological examination revealed that these testicles had haemorrhagic infarction or necrosis.

The physical findings in the SCT, IH and ED patients are presented in Figure 3.

Incarcerated inguinal hernia

It was found in 24% of the infant boys with acute scrotum, 73% of whom (16/22) were less than 3 months of age and 48% (10/22) aged from 1 to 3 months. The typical sign was oedema of the scrotum extending to the inguinal area. Six testicles were found to be necrotic and were removed during the operation. The histopathological finding was necrosis haemorrhagica of the testis. One dark testicle was left behind and had recovered after a 5-month follow-up.

Epididymitis

It was found in 23% of the patients operated on and was the most common diagnosis among boys aged from 3 to 6 months (13/17, 76%). The typical symptom was erythema of the scrotum, which was rare among the other boys. The epididymis or the whole scrotum was swollen in 19/21 patients and painful in 9/21. Body temperature exceeded 37.5 degrees Celsius in 4/21 patients. ED was diagnosed at operation if the epididymis was inflamed and the testicular appendages were normal. Nine patients had a positive bacterial culture in either urine or a tissue fluid sample. The bacteria found in the infant patients with epididymitis are listed in Table 1.

Deferred investigations in the boys with epididymitis consisted of a voiding cystourethrogram, sonography and cystoscopy. These

investigations yielded no physical abnormalities other than the fact that in two cases the condition was associated with grade two vesicoureteral reflux and in one case with a recto urethral fistula and VACTERL association.

Hydrocele

It was found in nine of the patients (10%), eight of whom were younger than 6 months. Seven patients had had an acutely enlarged scrotum for less than 24 hours. Oedema of the scrotum, tenderness and positive Transillumination were detected in eight, five and one of the cases, respectively.

Torsion of the testicular appendage

It was found in only one patient, aged 2 months. The hemiscrotum was red, swollen, dark and tender.

Discussion

This investigation was focused on the first year of life. The data are very reliable, because all the acute scrotum cases reviewed were operated on. There are often diagnostic difficulties when examining babies with acute scrotum, as they are unable to express pain, which may delay treatment. Also, ultrasound has its limitations when used on small testicles, and although MRI would be more accurate, its availability is limited in emergency situations by the fact that the patient needs to be anaesthetized [5]. Since the duration of the symptoms during the first year of life is difficult to estimate, the question of whether or not to operate immediately on a case of acute scrotum remains under debate.

SCT is the most common cause of acute scrotum during the first year of life [3,4,6] and especially during the neonatal period. In our

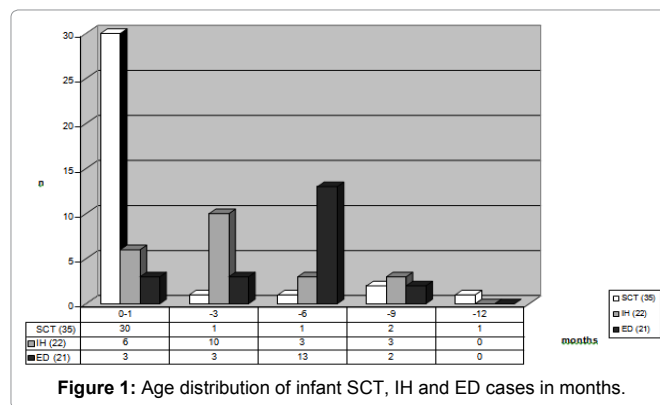


Figure 1: Age distribution of infant SCT, IH and ED cases in months.

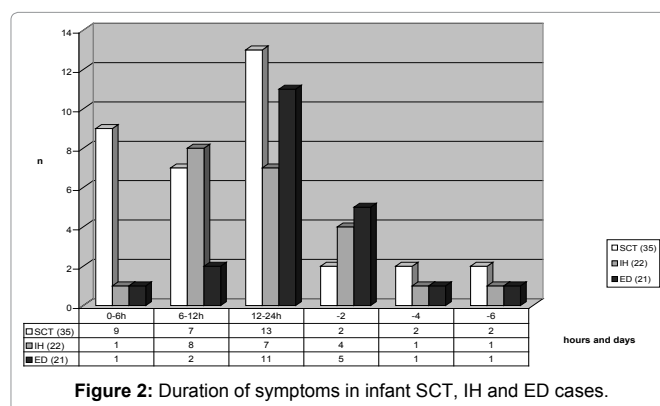


Figure 2: Duration of symptoms in infant SCT, IH and ED cases.

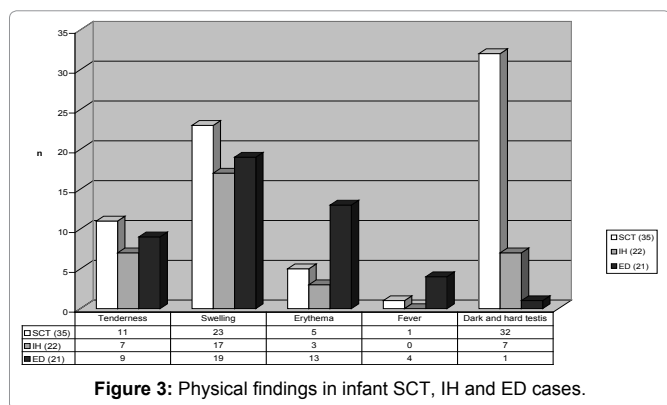


Figure 3: Physical findings in infant SCT, IH and ED cases.

Table 1: Bacteria cultured from infant patients with ED.

Bacteria	Number
E.coli	10
Enterococcus	4
Streptococcus faecalis	1
Klebsiella oxytoca	1

series 77% of all the neonatal patients with acute scrotum suffered from SCT. The incidence of strangulated inguinal hernia was highest from 1 to 3 months of age and epididymitis was most frequent from 3 to 6 months. Chiang et al. (2007), studying 16 infant patients, reported the incidences of SCT and ED to be 8 and 2, respectively, during the first month of life and 1 and 5 in infants less than 3 months of age [7]. We found a decrease in the incidence of acute scrotum between 6 months and 1 year of age, since only 10% of the patients belonged to this age group. This has not been reported previously.

In our series of ED patients (n=21) the diagnostic criteria were met and verified by reference to operative findings. Abnormalities were found upon further examination in three patients (14%), which is less than in other reports, where this route accounts for up to 26% of all anomalies [14]. No urodynamic examinations were performed in our series, however. Nine of the 21 patients with ED (43%) had a positive bacterial culture when the sample was taken preoperatively, two of them having sepsis. Santillanes et al. (2011) reported finds of bacteria in only 4% of their ED patients aged from two months to 17 years [15,16].

ED in infancy can be caused by an ascending urinary infection with a retrograde flow of urine into the seminal vesicles and vas, or by a bloodstream infection [7]. We agree that all infant patients with ED should have renal ultrasound and VCUg examinations because of the possibility of underlying anomalies [17].

Only one TAT (1%) was detected in our relatively large series, whereas TAT has been reported in 26–74% of cases in earlier studies of paediatric patients with acute scrotum [6,14,17]. It must be remembered, however, that we were concentrating on the first year of life whereas previous reports covered the whole childhood period.

The high rate of strangulated hernias in our patients (24%) is explained by the fact that most other authors simply excluded hernias [4,17]. The standard use of ultrasound nowadays means that more information is available preoperatively. A strangulated inguinal hernia may cause considerable morbidity, however, not only for the bowel, but also in the ipsilateral testicle. In 6 of our 22 cases the violated testicle had to be removed because of necrosis, which was later confirmed histologically.

The possibility of SCT as a cause of acute scrotum among neonates is considerable. An acute scrotum during the first year of life may be caused by SCT, ED, strangulated hernia, hydrocele, haematoma, TAT or orchitis, and the physical findings may overlap, but a dark bluish scrotum is mostly found with SCT, whereas a reddish hemiscrotum combined with fever indicates ED. Epididymitis in infants is frequently caused by bacteria.

Although it is clear that not all infants with acute scrotum require urgent exploration, it remains advisable to examine suspected SCTs, especially if the testicle had been normal soon after birth. Surprisingly, two prenatal or perinatal SCT testicles were salvaged in our series. This is known to be possible when the time from the onset of pain to surgery is less than 6 hours [17,18]. Altogether four out of 35 testes were salvaged in our patients, all of which had been explored within 6 hours of receiving notice of the symptoms. Whether the ultimate time limit is 24 or 48 hours remains controversial, as it is bound up with the incidence of testicular torsion and its degree.

Whether a neonatal acute scrotum needs to be surgically explored urgently, semi-urgently or not at all remains controversial [2,9,11,13,17,19]. All four salvaged testicles with SCT had been operated on within 6 hours of the assumed onset of symptoms, whereas all the other affected testicles had to be removed. In a clinical follow-up 6 to 12 months later the salvaged testicles had been found to be normal in size and consistency. In a systematic literature review by Nandi and Murphy published in 2011, covering 284 neonatal torsions, the salvage rate was 8.96%, increasing to 21.7% with prompt exploration [13]. Even three prenatal SCTs were salvaged. They advocated either semi-urgent or urgent exploration. This is consistent with our findings. On the other hand, John et al. [20] and Kaye et al. [21], based on series of 24 and 16 neonates, respectively, postulated that prenatal torsions were never salvageable. In Rhodes' survey of paediatric surgeons and urologists in the UK and Ireland in 2011 only 11 (10%) of the respondents had ever found a viable neonatal testis with SCT [12], whereas Pinto et al. [22], reporting in 1997 on the outcome for testicles one year after neonatal SCT, note that only two out of ten salvaged testicles were normal and both of these had been explored within 6 hours of discovery. They concluded that exploration is safe and should be performed in an emergency in order to increase the rate of testicular salvage.

There are now valuable tools available to the clinician in the imaging field. Colour Doppler ultrasound has greatly facilitated decision-making in cases of young children with acute scrotum [17,19,23,24], but even so, each neonate and infant patient should be investigated thoroughly and the benefit of surgery should be considered individually for each age group and patient on the basis of the clinical findings and an accurate history. Indeed, a patient with symptoms of long duration and fever or urinary infection should not be operated on unless there is evidence of an abscess.

Conclusions

SCT was found in 39% of all the acute scrotum cases occurring during the first year of life that were studied here and in 77% of those observed during the first month of life. ED was the most common diagnosis among baby boys aged from 3 to 6 months (13/17, 76%). A dark, hard testicle was a common finding in SCT patients, while swelling and erythema of the scrotum was the most common sign of ED. In 11.4 % of the testis torsion cases the testis was salvaged thanks to emergency surgery. We recommend exploration of an acute infant scrotum caused by SCT and also fixation of the contralateral

testicle, but in cases with a longer history operative treatment may be regarded as semi-urgent.

Declaration of interest

The authors report no conflicts of interest. The authors alone are responsible for the writing of the paper and for its content.

References

- Burgher SW (1998) Acute scrotal pain. *Emerg Med Clin North Am* 16: 781-809.
- Sidler D, Brown RA, Millar AJ, Rode H, Cywes S (1997) A 25-year review of the acute scrotum in children. *S Afr Med J* 87: 1696-1698.
- Kadish HA, Bolte RG (1998) A retrospective review of pediatric patients with epididymitis, testicular torsion, and torsion of testicular appendages. *Pediatrics* 102: 73-76.
- Clift VL, Hutson JM (1989) The acute scrotum in childhood. *Pediatr Surg Int* 4:185-188.
- Mäkelä E, Lahdes-Vasama T, Rajakorpi H, Wikström S (2007) A 19-year review of paediatric patients with acute scrotum. *Scand J Surg* 96: 62-66.
- Yang C Jr, Song B, Liu X, Wei GH, Lin T, et al. (2011) Acute scrotum in children: an 18-year retrospective study. *Pediatr Emerg Care* 27: 270-274.
- Chiang MC, Chen HW, Fu RH, Lien R, Wang TM, et al. (2007) Clinical features of testicular torsion and epididymo-orchitis in infants younger than 3 months. *J Pediatr Surg* 42: 1574-1577.
- Das S, Singer A (1990) Controversies of perinatal torsion of the spermatic cord: a review, survey and recommendations. *J Urol* 143: 231-233.
- Stone KT, Kass EJ, Cacciarelli AA, Gibson DP (1995) Management of suspected antenatal torsion: what is the best strategy?. *J Urol* 153: 782-784.
- Driver CP, Losty PD (1998) Neonatal testicular torsion. *Br J Urol* 82: 855-858.
- Murphy FL, Fletcher L, Pease P (2006) Early scrotal exploration in all cases is the investigation and intervention of choice in the acute paediatric scrotum. *Pediatr Surg Int* 22: 413-416.
- Rhodes HL, Corbett HJ, Horwood JF, Losty PD (2011) Neonatal testicular torsion. A survey of current practice amongst paediatric surgeons and urologists in the United Kingdom and Ireland. *J Pediatr Surg* 46: 2157-2160.
- Nandi B, Murphy FL (2011) Neonatal testicular torsion: a systematic literature review. *Pediatr Surg Int* 27: 1037-1040.
- Lau P, Anderson PA, Giacomantonio JM, Schwarz RD (1997) Acute epididymitis in boys: are antibiotics indicated?. *Br J Urol* 79: 797-800.
- Santillanes G, Gausche-Hill M, Lewis RJ (2011) Are antibiotics necessary for pediatric epididymitis?. *Pediatr Emerg Care* 27: 174-178.
- Caldamone AA, Valvo JR, Altebarmakian VK, Rabinowitz R (1984) Acute scrotal swelling in children. *J Pediatr Surg* 19: 581-584.
- Lewis AG, Bukowski TP, Jarvis PD, Wacksman J, Sheldon CA (1995) Evaluation of acute scrotum in the emergency department. *J Pediatr Surg* 30: 277-281.
- Tryfonas G, Violaki A, Tsikopoulos G, Avtzoglou P, Zioutis J, et al. (1994) Late postoperative results in males treated for testicular torsion during childhood. *J Pediatr Surg* 29: 553-556.
- Kass EJ, Stone KT, Cacciarelli AA, Mitchell B (1993) Do all children with an acute scrotum require exploration?. *J Urol* 150: 667-669.
- John CM, Kooner G, Mathew DE, Ahmed S, Kenny SE (2008) Neonatal testicular torsion—a lost cause?. *Acta Paediatr* 97: 502-504.
- Kaye JD, Levitt SB, Friedman SC, Franco I, Gitlin J, et al. (2008) Neonatal torsion: a 14-year experience and proposed algorithm for management. *J Urol* 179: 2377-2383.
- Pinto KJ, Noe HN, Jenkins GR (1997) Management of neonatal testicular torsion. *J Urol* 158: 1196-1197.
- Hörmann M, Balassy C, Philipp MO, Pumberger W (2004) Imaging of the scrotum in children. *Eur Radiol* 14: 974-983.
- Günther P, Rübgen I (2012) The acute scrotum in childhood and adolescence. *Dtsch Arztebl Int* 109: 449-457.

Author Affiliation

Top

¹Harri Rajakorpi, Vaasa Central Hospital, Finland

²Paediatric Research Centre, Tampere University Hospital, Finland

Submit your next manuscript and get advantages of SciTechnol submissions

- ❖ 50 Journals
- ❖ 21 Day rapid review process
- ❖ 1000 Editorial team
- ❖ 2 Million readers
- ❖ Publication immediately after acceptance
- ❖ Quality and quick editorial, review processing

Submit your next manuscript at ● www.scitechnol.com/submission