



## Candle-Flame-Like Stenosis Carotid Lesion

Nasser Maher<sup>1\*</sup>, Calderon Evelyn<sup>2</sup> and Kurtca Miray<sup>3</sup>

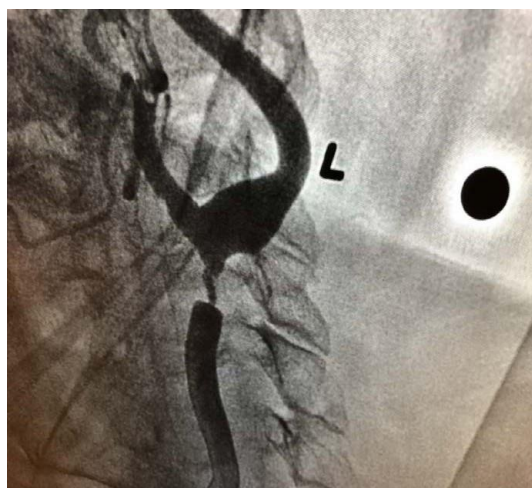


Figure 1: Candle-flame-like stenosis carotid lesion.

### Case Report

An 87-year-old male retired lawyer who came to our outpatient clinic and reported expressive aphasia, weakness in the right upper extremity, and inability to write as normal. Symptoms were highly suggestive of TIAs. On physical examination, he had a loud left carotid bruit. Carotid Doppler suggested a high-grade lesion of left common Carotid Artery. Carotid angiogram showed a severe candle-flame-like narrowing in the left common carotid artery that extended to the bulb area with post stenotic dilatation (Panel A). The patient underwent successful left carotid endarterectomy with no complications and no recurrence of TIAs symptoms on further follow-up.

TIAs are short events of neurologic function alteration caused by a regional reduction in blood flow to the brain without permanent sequelae [1,2]. Strokes can cause long-term disability and death. Death rate increases with subsequent strokes, which often occur within one year of the first attack. TIAs and strokes can be caused by blockages and severe stenosis of carotid arteries. Carotid endarterectomy may reduce the possibility of repeated episodes of TIAs, as well as stroke and its complications, including death in patients with severe carotid occlusion [3].

### References

1. Donald Easton J (2009) Definition and Evaluation of Transient Ischemic Attack. *Stroke* 40: 2276-2293.
2. Coutts SB (2017) Diagnosis and Management of Transient Ischemic Attack. *Continuum* 231: 82-92.
3. Rerkasem K, Rothwell PM (2011) Carotid endarterectomy for symptomatic carotid stenosis. *Cochrane Database Syst Review*.

**Citation:** Maher N, Evelyn C, Miray K (2020) Candle-Flame-Like Stenosis Carotid Lesion. *J Clin Image Case Rep* 4:3.

\*Corresponding author: Nasser Maher, Clinical Professor, Baylor College of Medicine, Consultant Cardiologist, Baylor St. Luke's Medical Center, CHI Health System, Texas Heart Institute, HCA Healthcare, and Houston Methodist Hospital, E-mail: mmnmd.1970@gmail.com

Received: May 20, 2020 Accepted: October 28, 2020 Published: November 04, 2020

### Author Affiliations

Top

<sup>1</sup>Clinical Professor, Baylor College of Medicine, Consultant Cardiologist, Baylor St. Luke's Medical Center, CHI Health System, Texas Heart Institute, HCA Healthcare, and Houston Methodist Hospital, Texas.

<sup>2</sup>Faculty of Medicine, University of Guayaquil, Av. Delta y Av. Kennedy, Guayaquil, Guayas, Ecuador, 090112, EC.

<sup>3</sup>Faculty of Medicine, Dokuz Eylul University, Turkey.