



Research Article

Multislice CT Study of the Craniovertebral Osseous Anomalies

Marinković S^{1*}, Kovačević V², Kapor S³ and Tomić I⁴

Abstract

Modern radiologic technologies, including the multislice CT (MSCT) machines, enable a reliable and precise examination of the patients and volunteers. Our aim was to use the mentioned method in order to reveal the potential craniovertebral malformations in a patient with a duplication of the pituitary gland and in a control group of 11 healthy volunteers. The MSCT examination was performed in all of them, including certain linear measurements and 3D reconstruction. The patient presented with a double hypophyseal fossa, the posterior clinoid process, the odontoid process and the axis body, as well as with a broad clivus, the third occipital condyle, a foramen transversarium defect, a partial agenesis of the anterior and posterior atlas arches, and a fusion of the cervical vertebrae. In one volunteer, an unclosed foramen transversarium was noticed, and in another one an isolated agenesis of the posterior atlantal arch. Whereas some of the obtained anomalies are usually an incidental finding in the general population, some others may produce certain symptoms and signs and therefore require a surgical intervention. Hence the data obtained in our study can have important clinical implications.

Keywords

Skull; Cervical spine; Craniovertebral junction; Congenital anomalies

Introduction

The craniovertebral anomalies occur with a low incidence [1-3], thereby, any new data in this field may have a great clinical significance. Quite incidentally, a patient appeared who was diagnosed as having two pituitary glands. Knowing that a pituitary duplication can be associated with certain rare bony anomalies [1,2,4], we decided to perform a detailed radiologic examination of that patient. In order to check the frequency of some of the observed anomalies, we included into this study almost a dozen healthy volunteers as a control group. A multislice computerized tomography (MSCT) was performed in all the twelve individuals using the latest generation machine. By the way, some of the obtained images reached a high aesthetic value, so it can be said that they approached the level of modern digital artworks.

Nevertheless, the aim of our study was to examine in detail the craniovertebral anomalies, especially in our patient with a pituitary duplication.

*Corresponding author: Slobodan Marinković, MD, PhD, Professor of Neuroanatomy, Institute of Anatomy, Faculty of Medicine, University of Belgrade, Belgrade, Serbia, Tel: 00381-11-2645958; Fax: 00381-11-2645958; E-mail: mocamarinkovic@med.bg.ac.rs

Received: February 23, 2016 Accepted: April 18, 2016 Published: April 25, 2016

Subjects and Methods

The patient was a 20-year-old man presented with hypogonadism and some limitation of the neck movements. The magnetic resonance imaging (MRI) examination showed a double pituitary gland. Expecting some bony anomalies, we performed a MSCT examination in Siemens Somatom Definition AS 128-slice scanner (rotation time 0.5 s, pitch 0.5, slice thickness 0.6 mm, 120-140 kV intervals, manual 260 mA, and noise index 3) with a subsequent 3D images reconstruction. Certain linear measurements were performed in the three planes (axial, coronal and sagittal) using standard software installed in the MSCT equipment which is based on the previous examinations [5].

The control group comprised 11 healthy volunteers, which was the largest number of subjects we could afford. The group consisted of a randomly selected 6 males and 5 females aged 19-42 (mean, 39.6) years. The examination of each subject, including linear measurements, was performed by the same MSCT apparatus in 2D scans. The written consent of each individual was obtained, and the whole procedure was approved by the Ethics Committee of the University Clinical Center.

Results

First of all, the data obtained in our patient will be presented, and then the anomalies found in the volunteers (Table 1).

Case report

We were lucky to find a patient who was diagnosed with hypogonadism and a duplication of the pituitary gland, with some limitation of the neck movements. The MRI showed a double pituitary stalk, enlargement of the hypothalamic wall and its fusion with the mamillary bodies.

The MSCT revealed a double hypophyseal fossa at the base of the skull, a duplication of the right and left posterior clinoid processes, a broad clivus, the expressed relief of the cranial bones, and the third occipital condyle (Figures 1 and 2; Table 1). The latter anomalous bone, which was fused with the anterior rim of the foramen magnum, measured 12.9 mm in the transverse direction, and 10.8 mm in the sagittal diameter.

In addition, a partial agenesis of the anterior and posterior arches of the atlas (C1) was revealed, as well as a bilateral anterior osseous defect of the foramen transversarium. The gap between the right and left remnants of the anterior arch measured 22.7 mm, and the missing middle part of the posterior arch had a transverse diameter of 26.1 mm.

A duplication of the odontoid process and the axis (C2) body (Figures 1 and 3) was noticed as well, and a fusion of the first four cervical vertebrae. The right and left odontoid processes were 7.7 mm and 8.6 mm in height, respectively, and the cleft between their apical parts measured 3.7 mm in the transverse direction. The cleft extended caudally through the body of the axis (Figure 1).

Control group

Among the 11 volunteers, a partial agenesis of the posterior atlas arch was found in one of them. The agenesis affected the middle

Table 1: Congenital anomalies found in 1 patient and 11 volunteers.

Anomalies	Position	No./Frequency (%)
Partial agenesis of the anterior atlas arch	Middle	1/(8.33)
Partial agenesis of the posterior atlas arch	Middle	2/(16.66)
Dehiscence of the foramen transversarium	Unilat, bilat.	2/(16.66)
Double hypophyseal fossa	Middle	1/(8.33)
Third occipital condyle	Middle	1/(8.33)
Double odontoid process & axis body	Middle	1/(8.33)
Fusion of the cervical vertebrae	/	1/(8.33)

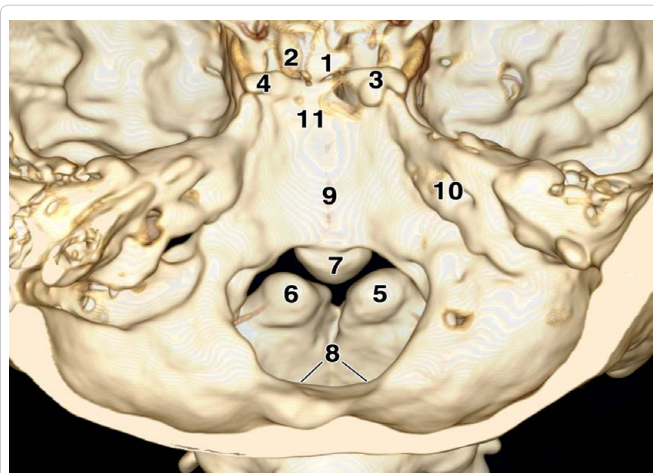


Figure 1: Superior and slightly posterior view of the skull with two pituitary fossae (1 and 2), and a duplication of the posterior clinoid processes (3 and 4), the odontoid process (5 and 6) and the axis body. Note a third occipital condyle (7), the foramen magnum (8), the clivus (9), the right internal acoustic meatus (10) and the dorsum sellae (11).

portion of that arch. The transverse diameter of the gap measured 5.2 mm.

Finally, in another healthy subject a defect of the right foramen transversarium of the atlas was observed (Figure 4). The dehiscence, which occupied the anterior part of the foramen, measured 5.1 mm in the transverse direction.

Discussion

The duplication of the pituitary gland in our patient, with the accompanied craniovertebral anomalies, belongs to the most infrequent congenital malformations. So far, some 40 cases have been reported since the year 1880 [2]. The osteological consequence of this duplication was expressed, as already noticed, by the presence of two hypophyseal fossae within the sella turcica.

The mentioned third occipital condyle, if it is an isolated anomaly, is a very rare event [6,7]. The anomaly represents a hyperplastic median portion of the embryonal hypochordal bow of the proatlas [6-8]. A duplication of the odontoid process also occurs very infrequently. It is most often a part of the midfacial duplication syndrome [1], but it can be an isolated anomaly as well [3]. As already known, the odontoid process has two foetal ossification centers on each side of the midline [6,7]. If they fail to fuse during the development, an odontoid duplication appears. Very rarely, the cleft may extend through the axis body, as was the case in our patient.

The atlas has three primary ossification centers [6,7]. The anterior

of them forms the anterior C1 arch, whereas the remaining two build the lateral masses and the posterior arch of the atlas. In the presented patient, as well as in one of our volunteers, a disorder of the posterior centers resulted in the agenesis of the middle part of the posterior arch. A similar etiology of the anterior arch agenesis was described. The incidence of both anomalies ranges between 0.09% and 0.4% [6,7,9]. A combination of both anomalies in the same patient is known as a bipartite atlas, which can lead to a craniovertebral instability and a consecutive myelopathy [9].

An unclosed foramen transversarium of the atlas was found in another volunteer unilaterally, and in the patient bilaterally. Its incidence was reported in between 2.0% and 10.2% of the general population [10]. In addition to the mentioned three primary ossification centers, there are also two lateral secondary ossification centers of the atlas, which form its right and left transverse processes and foramina [6]. Hence, a disorder of the secondary center(s) resulted in the unclosed foramen transversarium in our subjects.

All in all, in our small control group two of the anomalies were noticed among those found in our patient. One of them, i.e. the agenesis of the atlas arch, is very rare (up to 0.4%), whilst the other one, that is, the unclosed foramen transversarium, occurs more frequently (up to 10.2%). As regards our patient, the observed combination of the osseous anomalies, to our knowledge, has never been reported [1,2]. In general, some malformations are found only incidentally in living subjects, but some others are manifested by certain neurological symptoms and signs which often require surgical treatment [9].

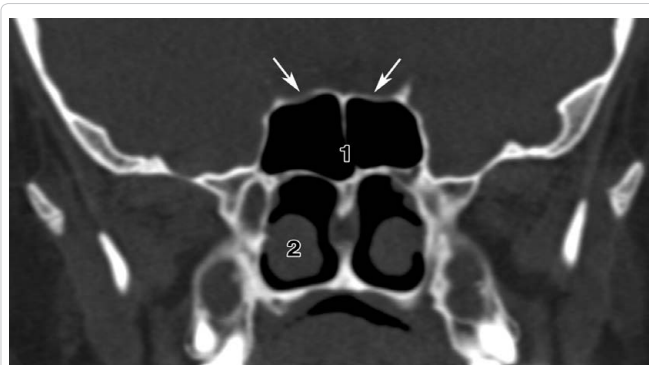


Figure 2: The coronal MSCT scan of the skull base. Note two hypophyseal fossae (arrows), as well as the sphenoid sinus (1) and the nasal concha (2).

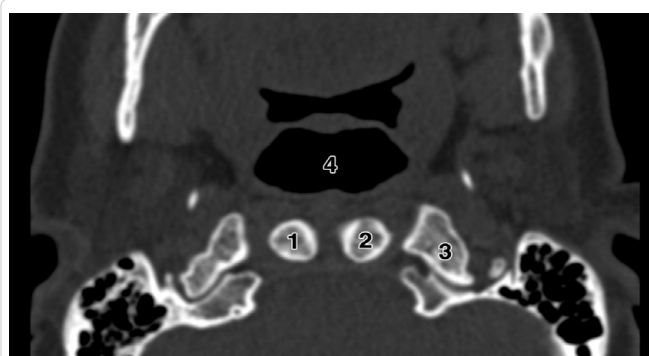


Figure 3: The axial MSCT scan to show a duplication of the odontoid process (1 and 2), as well as the lateral mass of the atlas (3) and the nasopharynx (4).

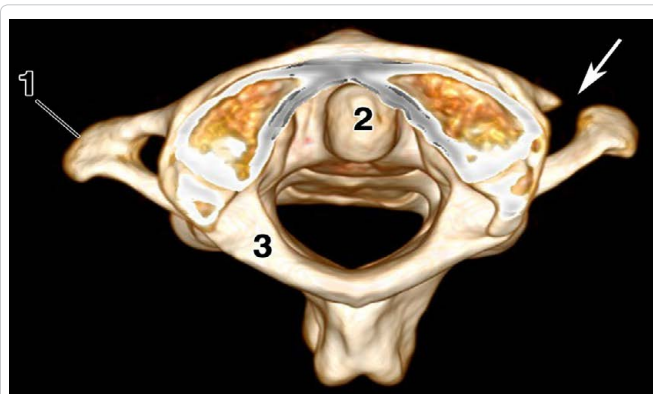


Figure 4: Superior view of the first three cervical vertebrae. Note an anterior defect (arrow) of the right foramen transversarium of the atlas, as well as the left transverse process (1), the odontoid process of the axis (2), and the posterior arch of the atlas (3).

Conclusion

We described a few extremely rare, or relatively infrequent, craniovertebral anomalies presented in the 2D and 3D MSCT images. They comprised a duplication of some osseous structures, and agenesis or defects of some others. Our findings can have certain clinical implications.

References

1. Shen W, Cui J, Chen J, Ji Y, Zou J, et al. (2013) Partial midfacial duplication. J Craniofac Surg 24: 934–936.
2. Manjila S, Miller EA, Vadera S, Goel RK, Khan FR, et al. (2012) Duplication of the pituitary gland associated with multiple blastogenesis defects: Duplication of the pituitary gland (DPG)-plus syndrome. Case report and review of literature. Surg Neurol Int 3: 23-35.
3. Garant M, Oudjihane K, Sinsky A, O’Gorman AM (1997) Duplicated odontoid process: plain radiographic and CT appearance of a rare congenital anomaly of the cervical spine. Am J Neuroradiol 18: 1719-1720.
4. Milić I, Samardžić M, Djorić I, Tasić G, Djulejić V, et al. (2015) Craniovertebral anomalies associated with double pituitary gland. Folia Morphol 74: 524-531.
5. Ullrich CG, Binet, EF, Sanecki MG, Kieffer SA (1980) Quantitative assessment of the lumbar spinal canal by computed tomography. Radiology 134: 137-143.
6. Smoker WR (1994) Craniovertebral junction: normal anatomy, craniometry, and congenital anomalies. RadioGraphics 14: 255-277.
7. Pang D, Thompson DN (2011) Embryology and bony malformations of the craniovertebral junction. Childs Nerv Syst 27: 523-564.
8. O’Rachilly R, Miller F, Meyer DB (1983) The human vertebral column at the end of the embryonic period proper. 3. The occipitocervical region. J Anat 136: 181-195.
9. Klimo P Jr, Blumenthal DT, Couldwell WT (2003) Congenital partial aplasia of the posterior arch of the atlas causing myelopathy: case report and review of the literature. Spine 28: E224-E228.
10. Billmann F, Le Minor JM (2009) Transverse foramen of the atlas (C1) anteriorly unclosed: a minknown human variant and its evolutionary significance. Spine 20: E422-E426.

Author Affiliation

Top

¹Professor of Neuroanatomy, Institute of Anatomy, Faculty of Medicine, University of Belgrade, Belgrade, Serbia

²Clinical Assistant of Cardiology, Clinic of Cardiology, Faculty of Medicine, Clinical Center of Serbia, University of Belgrade, Belgrade, Serbia

³Teaching Assistant, Institute of Anatomy, Faculty of Medicine, University of Belgrade, Belgrade, Serbia

⁴Teaching Assistant, Faculty of Art History, University of Belgrade, Belgrade, Serbia

Submit your next manuscript and get advantages of SciTechnol submissions

- ❖ 50 Journals
- ❖ 21 Day rapid review process
- ❖ 1000 Editorial team
- ❖ 2 Million readers
- ❖ Publication immediately after acceptance
- ❖ Quality and quick editorial, review processing

Submit your next manuscript at • www.scitechnol.com/submission

This article is published in the special issue **Current Trends in Applications for Software/Hardware Integration** and has been edited by Dr. J. Todd McDonald, University of South Alabama, USA